


Corticosteroid Glaucoma



Case Presentation:

- A 43 year-old man initially presented to the retina service for evaluation of extrafoveal choroidal neovascularization (CNV) secondary to ocular histoplasmosis in his left eye.
- The CNV had recurred despite two prior laser treatments by the referring ophthalmologist. In addition, the patient reportedly had extreme discomfort from the laser treatment.

Case Presentation:

Past ocular history:

- Ocular histoplasmosis diagnosed within the past year
- metallic foreign body OD in 1992
- welding flash burn OS 1995

Past medical history:

- s/p appendectomy 1978

Ocular medications:

- none

Medications:

- none

Case Presentation:

Allergies:

- NKDA

Social History:

- married, works as a welder

Family History:

- father diagnosed with glaucoma at age 68
- mother had "very high pressures"

Case Presentation:

- Visual acuity was 20/20 OU with correction.
- Pupils were round and reactive without afferent pupillary defect.
- Intraocular pressures were 20 mm Hg OD, 22 mm Hg OS
- Anterior segment exam was normal.
- Dilated fundus exam revealed peripapillary atrophy with a reported cup/disc ratio of 0.25 OU. There were peripheral punched out lesions OU. A laser scar with mild elevation was seen above the fovea OS.

Case Presentation:

- The patient was initially treated with an intravitreal injection of triamcinolone acetonide (Kenalog) 4mg/1cc OS.
- One week later, when there was no improvement by fluorescein angiography, the CNV was retreated with laser. IOP that day: 15 mm Hg OD, 20 mm Hg OS.
- One week later, (2 weeks s/p intravitreal steroid OS) IOP measured 20 mm Hg OD, 34 mm Hg OS. Alphagan OS BID was started.
- The following week (3 weeks s/p intravitreal steroid), IOP measured 16 mm Hg OD, 25 mm Hg OS.

Case Presentation:

- Three weeks later (6 weeks s/p intravitreal steroid), the patient reported "constant headaches X 4 days." He also admitted quitting his Alphagan drops 4 days ago. IOPs were 20 mm Hg OD, 38 mm Hg OS.
- Alphagan was increased to TID dosing, and Trusopt OD BID was started. Medication compliance was emphasized to the patient.
- Three weeks later (9 weeks s/p intravitreal steroid) IOPs were 20 mm Hg OD, 30 mm Hg OS. Trusopt was changed to Cosopt and Xalatan OS qhs was added. The Glaucoma service was consulted at this time.

Examination:

- He was seen on the glaucoma service 2.5 weeks later (11.5 weeks after intravitreal steroid injection). IOPs that day were 21mm Hg OD, and 31 mm Hg OS.
- 4-mirror gonioscopy showed the angle open to CBB for 360 degrees OU.

Examination:

- Optic discs appeared healthy as did the nerve fiber layer.
- SWAP-VF were full except for the central scotoma from the CNV OS
- Prototype OCT was normal, showing mean nerve fiber layer thicknesses of 118 microns OD, 107 microns OS.
- HRT classification numbers were +1.34 OD, -0.03 OS.

Case Presentation

- It was postulated that his prolonged response to the intravitreal steroids was due to an inadvertent depot in the sclera or subtenons space, although no depot was noted on exam. It was also thought that he might be more susceptible to IOP elevation after steroid treatment given his positive family history.
- The patient was continued on Alphagan OS BID, Cosopt OS BID, and Xalatan OS qhs.

Case Presentation

- One month later (4 months after intravitreal steroid injection) IOP was 21 mm Hg OS, 34 mm Hg OD. Exam was unchanged. OCT showed symmetric NFL of 111 microns OU. He was continued on the same medications
- 5 weeks later (5 months + 1 week after intravitreal steroid injection) IOP had finally decreased to 18 mm Hg OD and 18 mm Hg OS on maximal medical treatment. Exam and OCT was stable. Alphagan was stopped.
- 1 month later (6 months + 1 week after steroid) IOP was 20 mm Hg OD, 16 mm Hg OS. Xalatan was stopped, Cosopt continued.

Case Presentation

- Five weeks later, (7 months + 2 weeks after intravitreal steroid) IOPs were 14 mm Hg OD and 18 mm Hg OS. Cosopt was stopped.

Corticosteroid Glaucoma

Historical Perspective

- Cortisol first used clinically in 1949 by Kendall and Hench for treatment of Rheumatoid Arthritis, launching a tremendous amount of investigation into possible clinical applications for steroids.
- By 1950, Woods reported successful use of corticosteroids in ocular inflammatory diseases such as tuberculous uveitis, sympathetic ophthalmia, nongranulomatous uveitis, corneal burns and vernal conjunctivitis. (8)
- Elevated IOP with corticosteroid use was reported as early as 1950 but was not widely appreciated until approximately 1963 with the publications of Armaly and Becker.

Corticosteroid Glaucoma

Historical Perspective

- November 1962, Hans Goldmann: "there exists a form of secondary glaucoma, which there is much too little known and yet it seems to be of great importance."
- Working separately, Mansour F. Armaly in Iowa City, and Bernard Becker in St. Louis published benchmark studies on corticosteroid glaucoma, which documented the rise of intraocular pressure in formal studies.
- At the same time, other investigators were noting that not only were some long-term topical steroid users developing increased intraocular pressure, some were developing other findings resembling open angle glaucoma with optic nerve head cupping and visual field loss. (9)

Steroid Response

	Becker ¹⁵	Armaly ⁴
Frequency of administration	4 times daily	3 times daily
Duration of administration	6 weeks	4 weeks
Parameter for classification	Final intraocular pressure	Change in intraocular pressure
Classification system		
Low responder	IOP* < 20 mm Hg	IOP† Δ < 6 mm Hg
Intermediate responder	IOP 20 to 31 mm Hg	IOP Δ 6 to 15 mm Hg
High responder	IOP > 31 mm Hg	IOP Δ > 15 mm Hg

Steroid Response

	Low responders (%)	Intermediate responders (%)	High responders (%)
Normal volunteers			
Armaly ²	66	29	5
Becker ¹⁵	58	36	6
Patients with primary open-angle glaucoma			
Armaly ^{4,7,8}	6	48	46
Becker ^{15,19,20}	0	8	92

Corticosteroid Glaucoma

Historical Perspective

- Armaly and Becker developed a classification of "low, intermediate, and high" steroid responders.
- Their studies showed that patients with POAG and their first degree relatives were more likely to be steroid responders than normal individuals.

Corticosteroid Glaucoma

Historical Perspective

- The responses of the patients resembled the distribution of a single Gaussian population.
- Becker and Armaly both postulated that there was a genetic basis for the responsiveness to steroid instillation that could related to the inheritance of POAG.
- The following phenotypes were suggested by Becker, with the responsive trait (g) as recessive and the normal trait (n) as dominant.
 - High responders: homozygous for the responsive trait (gg)
 - Intermediate responders: heterozygous for the responsive trait (ng)
 - Low responders: homozygous for normal trait (nn)

Corticosteroid Glaucoma

Historical Perspective

- "It is tempting to conclude that the homozygous responders (gg) represent the POAG population and the heterozygous steroid responders (ng) represent the carriers of the glaucoma gene" (13)
- Theories relating steroid-responsiveness to POAG have fallen out of favor.
 - Twin studies did not show expected concordance (14,15)
 - Steroid testing was shown not to be an accurate predictor of visual field loss in glaucoma suspects.(16)

Corticosteroid Glaucoma

Those at greater risk for developing increased IOP when treated with corticosteroids:

- primary open angle glaucoma
- first degree relatives of POAG patients
- high myopia (27)
- diabetes (28)

Corticosteroid Glaucoma

Clinical presentation:

- Young children may present like primary infantile glaucoma (tearing, photophobia, blepharospasm)
- Older children and adults may resemble POAG.(asymptomatic)
- Careful history-taking of current and past medications is crucial for diagnosis.
- Rise in IOP can occur as early as one day after initiating treatment
- IOP rise may not occur for months to years.

Corticosteroid Glaucoma

Clinical presentation

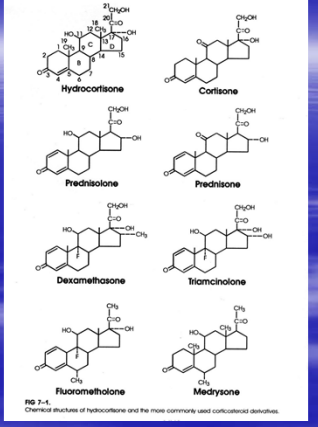
- Latent period depends on many factors:(17)
 - potency of drug
 - dose and frequency of drug
 - route of administration
 - presence of other ocular diseases
 - responsiveness of the patient

Corticosteroid Glaucoma

Pharmacology-

- Family of compounds derived from cholesterol molecule
- Addition of double bonds, side group modification, and creation of derivative compounds can change effect and potency of the drug.
- For example, prednisolone has a second double bond in the A ring, has greater antiinflammatory activity and less fluid retaining effects than cortisol.

Corticosteroid Glaucoma



Corticosteroid Glaucoma

Table 44.2
Relative Potency of Corticosteroids

Steroid Base	Relative Anti-inflammatory Activity
Short acting (8–12 hr)	
Cortisone	0.8
Cortisol	1.0
Intermediate acting (12–36 hr)	
Prednisone	4.0
Prednisolone	4.0
Triamcinolone	5.0
Long acting (36–72 hr)	
Dexamethasone	25
Betamethasone	25

Modified from Haynes and Murad (34).

Corticosteroid Glaucoma

Pharmacology-

- Derivative compounds can also change the effect of the base molecule by affecting penetration into eye, release and degradation rate. (25)
- Lebowitz rated effectiveness of various steroid derivative compounds in inflammatory keratitis and found that acetate derivative > alcohol derivative > phosphate derivative. (21)
- Rimexolone (Vexol), flunometholone (FML) and medrysone (HMS) are less likely to cause IOP elevation but also appear to be less effective in controlling inflammation. (22-24)

Corticosteroid Glaucoma

Table 44.3
Anti-inflammatory Activity of Topical Corticosteroids
in Experimental Keratitis

Steroid compound	Anti-inflammatory Activity (%)
Dexamethasone acetate 0.1%	55
Prednisolone acetate 1% (Pred Forte; Enconopred Plus)	51
Dexamethasone alcohol 0.1% (Maxidex)	40
Fluorometholone alcohol 0.25% (FML Forte)	35
0.1% (FML)	31
Prednisolone phosphate 1% (Inflamase Forte)	28
Dexamethasone phosphate 0.1% (Decadron Phosphate)	19
Medrysone (HMS)	not tested

Modified from Leibowitz (34).

Corticosteroid Glaucoma

CORTICOSTEROID-INDUCED GLAUCOMA

- A. Exogenous corticosteroids
 1. Ocular
 - a. Eyedrops
 - b. Ocular ointments
 - c. Inadvertent administration to the eye from the lids or face
 2. Periocular injection
 3. Systemic
 - a. Oral
 - b. Topical (to the skin)
 - c. Injection
- B. Endogenous corticosteroids
 1. Adrenal hyperplasia
 2. Adrenal adenoma or carcinoma
 3. Ectopic ACTH syndrome

Corticosteroid Glaucoma

- Inhaled corticosteroids have also been shown to increase IOP.(18)
- IOP response to intravitreal steroids has been documented in the literature.(29)
- Systemic steroid use is less likely to cause elevations of IOP than topical steroids. (19)
- Periocular injections may also cause elevated IOP, especially long-acting agents are used.

Corticosteroid Glaucoma

- Heschler reported on twelve patients who had IOP rise induced by repository steroids (sub-tenons).
- He found that the severity and duration of the resulting pressure rise was directly related to the solubility of the agent used.
- Ten of the patients had been on prior intensive corticosteroids without IOP elevations.
- Nine of the patients required excision of the depot corticosteroid to normalize their IOP. Normalization occurred within two weeks of incision.
- He suggested starting with a higher solubility agent before moving on to an agent with lower solubility when performing repository steroid injection.

Corticosteroid Glaucoma

Table 44.4
Injectable Corticosteroids

Short acting
Dexamethasone sodium phosphate (Decadron)
Hydrocortisone sodium succinate (Solu-Cortef)
Methylprednisolone sodium succinate (Solu-Medrol)
Intermediate acting
Triamcinolone diacetate (Aristocort)
Methylprednisolone acetate (Depo-Medrol)
Long acting
Triamcinolone acetonide (Kenalog)
Triamcinolone hexacetonide (Aristospan)

From Heschler (27).

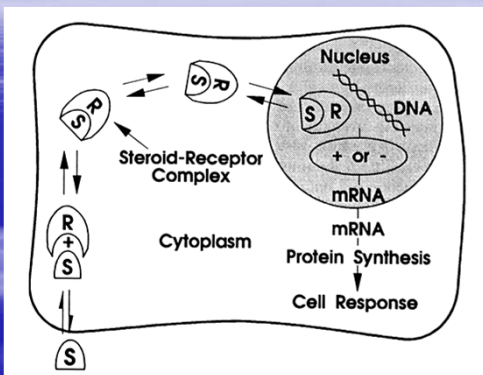
Corticosteroid Glaucoma

Pathophysiology

Recall the mechanism of action of steroid hormones:

- steroid binds with a specific cytoplasmic receptor
- enters the cell then migrates to the cell nucleus
- alters DNA transcription
- results in changes in protein synthesis and cell function

Corticosteroid Glaucoma



Corticosteroid Glaucoma

Pathophysiology

- Corticosteroids raise intraocular pressure by reducing the facility of outflow.
 - The most widely accepted theory is that corticosteroids inhibit catabolism of glycosaminoglycans (GAG)
 - The GAGs then accumulate in the trabecular meshwork obstructing outflow.
 - It has been proposed that corticosteroids stabilize lysosomal membranes, inhibiting release of enzymes which breakdown GAGs. (1)

Corticosteroid Glaucoma

Pathophysiology

- Other theories suggest that corticosteroids inhibit outflow by:
 - inhibiting phagocytosis of foreign material by trabecular endothelial cells, clogging outflow channels. (2)
 - inhibiting the synthesis of Prostaglandin E2 and F2 alpha which are proposed to control intraocular pressure. (3)
 - increasing the expression of TM cellular tight junction protein ZO-1. (7)

Corticosteroid Glaucoma

Pathophysiology

These theories do not explain why some people are more likely to be steroid responders than others.

- Southren et al. studied homogenates of trabecular meshwork taken from eyes with POAG and found marked differences in quantities of enzymes involved in cortisol metabolism.
- An accumulation of 5 Beta-dihydrocortisol was found in POAG eyes.
- 5 beta dihydrocortisol then was shown to heighten the dexamethasone intraocular pressure rise in rabbit eyes. (4, 5 ,6)

Corticosteroid Glaucoma

Pathophysiology

Another theory to explain why some people are more likely to be steroid responders than others:

- Armaly suggested that POAG patients may have pre-existing changes in trabecular meshwork which makes them susceptible to small changes in GAGs.

TIGR / myocilin

- TIGR (TM-inducible glucocorticoid response protein)
- Myocilin = TIGR
- What is the role of TIGR/myocilin gene (and protein)?
- What is the connection between TIGR/myocilin and steroid-induced glaucoma and / or glaucoma in general?

TIGR / myocilin (genetics)

- Myocilin/TIGR originally isolated from cultured human TM cells treated with prolonged dexamethasone (Nguyen 98)
- 55 kD protein with 67 kD glycosolated form
- Shown to be involved in at least some forms of OAG (may not be the major player in POAG)

TIGR / myocilin (Genetics)

- JOAG : AD disease (onset before 30)
- One form of early onset POAG
- One of the loci for JOAG linked to chromosome 1q21-q31 (GLC1A)
- 2 genes map within this region: APTILG1 and TIGR
- Only TIGR showed mutations in patients with disease (Stone and others).

TIGR / myocilin

- Myocilin / TIGR expressed in almost all ocular tissues (Karali IOVS 3/2000), especially TM
- Normal role of myocilin and mechanisms by which mutations cause disease unknown
- Intracellular (cytoplasm vs. perinuclear) vs extracellular location?

TIGR / myocilin

- Widespread distrib. of TIGR: Produced by cells other than TM, or does aqueous location cause circulation and distribution to anterior and posterior locations?
- Does wide distribution of TIGR affect glaucoma (does TIGR in retina/ONH cause glaucoma directly... versus TM obstruction by TIGR)?

TIGR / myocilin

- Does mutation in TIGR protein cause abnormal metabolism, with resultant TM obstruction and elevated IOP?
- Does TIGR mutation cause alteration in cytoskeletal architecture (e.g. assoc. with microtubules, leading to cell shape changes or altered cell-cell interactions)
- TIGR mutations affect aqueous production?

Corticosteroid Glaucoma

Management

1. Obtain baseline IOP before initiating corticosteroid therapy.
2. Check the intraocular pressure every 2-3 weeks for the first few months, then every 2-3 months thereafter if chronic treatment is needed.
3. There is no time period beyond which a patient is incapable of developing corticosteroid glaucoma.
4. When possible use non-steroidal anti-inflammatories or steroid preparations less likely to increase IOP, such as rimexolone (Vexol), flourometholone (FML), medrysone (HMS), loteprednol (Lotemax, Alrex)

Corticosteroid Glaucoma

Management

5. Once a patient is thought to have corticosteroid glaucoma, stopping the steroid drop will usually result in decrease of IOP to baseline within 2 weeks.
6. If IOP is at dangerous level, antiglaucoma medications may be used in addition to stopping steroid drops.
7. Evaluation of IOP elevation in the setting of steroid treatment for chronic iritis can be difficult.
 - Steroids may suppress ciliary body inflammation and return aqueous production to normal, increasing IOP.
 - Steroids may decrease the inflammation in the trabecular meshwork, increasing outflow facility.

Corticosteroid Glaucoma

- A.
Steroids: ↓ inflammation in meshwork → ↑ outflow
 ↓ inflammation in ciliary body → ↑ aqueous production (to normal)
- B.
Steroids: ↑ ↑ inflow / ↑ outflow → ↑ IOP

Corticosteroid Glaucoma

Management

8. If unable to discern between increased inflammation or steroid response as the cause of increased IOP, a trial of increased steroid therapy for several days should be performed:
 - If IOP decreases, inflammation was the cause of the increased IOP
 - If IOP increases, steroid response is more likely and the amount of steroid should be decreased.
9. If repository steroid is responsible, surgical removal of the depot may be necessary.

Corticosteroid Glaucoma


Management

10. Rarely, a filtering procedure may need to be performed if severe and/or prolonged IOP elevation is potentially damaging the optic nerve.

Corticosteroid Glaucoma

CONCLUSION

- A 43 year old male with a positive family history of glaucoma received low solubility intravitreal corticosteroid for treatment of CNV from ocular histoplasmosis. This treatment resulted in over five months of elevated intraocular pressure despite maximal medical therapy. He was monitored closely for glaucomatous damage which did not occur.
- This patient was more likely to be a steroid responder because of his positive family history.
- An depot of steroid within the vitreous contributed to the prolonged steroid response.



References

1. Bill A: The drainage of aqueous humor, Invest Ophthalmol Vis Sci 14:1, 1975
2. Kayes J, Becker B: The trabecular meshwork in corticosteroid-induced glaucoma, Trans Am Ophthalmol Soc 67:354, 1969
3. Weinreb RN, Mitchell MD, Polansky JR: Prostaglandin production by human trabecular cells. In vitro inhibition by dexamethasone, Invest Ophthalmol Vis Sci 26:890, 1985
4. Southren AL, et al: Altered cortisol metabolism in cells cultured from trabecular meshwork specimens obtained from patients with primary open angle glaucoma, Invest Ophthalmol Vis Sci 24:1413, 1983

References

5. Southren AL, et al: 5-Beta dihydrocortisol: possible mediator of the ocular hypertension in glaucoma, Invest Ophthalmol Vis Sci 26: 393, 1985
6. Weinstein BI, Munnangi P, Gordon GG, and Southren, AL: Defects in cortisol-metabolizing enzymes in primary open angle glaucoma, Invest Ophthalmol Vis Sci 26:890, 1985
7. Underwood JL, Alvarado JA, Murphy CG, et al: Steroid-induced decreases in hydraulic conductivity were blocked in human trabecular meshwork cells by an antisense oligonucleotide to ZO-1. Invest Ophthalmol Vis Sci 1994;35 (ARVO Suppl): 2737.
8. Woods AC: Clinical and experiential observation on the use of ACTH and cortisone in ocular inflammatory disease. Am J Ophthalm 1950;33:1325

References

9. Goldmann, H. Cortisone glaucoma, Archives Ophthalmol 68:621, 1962
10. Armaly MF: Effect of corticosteroids on intraocular pressure and fluid Dynamics. I. The effect of dexamethasone in the normal eye. Arch Ophthalmol 1963; 70:482
11. Armaly MF: Effect of corticosteroids on intraocular pressure and fluid Dynamics. I. The effect of dexamethasone in the glaucomatous eye. Arch Ophthalmol 1963; 70:492-499
12. Armaly MF: Statistical attributes of the steroid hypertensive response in the clinically normal eye. Invest Ophthalmol Vis Sci 1965:4:187

References

13. Becker, B. Intraocular pressure response to topical corticosteroids. Invest Ophthalmol Vis Sci 1965; 4:198
14. Schwartz JT. Twin study on ocular pressure after topical dexamethasone. I. Frequency distribution of pressure response, Am J Ophthalmol 76:126, 1973
15. Schwartz JT. Twin study on ocular pressure after topical dexamethasone. II. Inheritance of variations in pressure responses, Arch Ophthalmol 90:281, 1973
16. Wilensky JT, Podos SM, Becker B: Prognostic indicators in ocular hypertension, Arch Ophthalmol 91:200, 1974
17. Kass MA, Johnson T, Corticosteroid-induced Glaucoma. In: The Glaucomas Editors: Ritch, Shields, Krupin. Chapter 64 page 1161-1167

References

18. Dryer EB: Inhaled steroid use and glaucoma. N Engl J. Med 1993; 329:1822
19. Adhikary HP, Sells RA, Basu PK: Ocular complications of systemic steroids after renal transplantation and their association with HLA. Br J Ophthalmology 1982; 66:290
20. Herschler J: Increased intraocular pressure induced by repository corticosteroids. Am J Ophthalmol 1976:82:90
21. Leibowitz HM: Management of inflammation in the cornea and conjunctiva. Ophthalmology 1980 :87:753
22. Cantrill HL, Palmberg PF, Zink HA, et al: Comparison of in vitro potency of corticosteroids with ability to raise intraocular pressure. Am J Ophthalmol 1975;79:1012

References

23. Stewart RH, Kimbrough RL: Intraocular pressure response to topically administered fluorometholone. Arch Ophthalmol 1979;97:2139
24. Kass M, Cheetham J, Duzman E et al: The ocular hypertensive effect of 0.25% FML in corticosteroid responders. Am J Ophthalmol 1986:102:159
25. Johnson DH. Corticosteroid Glaucoma. Chapter 44 in Chandler and Grant's Glaucoma, Fourth Edition, editors: Epstein, Allingham, Schuman. Page 404-411
26. Allingham, RR. Glaucoma Due to Intraocular Inflammation. Chapter 42 in Chandler and Grant's Glaucoma, Fourth Edition, editors: Epstein, Allingham, Schuman. Page 379

References

27. Podos SM, Becker B, Morton WR: High myopia and primary open-angle glaucoma, *Am J Ophthalmology* 62:1039,1966
28. Becker, B: Diabetes mellitus and primary open angle glaucoma: the XXVII Edward Jackson Memorial Lecture, *Am J Ophthalmol* 77:1, 1971
29. Gillies MC, Simpson JM, Billson FA, Luo W, Penfold P, Chua W, Mitchell P, Zhu M, Hunyor AB. Safety of an intravitreal injection of triamcinolone: results from a randomized clinical trial. *Arch Ophthalmol.* 2004 Mar;122(3):336-40.
