

Consensus Statement of the European Group on Graves' Orbitopathy (EUGOGO) on Management of Graves' Orbitopathy*

Luigi Bartalena,¹ Lelio Baldeschi,² Alison J. Dickinson,³ Anja Eckstein,⁴ Pat Kendall-Taylor,⁵ Claudio Marcocci,⁶ Maarten P. Mourits,⁷ Petros Perros,⁸ Kostas Boboridis,⁹ Antonella Boschi,¹⁰ Nicola Currò,¹¹ Chantal Daumerie,¹² George J. Kahaly,¹³ Gerasimos Krassas,¹⁴ Carol M. Lane,¹⁵ John H. Lazarus,¹⁶ Michele Marinò,⁶ Marco Nardi,¹⁷ Christopher Neoh,³ Jacques Orgiazzi,¹⁸ Simon Pearce,¹⁹ Aldo Pinchera,⁶ Susanne Pitz,²⁰ Mario Salvi,²¹ Paolo Sivelli,²² Matthias Stahl,²³ Georg von Arx,²⁴ and Wilmar M. Wiersinga²⁵

Introduction

GRAVES' ORBITOPATHY (GO) constitutes a major clinical and therapeutic challenge (1,2). GO is an autoimmune disorder representing the commonest and most important extrathyroidal manifestation of Graves' disease, but it may occur in patients without current or prior hyperthyroidism (euthyroid or ophthalmic Graves' disease) or in patients who are hypothyroid due to chronic autoimmune (Hashimoto's) thyroiditis (3,4). Although the pathogenesis of GO (5–9) is beyond the scope of this document, attention is drawn to the link between the orbit and thyroid, which has important clinical and therapeutic implications. Optimal management of GO requires a coordinated approach addressing the thyroid dysfunction and the orbitopathy (10,11).

GO is often mild and self-limiting, and probably declining in frequency, with only 3–5% of cases posing a threat to eyesight (3,4). The onset and progression of GO are influenced by factors that are potentially controllable such as cigarette smoking, thyroid dysfunction, and choice of treatment modalities for hyperthyroidism (12,13).

Suboptimal management of patients with GO appears to be widespread (2). The objectives of this document are to provide practical information for managing patients with GO, for both nonspecialists and those with special interest and expertise in this condition, and thus to improve the outcomes of patients with GO. It is hoped that the document will also be useful to specialist nurses, orthoptists, and those involved in managerial roles and that it will provide a focus for audit and research. Randomized clinical trials (RCTs) are infrequent

¹Department of Clinical Medicine, University of Insubria, Varese, Italy.

²Department of Ophthalmology, Academic Medical Center, Amsterdam, the Netherlands.

³Department of Ophthalmology, Royal Victoria Infirmary, Newcastle upon Tyne, United Kingdom.

⁴Department of Ophthalmology, University of Essen, Essen, Germany.

⁵Medical School, University of Newcastle upon Tyne, Newcastle upon Tyne, United Kingdom.

⁶Department of Endocrinology, University of Pisa, Pisa, Italy.

⁷Orbital Center, Department of Ophthalmology, Academic Medical Center, Amsterdam, the Netherlands.

⁸Department of Endocrinology, Freeman Hospital, Newcastle upon Tyne, United Kingdom.

⁹University Department of Ophthalmology, Ahepa Hospital, Thessaloniki, Greece.

¹⁰Department of Ophthalmology, Université Catholique de Louvain, Cliniques Universitaires, Brussels, Belgium.

¹¹Department of Ophthalmology, University of Milan, Milan, Italy.

¹²Université Catholique de Louvain, Cliniques Universitaires, Brussels, Belgium.

¹³Department of Medicine I, Gutenberg University Hospital, Mainz, Germany.

¹⁴Department of Endocrinology, Panagia General Hospital, Thessaloniki, Greece.

¹⁵Cardiff Eye Unit, University Hospital of Wales, Heath Park, Cardiff, United Kingdom.

¹⁶School of Medicine, Cardiff University, Llandough Hospital, Cardiff, United Kingdom.

¹⁷Department of Neuroscience, Section of Ophthalmology, University of Pisa, Pisa, Italy.

¹⁸Department of Endocrinology, Centre Hospitalier Lyon-Sud, Lyon, France.

¹⁹School of Clinical Medical Sciences, Newcastle University, Newcastle upon Tyne, United Kingdom.

²⁰Department of Ophthalmology, Johannes Gutenberg-University, Mainz, Germany.

²¹Department of Medical Sciences, University of Milan, Milan, Italy.

²²Department of Ophthalmology, University of Insubria, Varese, Italy.

²³Department of Endocrinology, Solothurner Spitaler, Switzerland.

²⁴Interdisziplinäres Zentrum für Endokrine Orbitopathie, Olten, Switzerland.

²⁵Department of Endocrinology, Academic Medical Center, Amsterdam, the Netherlands.

*This paper is also being published in the March 2008 issue of the journal, *European Journal of Endocrinology*, vol. 158, no. 3.

in this field. The document therefore should be considered as a consensus statement rather than a guideline.

Methods

EUGOGO represents a multidisciplinary consortium of clinicians from European centers, who share a commitment to improving the management of patients with GO (www.eugogo.org). A Working Group was formed and met in November 2006. Subsequent discussions took place electronically and at a further meeting in May 2007. After revision the document was posted on the European Thyroid Association (ETA) and the European Society of Ophthalmic Reconstructive and Plastic Surgeons (ESORPS) websites for wider consultation. The document was presented at the ETA annual meeting in Leipzig, Germany, in September 2007. Relevant articles were identified by searching MEDLINE using the terms Graves' ophthalmopathy or orbitopathy, thyroid-associated ophthalmopathy or orbitopathy, thyroid-eye disease. The definition of Types of Evidence and the Grading of Recommendations used follows that of the Agency for Health Care Policy and Research (AHCPR), now Agency for Healthcare Research and Quality (AHRQ) (www.ahrq.gov), as set out in Table 1.

Recommendations

Referral to combined thyroid-eye clinics and initial assessment (Box 1)

Should all patients with GO be referred to combined thyroid-eye clinics (10)?

- All patients with GO, except for the mildest cases, should either be managed by a physician with particular expertise in managing GO or should better be referred to a combined thyroid-eye clinic for further assessment and management.
- Many patients with GO never reach combined thyroid-eye clinics or are referred too late to benefit from treatments (2).

- This practice is undesirable and may result in a suboptimal outcome and sometimes loss of vision.

A simple tool for assessing patients by generalists is recommended (1) and is summarized in Box 1.

Management issues of GO that should be addressed by both nonspecialists and specialists

Smoking and GO (Box 2)

Is smoking related to the occurrence, severity, and progression of GO?

- There is strong and consistent association between smoking and GO (12–24).
- Smokers suffer more severe GO (14,15,17) than non-smokers.
- A dose-response relationship between numbers of cigarettes smoked per day and probability of developing GO has been demonstrated (21).
- Smoking increases the likelihood of progression of GO after radioiodine therapy for hyperthyroidism (25–27).
- Some evidence suggests that smoking either delays or worsens the outcomes of treatments for GO (28,29).
- There is some retrospective evidence that quitting smoking is associated with a better outcome of GO (19,21).

Management of hyperthyroidism in patients with GO (Box 3)

Is correction of thyroid dysfunction important for GO?

- Patients with uncontrolled thyroid function (both hyper- and hypothyroidism) are more likely to have severe GO than patients with euthyroidism (30–32).

Is there a relationship between modality of treatment for hyperthyroidism and the course of GO?

- Antithyroid drug therapy (27,30,33) and thyroidectomy do not affect the course of GO (26,34–36), although the role of the latter requires further investigation.

TABLE 1. TYPES OF EVIDENCE AND THE GRADING OF RECOMMENDATIONS

1. Type of evidence (based on Agency for Health Care Policy and Research, AHCPR, 1992)

Level Type of evidence

Ia	Evidence obtained from meta-analysis of randomized controlled trials.
Ib	Evidence obtained from at least one randomized controlled trial.
IIa	Evidence obtained from at least one well-designed controlled study without randomization.
IIb	Evidence obtained from at least one other type of well-designed quasi-experimental study.
III	Evidence obtained from well-designed nonexperimental descriptive studies, such as comparative studies, correlation studies, and case-control studies.
IV	Evidence obtained from expert committee reports or opinions and/or clinical experience of respected authorities.

2. Grading of recommendations (based on Agency for Healthcare Research and Quality, AHRQ, 1994)

Grade	Evidence levels	Description
A	Ia, Ib	Requires at least one randomized controlled trial as part of the body of literature of overall good quality and consistency addressing the specific recommendation.
B	IIa, IIb, III	Requires availability of well-conducted clinical studies but no randomized clinical trials on the topic of recommendation.
C	IV	Requires evidence from expert committee reports or opinions and/or clinical experience of respected authorities. Indicates absence of directly applicable studies of good quality
√		Good practice point recommended by consensus development group

Box 1 Tools for referral of patients with GO to combined thyroid-eye clinics

Primary care physicians, general practitioners, general internists and specialists, who have no particular expertise in managing GO, should refer patients with GO, except for the mildest cases, to combined thyroid-eye clinics for further assessment and management (IV,C).

Assessments and criteria for referral recommended by EUGOGO (IV, C).

-Patients with a history of Graves' disease, who have neither symptoms nor signs of GO, require no further ophthalmological assessments and need not be referred to a combined thyroid-eye clinic.

-Patients with unusual presentations (unilateral GO or euthyroid GO) should be referred however mild their symptoms or signs, in order to make an accurate diagnosis.

-All other cases should be screened according to the protocol below (IV, C), as previously recommended by Wiersinga et al. (1):

Refer urgently if any of the following are present:

Symptoms

Unexplained deterioration in vision

Awareness of change in intensity or quality of colour vision in one or both eyes

History of eye(s) suddenly 'popping out' (Globe subluxation)

Signs

Obvious corneal opacity

Cornea still visible when the eyelids are closed

Disc swelling

Refer non-urgently if any of the following are present:

Symptoms

Eyes abnormally sensitive to light: troublesome or deteriorating over the past 1–2 months

Eyes excessively gritty and not improving after 1 week of topical lubricants

Pain in or behind the eyes: troublesome or deteriorating over the past 1–2 months

Progressive change in appearance of the eyes and/or eyelids over the past 1–2 months

Appearance of the eyes has changed causing concern to the patient

Seeing two separate images when there should only be one

Signs

Troublesome eyelid retraction

Abnormal swelling or redness of eyelid(s) or conjunctiva

Restriction of eye movements or manifest strabismus

Tilting of the head to avoid double vision

The reader is referred to Table 1 for an explanation of the recommendations grading system.

- No particular antithyroid drug or regimen, nor any type of thyroidectomy (subtotal or total) has been demonstrated to have any advantages in terms of outcome of GO.
- The few available RCTs on the effects of radioiodine therapy on GO show that a definite proportion of pa-

tients (~ 15%) develop new eye disease or experiences progression of pre-existing GO within 6 months after radioiodine (25–27). In approximately 5% of patients worsening persisted at 1 year and required additional treatment (25). This risk is almost eliminated by giving a short course (about 3 months) of oral glucocorticoids

Box 2 Smoking and GO

All patients with Graves' disease should be informed of the risks of smoking for GO (IV, C) emphasising the detrimental effects of smoking on:

-development of GO (IIb, B)

-deterioration of pre-existing GO (IIb, B)

-effectiveness of treatments for GO (IIb, B)

-progression of GO after radioiodine treatment (Ib, A)

If advice alone is ineffective, referral to smoking cessation clinics, or other smoking cessation strategies should be considered (IV, C).

Box 3 Management of hyperthyroidism and GO

Euthyroidism should be restored promptly and maintained stably in all patients with GO (III, B).

Frequent monitoring of thyroid status (every 4-6 weeks) is imperative in the initial phases of treatment when changes in thyroid status are expected (IV, C).

Patients with active GO given radioiodine should be offered prophylactic steroid cover (commencing with 0.3-0.5 mg of prednisone/kg bw per day orally 1-3 days after radioiodine and tapering the dose until withdrawal about 3 months later) (Ib, A). Shorter periods of glucocorticoid therapy (1-2 months) may be equally protective (IV, C).

Patients with inactive GO can safely receive radioiodine without steroid cover, as long as hypothyroidism is avoided (IIb, B), particularly if other risk factors for GO progression, such as smoking, are absent (IV, C).

(GCs) after radioiodine (25, 27), and avoiding post-treatment hypothyroidism (32). Shorter administration of oral GCs (1-2 months) is probably equally protective, but different dose regimens have not systematically been investigated.

- The risk of exacerbation of pre-existing GO is negligible in patients with inactive eye disease, as long as post-radioiodine hypothyroidism is avoided (37,38), and other risk factors for GO progression, including smoking (28) and high (> 7.5 IU/L) thyrotropin-receptor antibody levels (39), are absent (40).

Other simple measures that may alleviate symptoms (Box 4)

Are there worthwhile simple measures that can relieve some of the symptoms of GO?

- Symptoms of corneal exposure (grittiness, watering, and photophobia) often accompany active GO and may persist if lid retraction is severe. Such patients benefit from lubricants (3,4).
- Nocturnal ointment is of great benefit for incomplete eyelid closure provided the cornea is protected (3,4). Otherwise, urgent intervention will be required.
- Prisms may control intermittent or constant diplopia, sleeping with head up may reduce morning eyelid swelling. Diuretics are rarely useful.
- Botulinum toxin injection can reduce upper lid retraction (41), but this procedure should be carried out in specialist centers.

Management issues of GO that should be addressed in specialists centers

Grading severity and activity of GO (Box 5 and Box 6)

What protocol should be followed for detailed assessment of patients with GO in specialist centers?

- Making treatment decisions for patients with GO requires detailed assessment of the eyes, understanding of the natural history of the disease, insight into the impact of GO on the individual patient (42), and appreciation of the efficacy and side effects of therapies.

Is it helpful to grade the severity of GO?

- Grading the severity of GO is fraught with difficulties, however classifying patients into broad categories facilitates decision-making (Fig. 1).
- Careful assessment of the impact of GO on quality of life (QoL) by disease-specific questionnaire (GO-QoL) (42) is fundamental in deciding whether treatments used for moderate to severe GO (see below) are justified in patients with mild GO.

Is it helpful to grade the activity of GO?

- Grading the activity of GO is also fraught with difficulties, however classifying patients into active/inactive GO categories is frequently possible and greatly facilitates decision-making (Fig. 1). Patients with a Clinical Activity Score (CAS) $\geq 3/7$ should be considered as having active GO (43,44).

Box 4 Simple measures that may alleviate symptoms in GO

Lubricant eye drops during the day and/or lubricant ointments at night-time are recommended for all patients with GO who have symptoms of corneal exposure (III, B).

Patients with symptomatic diplopia should be given prisms if appropriate (IV, C).

Botulinum toxin injection may be considered for upper lid retraction in centres who have experience and expertise in this technique (IV, C).

Box 5 Activity and severity assessments in GO

EUGOGO recommends the following assessments for patients with GO in specialist centres (IV, C), as previously reported by Wiersinga *et al.* (1):

(a) Activity measures based on the classical features of inflammation: clinical activity score (CAS) is the sum of all items present (43, 44)

- Spontaneous retrobulbar pain
 - Pain on attempted up- or down gaze
 - Redness of the eyelids
 - Redness of the conjunctiva
 - Swelling of the eyelids
 - Inflammation of the caruncle and/or plica
 - Conjunctival oedema
- A CAS $\geq 3/7$ indicates active GO

(b) Severity measures

- Lid aperture (distance between the lid margins in mm with the patient looking in the primary position, sitting relaxed and with distant fixation)
- Swelling of the eyelids (absent/equivocal, moderate, severe)¹
- Redness of the eyelids (absent/present)¹
- Redness of the conjunctivae (absent/present)¹
- Conjunctival oedema (absent, present)¹
- Inflammation of the caruncle or plica (absent, present)¹
- Exophthalmos (measured in mm using the same Hertel exophthalmometer and same intercanthal distance for an individual patient)
- Subjective diplopia score (0 = no diplopia; 1 = intermittent, i.e. diplopia in primary position of gaze, when tired or when first awakening; 2 = inconstant, i.e. diplopia at extremes of gaze; 3 = constant, i.e. continuous diplopia in primary or reading position)
- Eye muscle involvement (ductions in degrees)¹
- Corneal involvement (absent/punctate keratopathy/ulcer)
- Optic nerve involvement (best corrected visual acuity, colour vision, optic disc, relative afferent pupillary defect (absent/present), plus visual fields if optic nerve compression is suspected)

¹www.eugogo.org

Management of sight-threatening GO
(Box 7 and Box 8)

How can patients with sight-threatening GO be identified?

- Sight-threatening GO usually occurs in the context of dysthyroid optic neuropathy (DON).
- The risk of corneal breakdown and perforation is significant when lagophthalmos is associated with poor Bell's phenomenon (45).
- Sight can also be threatened in patients with GO in the following rare circumstances: eyeball subluxation, severe forms of frozen globe in the presence of lagophthalmos, choroidal folds, and postural visual obscuration (46).

Box 6 Severity classifications in GO

EUGOGO recommends the following classification of patients with GO (IV, C):

1. **Sight-threatening GO:** patients with dysthyroid optic neuropathy (DON) and/or corneal breakdown. This category warrants immediate intervention.
2. **Moderate to severe GO:** patients without sight-threatening GO whose eye disease has sufficient impact on daily life to justify the risks of immunosuppression (if active) or surgical intervention (if inactive). Patients with moderate to severe GO usually have any one or more of the following: lid retraction ≥ 2 mm, moderate or severe soft tissue involvement, exophthalmos ≥ 3 mm above normal for race and gender, inconstant or constant diplopia.
3. **Mild GO:** patients whose features of GO have only a minor impact on daily life insufficient to justify immunosuppressive or surgical treatment. They usually only have one or more of the following: minor lid retraction (<2mm), mild soft tissue involvement, exophthalmos < 3 mm above normal for race and gender, transient or no diplopia, corneal exposure responsive to lubricants.

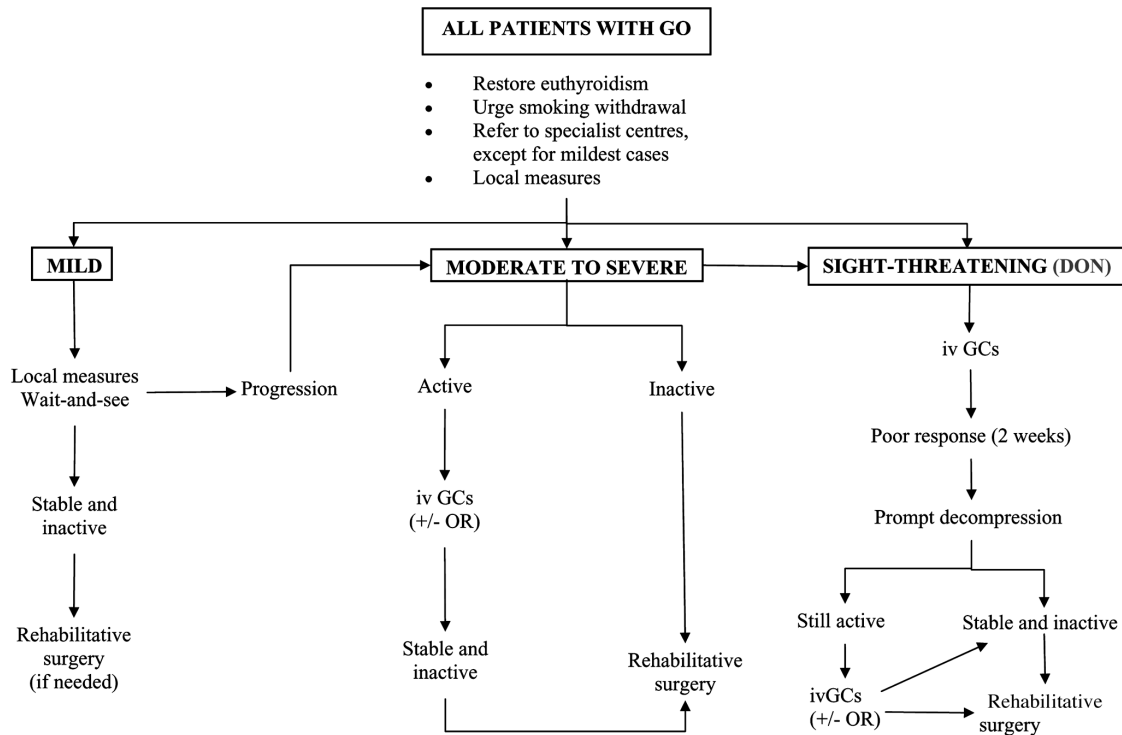


FIG. 1. Management of Graves' orbitopathy. Rehabilitative surgery includes orbital decompression, squint surgery, lid lengthening, blepharoplasty/browplasty. IV GCs, intravenous glucocorticoids; OR, orbital radiotherapy; DON, dysthyroid optic neuropathy. For definitions of GO severity and activity see text.

- The above clinical entities require recognition and prompt medical attention (1). Box 1 can be used to identify patients with sight-threatening GO.

What is the treatment of choice for dysthyroid optic neuropathy (DON)?

- DON can be treated by systemic glucocorticoids (GCs), surgery, or both.
- Orbital radiotherapy is not recommended in the case of DON unless as an adjunct to proven therapies.
- High-dose intravenous (IV) GCs administered in pulses are more efficacious and associated with fewer adverse

effects than oral or retrobulbar steroids (3,4,47–51) (Table 2).

- Improvement of optic nerve function can be expected after high-dose IV GCs within 1–2 weeks (52).
- Relapse of DON may occur when systemic GCs are withdrawn too quickly (see Management of Moderate to Severe GO) (3,4).
- Decompression surgery can lead to rapid resolution of DON with an acceptable adverse effect profile. However, GCs and squint surgery are frequently required, and occasionally further decompression surgery is necessary (53). Immediate decompression surgery as first

Box 7 Glucocorticoids and orbital decompression in DON

Glucocorticoids (GCs) and surgical decompression of the orbit are the only treatments proven to be effective in patients with DON (III, B).

High-dose iv GCs is the preferred first-line treatment for DON (III, B).

If the response to iv GCs is absent or poor after 1–2 weeks, or the dose/duration of steroid required induces significant side effects, prompt orbital decompression should be carried out (IV, C).

Orbital decompression should be offered promptly to patients with DON or corneal breakdown who cannot tolerate GCs (III, B).

Both iv GC therapy and orbital decompression surgery should only be undertaken in centres with appropriate expertise (IV, C).

Box 8 Sight-threatening corneal breakdown in GO

Sight-threatening corneal breakdown should be managed as an emergency (IV, C).

The management of sight-threatening corneal breakdown includes:

Frequent topical lubricants (preservative-free topical lubricants for hyperallergic patients), moisture chambers, blepharoraphy, tarsorrhaphy or other temporary measures until the cornea has healed (IV,C).

Consideration of systemic GCs or surgical decompression when the above measures alone are ineffective (IV, C).

In the event of corneal perforation/severe ulceration, appropriate antibiotics, and emergency glueing, amnion membrane as shield, or corneal grafting need to be considered (IV, C).

Once the corneal breakdown is brought under control, it is imperative that treatment is offered to improve lid closure and thus prevent further episodes of corneal breakdown (IV, C).

choice therapy does not appear to result in a better outcome compared to IV GCs as first choice, nor does it obviate the need for subsequent GC therapy (54).

What is the treatment of choice for sight-threatening corneal breakdown?

- In severe, sight-threatening corneal breakdown when the cornea cannot be protected by the closed eyelid, hourly topical lubricants are indicated, however, this intervention alone may be insufficient to prevent ulceration, thinning, and perforation. In such cases specific measures to improve eyelid closure are required.
- A moisture chamber or temporary eye closure by blepharoraphy or tarsorrhaphy, or botulinum toxin injections can help temporize until corneal healing occurs (55).
- The effect of GCs on severe corneal exposure has never been specifically addressed.
- Most of the studies on the effects of orbital decompression report a reduction in symptoms associated with exposure keratopathy; rarely severe corneal ulcers may be refractory to decompression surgery if lagophthalmos persists (56).

Management of moderate to severe GO (Box 9 and Box 10)

Does every patient with moderate to severe GO require treatment?

- Many patients in this category should be considered for treatment, with the exception of patients who are asymptomatic or unwilling to have treatment.
- Patients with moderate to severe and active (CAS $\geq 3/7$) GO should be treated with immunosuppressive treatment modalities, while those with inactive GO may benefit from rehabilitative surgery (see below) (Fig. 1).

What are the nonsurgical treatments of choice for moderate to severe GO?

- Glucocorticoids. GC therapy has been used in the management of GO through oral, local (retrobulbar or subconjunctival) or IV routes (35). Oral GC therapy (starting dose, 80–100 mg prednisone [or about 1 mg/kg bw] or equivalent) requires high doses for prolonged periods of time. No randomized, placebo-controlled studies have been performed. Open trials or randomized studies in which oral GC were compared with other treatments (47,48,50,57–62) show a favorable response in about 33–63% of patients, particularly for soft tissue changes, recent onset eye muscle involvement, and DON. The eye disease frequently flares up on tapering or withdrawing GCs. Side effects are frequent. Prolonged oral GC treatment is associated with a risk of osteoporosis (49), which may be decreased using bisphosphonates or other antiresorptive drugs (63,64). Retrobulbar or subconjunctival GC therapy is less effective than oral GCs (65). IV GC pulse therapy is more

TABLE 2. RANDOMIZED CLINICAL TRIALS OF INTRAVENOUS METHYLPREDNISOLONE VERSUS ORAL PREDNISONE

Treatment randomization		Response rate			Reference
Group A	Group B	Group A	Group B	P value	
Intravenous methylprednisolone ^a + radiotherapy ^b (n = 41)	Oral prednisone ^c + radiotherapy ^b (n = 41)	88%	63%	< 0.02	Marcocci et al. (47)
Intravenous methylprednisolone ^d (n = 35)	Oral prednisone ^e (n = 35)	77%	51%	< 0.01	Kahaly et al. (50)

^a15 mg/kg for four cycles, then 7.5 mg/kg for four cycles; each cycle consisted of two infusions on alternate days at 2-week intervals.

^b20 Gy in 10 daily doses of 2 Gy over 2 weeks.

^c100 mg daily for 1 week, then weekly reduction until 25 mg daily, then tapering by 5 mg every 2 weeks.

^d500 mg once weekly for 6 weeks, 250 mg once weekly for 6 weeks, total treatment period: 12 weeks.

^e100 mg daily starting dose, tapering by 10 mg per week, total treatment period: 12 weeks.

Box 9 Treatment of moderate to severe GO that is ACTIVE

The treatment of choice for moderate to severe and active (CAS \geq 3/7) GO is pulses of iv glucocorticoids (GCs) (Ib, A). This treatment should be undertaken in centres with appropriate expertise (IV, C).

The total cumulative dose of methylprednisolone should not exceed 8 g in one course of therapy (III, B).

Patients being treated with high dose iv GC should be first screened for liver dysfunction, hypertension, history of peptic ulcer, diabetes, urine infections and glaucoma, and then monitored for side-effects (IV, C).

Bisphosphonates are recommended when long-term (>3 months) oral GC therapy (average daily dose > 5 mg prednisone or equivalent) is used (Ia, A). It is reasonable to suggest the use of antiresorptive agents also when GCs are used iv (IV, C).

Orbital irradiation (OR) should be considered in patients with active disease who have diplopia or restricted motility (Ib, A). OR with lower cumulative doses (10 Gy) may be as effective as and better tolerated than OR with higher doses (20 Gy)(Ib, A). Doses > 20 Gy are not recommended (IV, C).

Caution should be exercised before administering OR to patients younger than 35 years; OR must be avoided in patients with diabetic retinopathy or severe hypertension (III, B).

The combination of oral GCs with OR is more effective than either treatment alone (Ib, A), but randomized clinical trials indicating that combination of iv GCs with OR is better than iv GCs alone are lacking (IV, C).

effective than oral GC (response rates \sim 80% vs. \sim 50%; Table 2) (3,4,47–51,66). Evidence for the superiority of any of the different IV GC schedules is lacking (Table 2). Although IV GCs are tolerated better than oral GCs (47,50), acute liver damage and a risk of life-threatening liver failure has been reported in association with very high cumulative doses (67,68) in about 0.8% of patients (68). IV GCs are safe if the cumulative dose is less than 8 g methylprednisolone in one course of therapy (69). Bisphosphonates should be considered for patients receiving IV GCs, although no RCTs have specifically addressed this issue.

- Orbital radiotherapy. The reported response rate to orbital radiotherapy (OR) in open trials is \sim 60% (3,4,66). A cumulative dose of 20 Gy per orbit fractionated in 10 doses over a 2-week period is commonly used (70), but an alternative regimen of 1 Gy per week over a 20-week period was equally effective and better tolerated (71). Higher doses are no more effective (72). A lower cumulative dose of 10 Gy was found to be as effective as the standard 20 Gy regimen (71). The response to OR did not differ from oral prednisone in a RCT (60). Two

recent RCTs have shown that OR is more effective than sham irradiation in improving diplopia and eye muscle motility (73,74). Another RCT has questioned the efficacy of OR (75). OR is usually well tolerated, but may cause transient exacerbation of ocular symptoms, which is preventable with concomitant GC administration (3,66). Data on long-term safety are reassuring (76–78), but theoretical concerns about carcinogenesis remain for younger patients, particularly those under the age of 35 years (70,76–78). Although cataracts can occur earlier after OR than naturally, they are easily treated by surgery. Retinal microvascular abnormalities have been detected in a minority of patients (79), mostly in those with concomitant severe hypertension or diabetic retinopathy, and these two comorbidities are considered absolute contraindications to OR (80,81). It is possible that diabetes, even in the absence of retinopathy, represents a risk factor for the development of retinal changes after OR (78), but the evidence is less clear (77). Thus, diabetes without retinopathy may be regarded as a relative contraindication to OR (see also Box 12).

Box 10 Timing and order of surgery for GO

The timing and order of surgical interventions should be carefully planned (IV, C).

Surgical management should proceed in the following sequence: orbital decompression, then squint surgery, then lid lengthening with or followed by blepharoplasty/browplasty, since side effects of the preceding step can interfere with the step that follows (III, B).

Rehabilitative surgery should only be performed in patients who have had inactive GO for at least 6 months (III, B).

Rehabilitative surgery should only be undertaken in centres with appropriate expertise (IV, C).

Box 11 Management of mild GO

Glucocorticoids are rarely justified in mild GO as the risks outweigh the benefits (IV, C).

Watchful waiting is appropriate for the majority of patients with mild GO (IV, C).

In a minority of patients with mild disease, quality of life may be so profoundly affected as to justify using treatments as for moderate to severe disease (IV, C).

- Combination of GC (either orally or locally) with OR is more effective than either treatment alone (57,82). It is unclear whether IV GCs with OR are more efficacious than IV GCs alone.
- Treatments of marginal or unproven value include somatostatin analogs (83–86), azathioprine (87), ciamexone (88), and IV immunoglobulins (62,89). Two studies have shown the superiority of the combination of oral GCs and cyclosporine than either treatment alone (58,59). The potential usefulness of immunomodulatory agents, such as rituximab (90) or etanercept (91), has been suggested by open studies, but no RCTs have been carried out as yet.

Do nonsurgical treatments reduce the subsequent need for rehabilitative surgery or do they adversely interfere with it?

- No RCTs have been performed to investigate specifically whether nonsurgical treatments reduce the subsequent need for rehabilitative surgery, so this important question remains unanswered.
- The theoretical concern that radiation-induced fibrosis may reduce orbital compliance and hence compromise subsequent therapies, is not supported by the available evidence (92,93).

What is the role of surgery in moderate to severe GO?

- Rehabilitative surgery includes one or more of the following procedures: 1) orbital decompression (the usual indications being disfiguring exophthalmos, and/or troublesome retroocular pain/discomfort, and/or grittiness associated with minor exposure keratopathy not amenable to topical therapies (94), 2) squint correction, 3) lid lengthening, and 4) blepharoplasty/browplasty. If more than one procedure is required, the sequence should be as outlined above.
- Orbital decompression for disfiguring exophthalmos is best deferred until the orbitopathy has been inactive for at least 6 months. However orbital decompression can also be considered in patients with active GO who are intolerant or nonresponsive to GCs, if waiting for spontaneous inactivation of GO can potentially be hazardous for visual function.
- Almost all studies show the efficacy and relative safety of orbital decompression (46,94–101); however, the available studies do not allow any meaningful comparison of the available techniques (93,94,100,101).
- Eye muscle surgery and lid surgery are effective treatments for correcting diplopia and for improving lid function and appearance.

- Rehabilitative surgery yields best results when GO is inactive. Very long duration of GO is no contraindication to rehabilitative decompression (100).

Does orbital decompression compromise subsequent non-surgical therapy?

- In the rare event of reactivation of GO after rehabilitative surgery, systemic GCs and/or OR can be used with the usual expected efficacy (99).

Management of mild GO (Box 11)

Are glucocorticoids and/or orbital radiotherapy indicated or useful in mild GO?

- Although GCs and OR are of potential value in mild disease (60,73,74), they are usually not recommended as the risks outweigh the benefits. Simple measures (Box 4) are usually sufficient.

Is a “wait and see” strategy reasonable?

- GO is a self-limiting disease. In the absence of efficacious treatments with minimal side effects, watchful waiting is appropriate for the majority of patients with mild disease, especially those with a satisfactory quality of life, as assessed by the EUGOGO questionnaire (www.eugogo.org).

How should mild eyelid retraction, soft tissue swelling, and exophthalmos be managed and when in the course of the orbital disease?

- Sometimes even mild eyelid retraction, soft tissue swelling, or exophthalmos have a profoundly negative impact on psychosocial functioning and quality of life, depending on the circumstances of the individual (102,103).
- Treatment might be offered to these patients if careful consideration of risks and benefits favors intervention.

Special situations (Box 12 and Box 13)

How should a diabetic or hypertensive patient with moderate to severe or sight-threatening GO be treated?

- Systemic GCs can induce or exacerbate diabetes and/or hypertension. However, the indications for steroid use in patients with diabetes and/or hypertension are no different than in other patients. Close monitoring of glycemic control and blood pressure is important. Thiazide or loop diuretics should be used with caution during

Box 12 Diabetes or hypertension and GO

Diabetes and/or hypertension should not be considered as contraindications to GC or surgical treatments for GO (IV, C).

Diabetic retinopathy and/or severe hypertension are absolute contraindications for OR (III, B).

Diabetes without retinopathy is a relative contraindication for OR, but evidence is less clear (IV, C).

Box 13 GO in children

Euthyroidism should be restored promptly and maintained in children as in adults (III, B)

Children with GO should be managed conservatively if vision is not threatened (IV, C).

Simple measures to address specific symptoms can be utilised as for adults (Box 4) (IV, C).

Glucocorticoids should be avoided in children (IV, C).

Orbital radiotherapy is contraindicated in children (IV, C).

Exposure to active and, possibly, passive smoking should be avoided (IV, C)

high-dose GC therapy to avoid hypokalemia. The same principle applies to surgical treatments.

- OR may increase the risk of retinopathy in diabetic and hypertensive patients. (77,78,80,81), at least using a 20-Gy cumulative dose.
- Diabetes and/or hypertension are not contraindications to surgical orbital decompression or other surgical treatments for GO.

What is the best therapeutic approach to GO in childhood?

- GO is rare in childhood because of the low incidence of Graves' disease in this age group (104,105). The eye disease is usually milder in children than in adults and often stabilizes and eventually resolves without intervention (105).
- Achieving and maintaining euthyroidism are as important objectives as in adult patients.
- Exposure to smoking (active and, possibly, passive) is probably as detrimental as in adults (106–108).
- Because of the effects on growth, GCs should be avoided unless DON is present. OR is contraindicated in children. Somatostatin analogs have been used in isolated cases, but RCTs on efficacy and safety are lacking (109).
- Orbital surgery may be necessary in cases of severe exophthalmos, but for most patients a conservative and expectant approach is appropriate.

Summary of consensus (Fig. 1)

All patients with GO should: be referred to specialist centers, be encouraged to quit smoking, and receive prompt treatment in order to restore and maintain euthyroidism.

Patients with sight-threatening GO should be treated with IV GCs as the first-line treatment; if response is poor after 1–2 weeks, they should be submitted to urgent surgical decompression. The treatment of choice for moderate to severe GO is IV GCs (with or without OR) if the orbitopathy is active; surgery (orbital decompression and/or squint surgery and/or eyelid surgery in this order) should be considered if the orbitopathy is inactive. In patients with mild GO, local measures and an expectant strategy are sufficient in most cases, but treatment may be justified if quality of life is affected significantly.

In Memoriam

This document is dedicated to the memory of Mark Prummel (1956–2005), one of the founders of EUGOGO, who greatly contributed in expanding our understanding of clinical and therapeutic aspects of GO.

Disclosure

The authors declare that there was neither financial support to this study nor conflict of interest that would prejudice its impartiality.

References

1. Wiersinga WM, Perros P, Kahaly GJ, Mourits MP, Baldeschi L, Boboridis K, Boschi A, Dickinson AJ, Kendall-Taylor P, Krassas GE, Lane CM, Lazarus JH, Marcocci C, Marinò M, Neoh C, Orgiazzi J, Pinchera A, Pitz S, Prummel MF, Sartini MS, Stahl M, von Arx G 2006 Clinical assessment of patients with Graves' orbitopathy: the European Group on Graves' Orbitopathy recommendations to gen-

- eralists, specialists and clinical researchers. *Eur J Endocrinol* **155**:387–389.
2. Perros P, Baldeschi L, Boboridis K, Dickinson AJ, Hullo A, Kahaly GJ, Kendall-Taylor P, Krassas GE, Lane CM, Lazarus JH, Marcocci C, Marinò M, Mourits MP, Nardi M, Orgiazzi J, Pinchera A, Pitz S, Prummel MF, Wiersinga WM 2006 A questionnaire survey on the management of Graves' orbitopathy in Europe. *Eur J Endocrinol* **155**: 207–211.
 3. Bartalena L, Pinchera A, Marcocci C 2000 Management of Graves' ophthalmopathy: reality and perspectives. *Endocr Rev* **21**:168–199.
 4. Perros P, Dickinson AJ 2005 Ophthalmopathy. In: Braverman LE, Utiger RD (eds) *Werner's & Ingbar's The Thyroid—A Fundamental and Clinical Text*, 9th ed. Lippincott Williams & Wilkins, Philadelphia, pp 474–487.
 5. Weetman AP 2000 Graves' disease. *N Engl J Med* **343**:1237–1248.
 6. Wiersinga WM, Prummel MF 2001 Pathogenesis of Graves' ophthalmopathy—current understanding. *J Clin Endocrinol Metab* **86**:501–503.
 7. Ludgate M, Baker G 2004 Inducing Graves' ophthalmopathy. *J Endocrinol Invest* **27**:211–215.
 8. Lazarus JH, Marinò M 2007 Orbit-thyroid relationship. In: Wiersinga WM, Kahaly GJ (eds) *Graves' Orbitopathy: A Multidisciplinary Approach*. Karger, Basel, pp 27–33.
 9. Orgiazzi J 2007 Pathogenesis. In: Wiersinga WM, Kahaly GJ (eds) *Graves' Orbitopathy: A Multidisciplinary Approach*. Karger, Basel, pp 41–56.
 10. Wiersinga WM 2007 Combined thyroid-eye clinics. In: Wiersinga WM, Kahaly GJ (eds) *Graves' Orbitopathy: A Multidisciplinary Approach*. Karger, Basel, pp 96–99.
 11. Bartalena L, Tanda ML, Piantanida E, Lai A, Pinchera A 2004 Relationship between management of hyperthyroidism and course of the ophthalmopathy. *J Endocrinol Invest* **27**:288–294.
 12. Wiersinga WM, Bartalena L 2002 Epidemiology and prevention of Graves' ophthalmopathy. *Thyroid* **12**:855–860.
 13. Bartalena L, Marcocci C, Pinchera A 2002 Graves' ophthalmopathy: a preventable disease? *Eur J Endocrinol* **146**:457–461.
 14. Hagg E, Asplund K 1987 Is endocrine ophthalmopathy related to smoking? *Br Med J* **295**:634–635.
 15. Bartalena L, Martino E, Marcocci C, Bogazzi F, Panicucci M, Velluzzi F, Loviselli A, Pinchera A 1989 More on smoking habits and Graves' ophthalmopathy. *J Endocrinol Invest* **12**:733–737.
 16. Shine B, Fells P, Edwards OM, Weetman AP 1990 Association between Graves' ophthalmopathy and smoking. *Lancet* **335**:1261–1264.
 17. Prummel MF, Wiersinga WM 1993 Smoking and risk of Graves' disease. *JAMA* **269**:479–482.
 18. Winsa B, Mandahl A, Karlsson FA 1993 Graves' disease, endocrine ophthalmopathy and smoking. *Acta Endocrinol (Copenh)* **128**:156–160.
 19. O'Hare JA, Georghegan M 1993 Cigarette smoking as a promoter of Graves' disease. *Eur J Intern Med* **4**:289–292.
 20. Nunery WR, Martin RT, Heinz GW, Gavin TJ 1993 The association of cigarette smoking with clinical subtypes of ophthalmic Graves' disease. *Ophthal Plast Reconstr Surgery* **9**:77–82.
 21. Pfeilschifter J, Ziegler R 1996 Smoking and endocrine ophthalmopathy: impact of smoking severity and current vs lifetime cigarette consumption. *Clin Endocrinol (Oxf)* **45**:477–481.
 22. Vestergaard P 2002 Smoking and thyroid disorders—a meta-analysis. *Eur J Endocrinol* **146**:153–161.
 23. Hegedus L, Brix TH, Vestergaard P 2004 Relationship between cigarette smoking and Graves' ophthalmopathy. *J Endocrinol Invest* **27**:265–271.
 24. Thornton J, Kelly SP, Harrison RA, Edwards R 2006 Cigarette smoking and thyroid eye disease: a systematic review. *Eye* **20**:1–11.
 25. Bartalena L, Marcocci C, Bogazzi F, Panicucci M, Lepri A, Pinchera A 1989 Use of corticosteroids to prevent progression of Graves' ophthalmopathy after radioiodine therapy for hyperthyroidism. *N Engl J Med* **321**:1349–1352.
 26. Tallstedt L, Lundell G, Terring O, Wallin G, Ljunggren J-G, Blomgren H, Taube A, the Thyroid Study Group 1992 *N Engl J Med* **326**:1733–1738.
 27. Bartalena L, Marcocci C, Bogazzi F, Manetti L, Tanda ML, Dell'Unto E, Bruno-Bossio G, Nardi M, Bartolomei MP, Lepri A, Rossi G, Martino E, Pinchera A 1998 Relation between therapy for hyperthyroidism and the course of Graves' ophthalmopathy *N Engl J Med* **338**:73–78.
 28. Bartalena L, Marcocci C, Tanda ML, Manetti L, Dell'Unto E, Bartolomei MP, Nardi M, Martino E, Pinchera A 1998 Cigarette smoking and treatment outcomes in Graves' ophthalmopathy. *Ann Intern Med* **129**:632–635.
 29. Eckstein A, Quadbeck B, Mueller G, Rettenmeier AW, Hoermann R, Mann K, Steuhl P, Esser J 2004 Impact of smoking on the response to treatment of thyroid associated ophthalmopathy. *Br J Ophthalmol* **87**:773–776.
 30. Prummel MF, Wiersinga WM, Mourits MP, Koornneef L, Berghout A, van der Gaag R 1989 Amelioration of eye changes of Graves' ophthalmopathy by achieving euthyroidism. *Acta Endocrinol (Copenh)* **121 (Suppl. 2)**: 185–189.
 31. Prummel MF, Wiersinga WM, Mourits MP, Koornneef L, Berghout A, van der Gaag R 1990 Effect of abnormal thyroid function on the severity of Graves' ophthalmopathy. *Arch Intern Med* **150**:1098–1101.
 32. Tallstedt L, Lundell G, Blomgren H, Bring J 1994 Does early administration of thyroxine reduce the development of Graves' ophthalmopathy after radioiodine therapy? *Eur J Endocrinol* **130**:494–497.
 33. Marcocci C, Bartalena L, Bogazzi F, Bruno-Bossio G, Pinchera A 1992 Relationship between Graves' ophthalmopathy and type of treatment of Graves' hyperthyroidism. *Thyroid* **2**:171–178.
 34. Marcocci C, Bruno-Bossio G, Manetti L, Tanda ML, Miccoli P, Iacconi P, Bartolomei MP, Nardi M, Pinchera A 1999 The course of Graves' ophthalmopathy is not influenced by near-total thyroidectomy: a case-control study. *Clin Endocrinol (Oxf)* **51**:503–506.
 35. Menconi F, Marinò M, Pinchera A, Rocchi R, Mazzi B, Nardi M, Bartalena L, Marcocci C 2007 Effects of total thyroid ablation *versus* near-total thyroidectomy alone on mild to moderate Graves' orbitopathy treated with intravenous glucocorticoids. *J Clin Endocrinol Metab* **92**:1653–1658.
 36. Jarhult J, Rudberg C, Larsson E, Selvander H, Sjovall K, Winsa B, Rastad J, Karlsson FA, TEO Study Group 2005 Graves' disease with moderate-severe endocrine ophthalmopathy—long term results of a prospective, randomized study of total or subtotal thyroid resection. *Thyroid* **15**:1157–1164.

37. Perros P, Kendall-Taylor P, Neoh C, Frewin S, Dickinson J 2005 A prospective study of the effects of radioiodine therapy for hyperthyroidism in patients with minimally active Graves' ophthalmopathy. *J Clin Endocrinol Metab* **90**:5321–5323.
38. Dederichs B, Dietlein M, Jenniches-Kloth B, Schmidt M, Theissen P, Moka D, Schicha H 2006 Radioiodine therapy of Graves' hyperthyroidism in patients without pre-existing ophthalmopathy: can glucocorticoids prevent the development of new ophthalmopathy? *Exp Clin Endocrinol Diab* **114**:366–370.
39. Eckstein AE, Plicht M, Lex H, Neuhauser M, Mann K, Lederbogen S, Heckmann C, Esser J, Morgenthaler NG 2006 Thyrotropin receptor autoantibodies are independent risk factors for Graves' ophthalmopathy and help to predict severity and outcome of the disease. *J Clin Endocrinol Metab* **91**:3464–3470.
40. Bartalena L 2005 Glucocorticoids for Graves' ophthalmopathy: how and when. *J Clin Endocrinol Metab* **90**:5497–5499.
41. Uddin JM, Davies PD 2002 Treatment of upper eyelid retraction associated with thyroid eye disease with subconjunctival botulinum toxin injection. *Ophthalmology* **109**:1183–1187.
42. Terwee CB, Gerding MN, Dekker FW, Prummel MF, Wiersinga WM 1998 Development of a disease-specific quality of life questionnaire for patients with Graves' ophthalmopathy. *Br J Ophthalmol* **82**:773–779.
43. Mourits MP, Koornneef L, Wiersinga WM, Prummel MF, Berghout A, van der Gaag R 1989 Clinical criteria for the assessment of disease activity in Graves' ophthalmopathy: a novel approach. *Br J Ophthalmol* **73**:639–644.
44. Mourits MP, Prummel MF, Wiersinga WM, Koornneef L 1997 Clinical activity score as a guide in the management of patients with Graves' ophthalmopathy. *Clin Endocrinol (Oxf)* **47**:9–14.
45. Dickinson AJ, Perros P 2001 Controversies in the clinical evaluation of active thyroid-associated orbitopathy: use of detailed protocol with comparative photographs for objective assessment. *Clin Endocrinol (Oxf)* **55**:283–303.
46. Rose GE 2006 Postural visual obscurations in patients with inactive thyroid eye disease; a variant of "hydraulic" disease. *Eye* **20**:1178–1185.
47. Marcocci C, Bartalena L, Tanda ML, Manetti L, Dell'Unto E, Rocchi E, Barbesino G, Mazzi B, Bartolomei MP, Lepri P, Cartei F, Nardi M, Pinchera A 2001 Comparison of the effectiveness and tolerability of intravenous or oral glucocorticoids associated with orbital radiotherapy in the management of severe Graves' ophthalmopathy: results of a prospective, single-blind, randomized study. *J Clin Endocrinol Metab* **86**:3562–3567.
48. Macchia PE, Bagattini M, Lupoli G, Vitale M, Vitale G, Fenzi G 2001 High-dose intravenous corticosteroid therapy for Graves' ophthalmopathy. *J Endocrinol Invest* **24**:152–58.
49. Kauppinen-Makelin R, Karmi A, Leinonen E, Loyttyniemi E, Salonen O, Sane T, Setälä K, Viikari J, Heufelder A, Valimäki M 2002 High dose intravenous methylprednisolone pulse therapy versus oral prednisone for thyroid-associated ophthalmopathy. *Acta Ophthalmol Scand* **80**:316–321.
50. Kahaly GJ, Pitz S, Hommel G, Dittmar M 2005 Randomized, single-blind trial of intravenous *versus* oral steroid monotherapy in Graves' orbitopathy. *J Clin Endocrinol Metab* **90**:5234–5240.
51. Ng CM, Yuen HKL, Choi KL, Chan MK, Yuen KT, Ng YW, Tiu SC 2005 Combined orbital irradiation and systemic steroids compared with systemic steroids alone in the management of moderate-to-severe Graves' ophthalmopathy: a preliminary study. *Hong Kong Med J* **11**:322–330.
52. Hart Frantzco RH, Kendall-Taylor P, Crombie A, Perros P 2005 Early response to intravenous glucocorticoids for severe thyroid-associated ophthalmopathy predicts treatment outcome. *J Ocular Pharmacol Therap* **21**:328–336.
53. Soares-Welch CV, Fatourechi V, Bartley GB, Beatty CW, Gorman CA, Bahn RS, Bergstrahl EJ, Schleck CD, Garrity JA 2003 Optic neuropathy of Graves disease: results of transantral orbital decompression and long-term follow-up in 215 patients. *Am J Ophthalmol* **136**:433–441.
54. Wakelkamp IM, Baldeschi L, Saeed P, Mourits MP, Prummel MF, Wiersinga WM 2005 Surgical or medical decompression as a first-line treatment in Graves' ophthalmopathy? A randomized controlled trial. *Clin Endocrinol (Oxf)* **63**:323–328.
55. Akamizu T, Kaneko H, Noguchi N, Kashii S, Nakao K 2000 Moisture chamber for management of corneal ulcer due to Graves' ophthalmopathy. *Thyroid* **10**:1123–1124.
56. Heinz C, Eckstein A, Steuhl HP, Meller D 2004 Amniotic membrane transplantation for reconstruction of corneal ulcer in Graves' ophthalmopathy. *Cornea* **23**:524–526.
57. Bartalena L, Marcocci C, Chiovato L, Laddaga M, Lepri A, Andreani D, Cavallacci G, Baschieri L, Pinchera A 1983 Orbital cobalt irradiation combined with systemic corticosteroids for Graves' ophthalmopathy: comparison with systemic corticosteroids alone. *J Clin Endocrinol Metab* **56**:1139–1144.
58. Kahaly G, Schrezenmeier J, Krause U, Schwikert B, Meuer S, Müller W, Dennebaum R, Beyer J 1986 Cyclosporin and prednisone vs. prednisone in treatment of Graves' ophthalmopathy: a controlled, randomized and prospective study. *Eur J Clin Invest* **16**:415–422.
59. Prummel MF, Mourits MP, Berghout A, Krenning EP, van der Gaag R, Koornneef L, Wiersinga WM 1989 Prednisone and cyclosporine in the treatment of severe Graves' ophthalmopathy. *N Engl J Med* **321**:1353–1359.
60. Prummel MF, Mourits MP, Blank L, Berghout L, Koornneef L, Wiersinga WM 1993 Randomised double-blind trial of prednisone versus radiotherapy in Graves' ophthalmopathy. *Lancet* **342**:949–954.
61. Kung AW, Michon J, Tai KS, Chan FL 1996 The effect of somatostatin versus corticosteroids in the treatment of Graves' ophthalmopathy. *Thyroid* **6**:381–384.
62. Kahaly GJ, Pitz S, Müller-Forell W, Hommel G 1996 Randomized trial of intravenous immunoglobulins versus prednisolone in Graves' ophthalmopathy. *Clin Exp Immunol* **106**:197–202.
63. Anonymous 2001 Recommendations for the prevention and treatment of glucocorticoid-induced osteoporosis: 2001 update. American College of Rheumatology Ad Hoc Committee on glucocorticoid-induced osteoporosis. *Arthr Rheumatol* **44**:1496–1503.
64. Compston J on behalf of Guidelines Writing Group 2002 Glucocorticoid-Induced Osteoporosis Guidelines for Prevention and Treatment. Royal College of Physicians of London, UK.
65. Marcocci C, Bartalena L, Panicucci M, Marconcini C, Cartei F, Cavallacci G, Laddaga M, Campobasso G, Baschieri L, Pinchera A 1987 Orbital cobalt irradiation combined with retrobulbar or systemic corticosteroids for Graves' oph-

- thalmopathy: a comparative study. *Clin Endocrinol (Oxf)* **27**:33–42.
66. Wiersinga WM, Prummel MF 2002 Graves' ophthalmopathy: a rational approach to treatment. *Trends Endocrinol Metab* **13**:280–287.
 67. Weissel M, Hauff W 2000 Fatal liver failure after high-dose glucocorticoid pulse therapy in a patient with severe eye disease. *Thyroid* **10**:521.
 68. Marinò M, Morabito E, Brunetto MR, Bartalena L, Pinchera A, Marcocci C 2000 Acute and severe liver damage associated with intravenous glucocorticoid pulse therapy in patients with Graves' ophthalmopathy. *Thyroid* **14**:403–406.
 69. Le Moli R, Baldeschi L, Saeed P, Regensburg N, Mourits MP, Wiersinga WM 2007 Determinants of liver damage associated with intravenous methylprednisolone pulse therapy in Graves' ophthalmopathy. *Thyroid* **17**:357–362.
 70. Bartalena L, Marcocci C, Tanda ML, Rocchi R, Mazzi B, Barbesino G, Pinchera A 2002 Orbital radiotherapy for Graves' ophthalmopathy. *Thyroid* **12**:245–250.
 71. Kahaly GJ, Rosler HP, Pitz S, Hommel G 2000 Low- versus high-dose radiotherapy for Graves' ophthalmopathy: a randomized, single blind trial. *J Clin Endocrinol Metab* **85**:102–108.
 72. Nakahara H, Noguchi S, Murakami N, Morita M, Tamaru M, Ohnishi T, Hoshi H, Jinnouchi S, Nagamadu S, Futami S 1995 Graves' ophthalmopathy: MR evaluation of 10 Gy vs. 24 Gy irradiation combined with systemic corticosteroids. *Radiology* **196**:857–862.
 73. Mourits MP, van Kempen-Hartevelde ML, Garcia MB, Koppeschaar HP, Tick L, Terwee CB 2000 Radiotherapy for Graves' orbitopathy: randomised placebo-controlled study. *Lancet* **355**:1505–1509.
 74. Prummel MF, Terwee CB, Gerding MN, Baldeschi L, Mourits MP, Blank L, Dekker FW, Wiersinga WM 2004 A randomized controlled trial of orbital radiotherapy versus sham irradiation in patients with mild Graves' ophthalmopathy. *J Clin Endocrinol Metab* **89**:15–20.
 75. Gorman CA, Garrity JA, Fatourehchi V, Bahn RS, Petersen IA, Stafford SL, Earle JD, Forbes GS, Kline RW, Bergstrahl EJ, Offord KP, Rademacher DM, Stanley NM, Bartley GB 2001 A prospective, randomized, double-blind, placebo-controlled study of orbital radiotherapy for Graves' orbitopathy. *Ophthalmology* **108**:1523–1534.
 76. Marquez SD, Lum BL, McDougall IR, Katkuri S, Levin PS, MacManus PS, Donaldson SS 2001 Long-term results of irradiation for patients with Graves' ophthalmopathy. *Int J Rad Oncol Biol Phys* **51**:766–774.
 77. Marcocci C, Bartalena L, Rocchi R, Marinò M, Menconi F, Morabito E, Mazzi B, Mazzeo S, Sartini MS, Nardi M, Cartei F, Cionini L, Pinchera A 2003 Long-term safety of orbital radiotherapy for Graves' ophthalmopathy. *J Clin Endocrinol Metab* **88**:3561–3566.
 78. Wakelkamp IM, Tan H, Saeed P, Schlingemann RO, Verbraak FD, Blank LE, Prummel MF, Wiersinga WM 2004 Orbital irradiation for Graves' ophthalmopathy: is it safe? A long-term follow-up study. *Ophthalmology* **111**:1557–1562.
 79. Robertson DM, Buettner H, Gorman CA, Garrity JA, Fatourehchi V, Bahn RS, Petersen IA, Stafford SL, Earle JD, Forbes GS, Kline RW, Bergstrahl EJ, Offord KP, Rademacher DM, Stanley NM, Bartley GB 2003 Retinal microvascular abnormalities in patients treated with external radiation for Graves ophthalmopathy. *Arch Ophthalmol* **121**:652–657.
 80. Wiersinga WM 2007 Management of Graves' ophthalmopathy. *Nature Clin Pract Endocrinol Metab* **3**:396–404.
 81. Viebahn M, Marricks ME, Osterloh MD 1991 Synergism between diabetic and radiation retinopathy: case report and review. *Br J Ophthalmol* **75**:29–32.
 82. Marcocci C, Bartalena L, Bogazzi F, Bruno-Bossio G, Lepri A, Pinchera A 1991 Orbital radiotherapy combined with high-dose systemic glucocorticoids for Graves' ophthalmopathy is more effective than orbital radiotherapy alone: results of a prospective study. *J Endocrinol Invest* **14**:853–860.
 83. Dickinson AJ, Vaidya B, Miller M, Coulthard A, Perros P, Baister E, Andrews CD, Hesse L, Heverhagen JT, Heufelder AE, Kendall-Taylor P 2004 Double-blind, placebo-controlled trial of octreotide long-acting repeatable (LAR) in thyroid-associated ophthalmopathy. *J Clin Endocrinol Metab* **89**:5910–5915.
 84. Wemeau JL, Caron P, Beckers A, Rohmer V, Orgiazzi J, Borson-Chazot F, Nocaudie M, Perimemis P, Bisot-Locard S, Bourdeix J, Dejager S 2005 Octreotide (long-acting release formulation) treatment in patients with Graves' orbitopathy: clinical results of a four-month, randomized, placebo-controlled, double-blind study. *J Clin Endocrinol Metab* **90**:841–848.
 85. Stan MN, Garrity JA, Bradley EA, Woog JJ, Bahn MM, Brennan MD, Bryant SC, Achenbach SJ, Bahn RS 2006 Randomized, double-blind, placebo-controlled trial of long-acting release octreotide for treatment of Graves' ophthalmopathy. *J Clin Endocrinol Metab* **91**:4817–4824.
 86. Chang T-C, Liao SL 2006 Slow-release lanreotide in Graves' ophthalmopathy: a double-blind randomized, placebo-controlled clinical trial. *J Endocrinol Invest* **29**:413–422.
 87. Perros P, Weightman DR, Crombie AL, Kendall-Taylor P 1990 Azathioprine in the treatment of thyroid-associated ophthalmopathy. *Acta Endocrinol (Copenh)* **122**:8–12.
 88. Kahaly G, Lieb W, Muller-Forell W, Mainberger M, Beyer J, Vollmar J, Staiger C 1990 Ciamezone in endocrine orbitopathy. A randomized, double-blind, placebo-controlled study. *Acta Endocrinol (Copenh)* **122**:13–21.
 89. Antonelli A, Saracino A, Alberti B, Canapicchi R, Cartei F, Lepri A, Laddaga M, Baschieri L 1992 High-dose intravenous immunoglobulin treatment in Graves' ophthalmopathy. *Acta Endocrinol (Copenh)* **126**:13–23.
 90. Salvi M, Vannucchi G, Campi I, Currò N, Dazzi D, Simonetta S, Bonara P, Rossi S, Sina C, Guastella C, Ratiglia R, Beck-Peccoz P 2007 Treatment of Graves' disease and associated ophthalmopathy with the anti-CD20 monoclonal antibody rituximab: an open study. *Eur J Endocrinol* **156**:33–40.
 91. Paridaens D, van den Bosch WA, van der Loos TL, Krenning EP, van Hagen PM 2005 The effect of etanercept on Graves' ophthalmopathy: a pilot study. *Eye* **19**:1286–1289.
 92. Mourits P, Koornneef L, van Mourik-Noordenbos AM, van der Meulen-Schott HM, Prummel MF, Wiersinga WM, Berghout A 1990 Extraocular muscle surgery for Graves' ophthalmopathy: does prior treatment influence surgical outcome? *Br J Ophthalmol* **74**:481–483.
 93. Baldeschi L, MacAndie K, Koetsier E, Blank L, Wiersinga WM 2008 The influence of previous orbital irradiation on the outcome of rehabilitative decompression surgery in Graves' ophthalmopathy. *Am J Ophthalmol*, in press.

94. Baldeschi L 2007 Decompression surgery for thyroid-related orbitopathy: state of the art and unresolved issues. In: Guthoff R, Katovitz J (eds) *Essentials in Ophthalmology: Orbit and Oculoplastic*, 9th ed. Springer, Berlin, pp 143–154.
95. Goldberg RA, Christenbury JD, Shorr N 1988 Medial entropion following orbital decompression for dysthyroid ophthalmopathy. *Ophthal Plast Reconstr Surgery* **4**: 81–85.
96. Rose GE, Lund VJ 2003 Clinical features and treatment of late enophthalmos after orbital decompression: a condition suggesting cause for idiopathic “implosion antrum” (silent sinus syndrome). *Ophthalmology* **110**:819–826.
97. McCormick CD, Bearden WH, Hunts JH, Anderson RL 2004 Cerebral vasospasm and ischemia after orbital decompression for Graves ophthalmopathy. *Ophthal Plast Reconstr Surgery* **20**:347–351.
98. Carrasco JR, Castillo I, Bolyk R, Probitkin EA, Savino PJ 2005 Incidence of infraorbital hypesthesia and sinusitis after orbital decompression for thyroid-related orbitopathy: a comparison of surgical techniques. *Ophthal Plast Reconstr Surgery* **21**:188–191.
99. Baldeschi L, Lupetti A, Vu P, Wakelkamp IM, Prummel MF, Wiersinga WM 2007 Reactivation of Graves’ orbitopathy after rehabilitative orbital decompression. *Ophthalmology* **114**:1395–1402.
100. Baldeschi L, Wakelkamp IM, Lindeboom R, Prummel MF, Wiersinga WM 2006 Early versus late orbital decompression in Graves’ orbitopathy: a retrospective study in 125 patients. *Ophthalmology* **113**:874–878.
101. Baldeschi L, MacAndie K, Hintschich C, Wakelkamp IM, Prummel MF, Wiersinga WM 2005 The removal of the deep lateral wall in orbital decompression: its contribution to exophthalmos reduction and influence on consecutive diplopia. *Am J Ophthalmol* **140**:642–647.
102. Wiersinga WM, Prummel MF, Terwee CB 2004 Effects of Graves’ ophthalmopathy on quality of life. *J Endocrinol Invest* **27**:259–264.
103. Kahaly GJ, Petrak F, Hardt J, Pitz S, Egle UT 2005 Psychosocial morbidity of Graves’ orbitopathy. *Clin Endocrinol (Oxf)* **63**:395–402.
104. Wiersinga WM 2004 Thyroid associated ophthalmopathy: pediatric and endocrine aspects. *Ped Endocr Rev* **1(suppl 3)**:513–517.
105. Krassas GE, Gogakos A 2006 Thyroid-associated ophthalmopathy in juvenile Graves’ disease—clinical, endocrine and therapeutic aspects. *J Pediatr Endocrinol Metab* **19**: 1193–1206.
106. Krassas GE, Segni M, Wiersinga WM 2005 Childhood Graves’ ophthalmopathy: results of a European questionnaire study. *Eur J Endocrinol* **153**:515–520.
107. Krassas GE, Wiersinga WM 2006 Smoking and autoimmune thyroid disease: the plot thickens. *Eur J Endocrinol* **154**:777–780.
108. Krassas GE, Perros P 2007 Prevention of thyroid-associated ophthalmopathy in children and adults: current views and management of preventable risk factors. *Pediatr Endocr Rev* **4**:218–224.
109. Krassas GE 2001 Thyroid eye disease in children and adolescents: new therapeutic approaches. *J Pediatr Endocrinol Metab* **14**:97–100.

Address reprint requests to:
Professor Luigi Bartalena
Department of Clinical Medicine
University of Insubria
Varese
Italy

E-mail: l.bartalena@libero.it or luigi.bartalena@uninsubria.it