

# PERSPECTIVE

## The White Dot Syndromes

DAVID A. QUILLEN, MD, JANET B. DAVIS, MD, JUSTIN L. GOTTLIEB, MD,  
BARBARA A. BLODI, MD, DAVID G. CALLANAN, MD, TOM S. CHANG, MD, AND  
ROBERT A. EQUI, MD

• **PURPOSE:** To review the distinctive and shared features of the white dot syndromes, highlighting the clinical findings, diagnostic test results, proposed etiologies, treatments, and prognosis.

• **DESIGN:** Review.

• **METHODS:** Review of the literature.

• **RESULTS:** Common white dot syndromes are reviewed, including acute posterior multifocal placoid pigment epitheliopathy, birdshot chorioretinopathy, diffuse unilateral subacute neuroretinitis, multiple evanescent white dot syndrome, multifocal choroiditis with panuveitis, serpiginous choroiditis, and acute zonal occult outer retinopathy.

• **CONCLUSIONS:** The white dot syndromes are a group of disorders characterized by multiple whitish-yellow inflammatory lesions located at the level of the outer retina, retinal pigment epithelium, and choroid. For clinicians and researchers alike, they present significant diagnostic and therapeutic challenges. (*Am J Ophthalmol* 2004;137:538–550. © 2004 by Elsevier Inc. All rights reserved.)

**T**HE WHITE DOT SYNDROMES ARE A GROUP OF DISORDERS characterized by multiple whitish-yellow inflammatory lesions located at the level of the outer retina, retinal pigment epithelium, and choroid. The white dot syndromes include: acute posterior multifocal placoid pigment epitheliopathy (APMPPE), birdshot chorioretinopathy, diffuse unilateral subacute neuroretinitis (DUSN), multiple evanescent white dot syndrome (MEWDS), multifocal choroiditis with panuveitis (MFC), and serpiginous choroiditis.<sup>1</sup> Other entities, such as acute

zonal occult outer retinopathy (AZOOR), punctate inner choroiditis (PIC), acute macular neuroretinopathy (AMN), sarcoidosis, histoplasmosis, pneumocystis chorioidopathy, Behcets disease, toxoplasmosis, sympathetic ophthalmia, syphilis, and intraocular lymphoma may be considered in the differential diagnosis of the white dot syndromes.

The white dot syndromes have many distinctive and shared clinical features (Table 1). The majority of individuals are less than 50 years of age with the exception of birdshot chorioretinopathy and serpiginous choroiditis which may affect middle-aged and older adults. MEWDS, birdshot chorioretinopathy, and MFC are more commonly observed in women. The white dot syndromes may be unilateral (DUSN, MEWDS) or bilateral (APMPPE, birdshot chorioretinopathy, MFC, serpiginous choroiditis). Symptoms associated with the white dot syndromes include blurred vision, visual field loss (blind spot enlargement), photopsias, nyctalopia, and floaters. Vitritis is usually mild except in cases of birdshot chorioretinopathy and MFC. The white dots may be subtle or prominent depending on the condition. For example, MEWDS is characterized by faint white dots located in the midperipheral or posterior fundus, whereas MFC is notable for more prominent inflammatory lesions. The white dot lesions may be discreet (MEWDS, multifocal choroiditis, birdshot chorioretinopathy, DUSN) or more placoid in appearance (APMPPE and serpiginous choroiditis).

The etiology of the white dot syndromes is not completely understood. Various mechanisms of disease have been proposed including infectious and noninfectious causes. Despite their distinct presentations, several of the white dot syndromes share common clinical features. The association of MFC, MEWDS, AMN, and AZOOR has been referred to as the AZOOR complex of disorders.<sup>2</sup> Each of the AZOOR complex of disorders shares the following features: female predominance, development of one or more zones of unexplained visual field loss usually contiguous with the blind spot, photopsias, and reduced electroretinographic amplitudes.<sup>2</sup> Controversy exists as to whether or not these conditions represent a spectrum of a

Biosketches and/or additional material at [www.ajo.com](http://www.ajo.com)

Accepted for publication Dec 31, 2003.

From the Penn State College of Medicine, Hershey, Pennsylvania (D.A.Q.); Bascom Palmer Eye Institute, University of Miami, Miami, Florida (J.B.D.); University of Wisconsin-Madison, Madison, Wisconsin (J.L.G., B.A.B.); University of Texas, Southwestern, Texas (D.G.C.); and Doheny Eye Institute, University of Southern California, Los Angeles, California (T.S.C., R.A.E.).

Inquiries to David A. Quillen, MD, Penn State Department of Ophthalmology, 500 University Drive, Hershey, PA 17033; fax: (717) 531-5475; e-mail: [daq2@psu.edu](mailto:daq2@psu.edu)

**TABLE 1. White Dot Syndromes**

	APMPPE	Birdshot Chorioretinopathy	DUSN
Age	young (20s–50s)	middle-age (40s–60s)	variable, may affect children
Sex	men = women	women > men	men = women
Laterality	bilateral	bilateral	unilateral
Viral Illness	+/-	-	-
Onset	abrupt	insidious	variable
Duration	weeks-months recurrence rare	chronic, recurrent	months-years acute lesions: weeks-months
Symptoms	blurred vision, scotomas, photopsias	blurred vision, floaters, difficulty with night vision +/- or color vision, photopsias	severe loss of vision following apparent subacute visual loss
Vitreous Cells	mild	moderate	mild
Findings	multifocal, flat, gray-white placoid lesions at level of RPE in the posterior pole which fade rapidly in 7–12 days; may have mild disk swelling	multiple, ill-defined cream- colored lesions at level of outer retina/RPE, patches of depigmentation, vascular leakage, CME; +/- disk swelling, optic atrophy	early: +/- APD, disk edema, clusters of yellow-white spots at outer retina/RPE (in vicinity of worm) late: APD, optic atrophy, RPE derangement, vessel attenuation
Fluorescein	acute: block early, stain late late: window defects	normal; may have vascular leakage, CME	acute: nonfluorescent early, stain late; +/- disk staining
ERG/EOG	+/- abnormal EOG	abnormal rod and cone ERG	mod to severe reduction of ERG (unilateral)
Sequelae	RPE mottling/depigmentation	CME, rare CNV	optic atrophy, vessel attenuation, RPE atrophy
HLA	HLA-B7, HLA-DR2	HLA - A29 (strong)	-----
Other	may have CNS vasculitis	+/- hearing loss, vitiligo	-----
Treatment	observation; consider corticosteroids for CNS disease	corticosteroids cyclosporine	direct photocoagulation of worm; ? antihelminthic meds
Prognosis	good	guarded	poor (unless worm destroyed)
Etiology	? viral	? autoimmune	nematodes: ? Baylisascaris, ? Ancylostoma

single or closely related group of diseases or distinct entities.<sup>3,4</sup>

This article reviews the common inflammatory white dot syndromes and highlights recent developments and controversies regarding this distinctive group of disorders.

• **ACUTE POSTERIOR MULTIFOCAL PLACOID PIGMENT EPITHELIOPATHY:** APMPE affects healthy men and women between the ages of 20 and 50 years. Symptoms of APMPE include a rapid onset of blurred vision associated with central and paracentral scotomas. Visual loss is usually bilateral but may be asymmetric. The second eye usually becomes involved within a few days but the onset may be delayed for several weeks. Individuals may complain of photopsias, a symptom reported by persons with several other inflammatory white dot disorders as well. Approximately one third of individuals report an antecedent viral illness.<sup>5</sup>

Mild vitreous cells usually are present. The ophthalmoscopic examination is characterized by bilateral, multifocal

yellowish-white placoid lesions, usually less than 1 disk diameter in size, and located primarily in the posterior pole (Figure 1) at the level of the retinal pigment epithelium (retinal pigment epithelium). The lesions fade gradually over the course of 1 to 2 weeks. New lesions may be observed in the peripheral fundus for up to 3 weeks after the onset of symptoms and tend to be more linear and radially oriented. The acute lesions are replaced by varying degrees of retinal pigment epithelium atrophy and hyperpigmentation. Atypical findings include papillitis, periphlebitis, central retinal vein occlusion, disk neovascularization, exudative neurosensory retinal detachment, and subhyaloid hemorrhage.<sup>6–10</sup>

Intravenous fluorescein angiography (IVFA) reveals a characteristic “block early, stain late” pattern. In the early phase of the angiogram, the acute lesions are hypofluorescent. The hypofluorescence is probably related to both the gray-white opacification of the retinal pigment epithelium and choroidal nonperfusion. The lesions become hyperfluorescent in the late phase of the study. Prolonged filling of the choroid may also be seen. In the quiescent stage of

TABLE 1. Continued

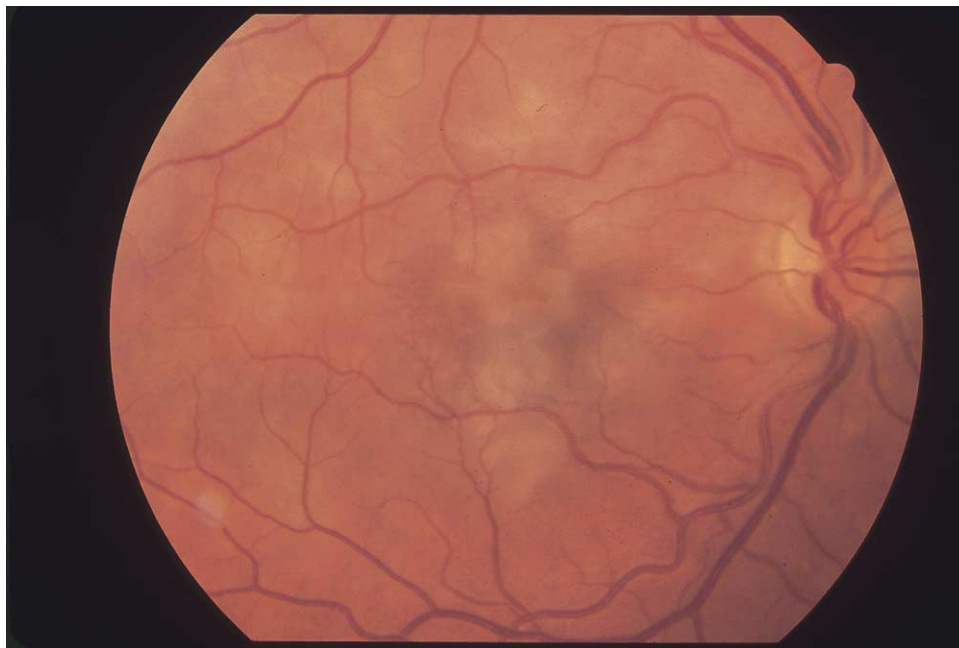MEWDS	Multifocal Choroiditis with Panuveitis	Serpiginous Choroiditis
young (20s–40s)	young; may affect children	young, middle-age (30s–60s)
women > men	women > men	men > women
unilateral	bilateral	bilateral but delayed / asymmetric
+/-	+/-	-
abrupt	insidious	variable
weeks-months	chronic, recurrent	chronic, recurrent acute lesions weeks-months
recurrence rare		
blurred vision, scotomas, photopsias	blurred vision, floaters, scotomas, photopsias	blurred vision paracentral or central scotomas
mild	moderate	mild
myopia, +/- APD, small white dots at level of outer retina/RPE, may coalesce to form patches, white/orange granularity to fovea; +/- disk edema, blind spot enlargement	myopia, anterior uveitis (50%), active yellow-gray choroidal lesions replaced by punched-out scars; +/- disk swelling, CME may present with CNV	geographic zone of gray-white diskoloration of RPE in peripapillary/macula area, centripetal extension with active peripheral edge and RPE and choriocapillaris atrophy in wake
early hyperfluorescence, late staining; "wreath-like" pattern	acute: block early, stain late late: window defects	hypofluorescent early, borders stain late
abnormal ERG	normal-subnormal ERG	normal
very mild RPE alterations	punched out scars; CNV	RPE mottling, scarring, loss of choriocapillaris, CNV
-----	-----	HLA-B7
-----	-----	-----
observation	corticosteroids; photocoagulation, PDT for CNV	immunosuppression, ? antiviral medications; photocoagulation for CNV
very good	generally poor	guarded
? viral	? viral	? autoimmune, ? infectious (? herpes virus family)

APMPPE, varying degrees of hypo- and hyperfluorescence are revealed by IVFA, depending on the extent of the retinal pigment epithelium derangement. Indocyanine green angiography (ICG) reveals hypofluorescence of the active and healed lesions, highlighting the role of choroidal nonperfusion in APMPPE. Electrophysiologic testing may demonstrate an abnormal electrooculogram (EOG).

The etiology of APMPPE is not well understood. An abnormal immune response to an inciting agent—possibly viral—has been postulated since some patients report an antecedent prodromal illness characterized by flu-like symptoms. The early hypofluorescence of the acute lesions demonstrated by IVFA and ICG suggest that nonperfusion or infarction of the choroid, perhaps secondary to vasculitis, may be the primary disorder. Associations with systemic vasculitides support this hypothesis. The variations in clinical appearance and presentation may be related to the extent of choroidal ischemia and nonperfusion. APMPPE has been described in association with mumps, sarcoidosis, Wegener's granulomatosis, polyarteri-

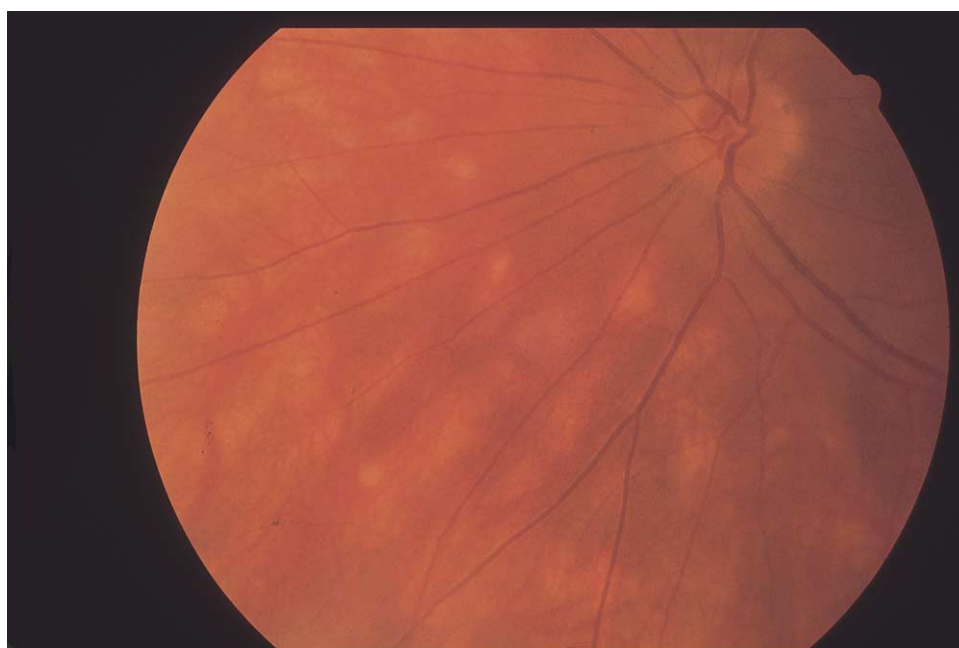tis nodosa, ulcerative colitis, group A streptococcal infection, tuberculosis, following hepatitis B vaccination, and Lyme disease; however, the nature of these associations are unclear. Associations with HLA-B7 and HLA-DR2 also have been reported. A hypersensitivity reaction to antimicrobial agents has been postulated as an etiologic factor in some cases of recurrent disease.<sup>11–20</sup>

In general, no treatment is required for APMPPE. Most individuals have a good visual prognosis, with spontaneous recovery of visual acuity to 20/40 or better within 3 to 6 weeks. Recurrences are rare. Long-term loss of vision may be related to extensive retinal pigment epithelium changes, choroidal neovascularization (rare), or the atypical features described herein. Features that may be associated with poor visual prognosis include foveal involvement at initial presentation, older age at presentation (>60 years), unilateral disease, longer interval between first and second eye involvement (>6 months), and recurrent disease.<sup>21</sup> Systemic corticosteroid treatment has been suggested in cases with foveal involvement and



**FIGURE 1.** Acute posterior multifocal placoid pigment epitheliopathy (APMPPE) is characterized by the sudden onset of multifocal yellowish-white placoid lesions located at the level of the retinal pigment epithelium. APMPPE is usually bilateral and symmetric.

---



**FIGURE 2.** Birdshot chorioretinopathy is characterized by radiating cream-colored, oval spots located at the level of the retinal pigment epithelium. The lesions are most notable in the posterior fundus nasal to the optic disk.

---

associated central nervous system (CNS) vasculitis. Although extremely rare, there are reports of death associated with CNS vasculitis that developed within several weeks after the onset of APMPPE.<sup>22</sup> No systemic investigation is necessary for typical APMPPE, although a thorough sys-

temic review of systems is essential in all patients. Neuroimaging, usually with magnetic resonance imaging (MRI), is indicated in individuals with evidence of CNS vasculitis, including severe headache or other neurologic signs or symptoms.

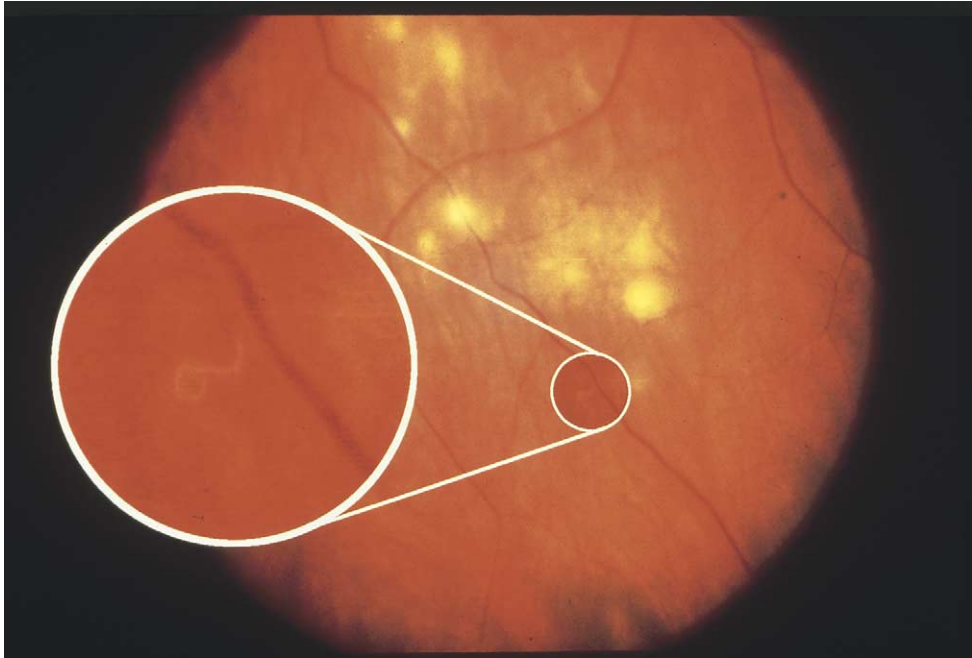


FIGURE 3. Diffuse unilateral subacute neuroretinitis (DUSN) is caused by a mobile nematode located in the subretinal space. Clusters of small white dots may be visible in the vicinity of the nematode (photograph courtesy of Ditte Hess, CRA and Rick Stratton).

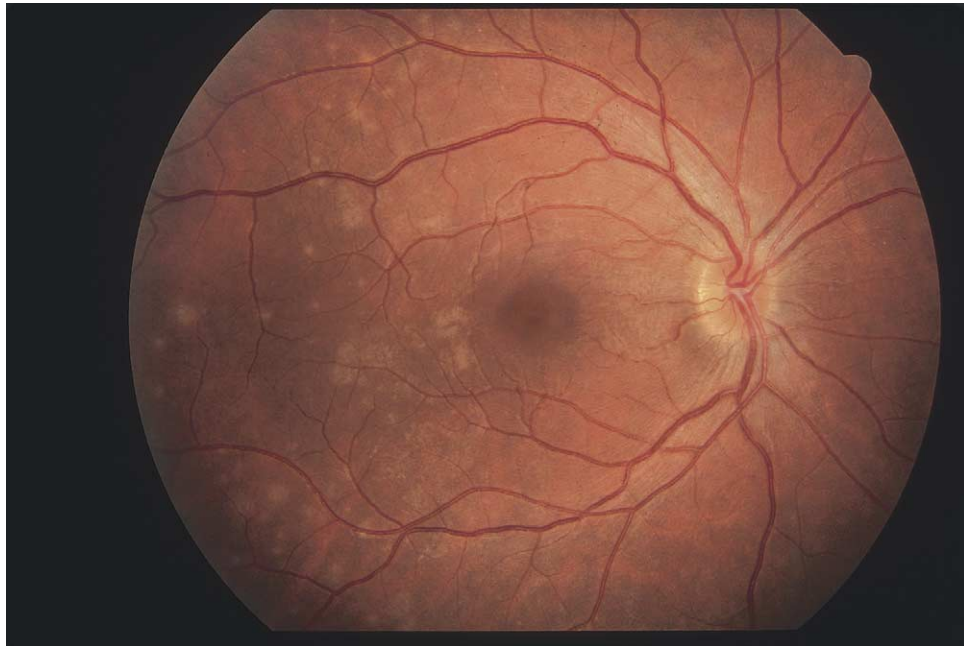
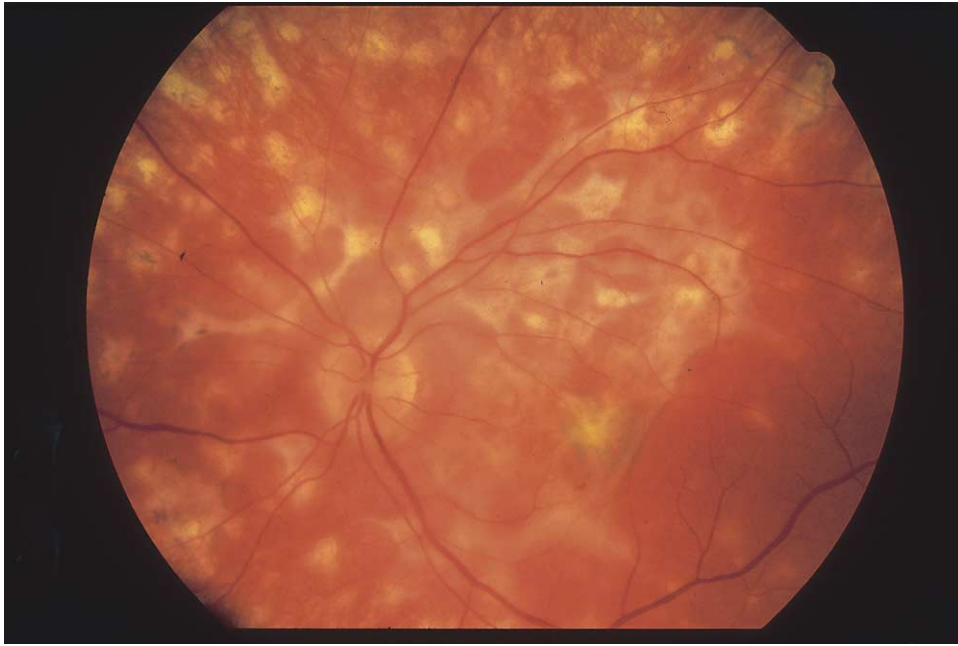
FIGURE 4. Multiple evanescent white dot syndrome (MEWDS) is characterized by the presence of subtle white lesions located in the posterior fundus, occasionally assuming a “wreath-like” pattern. Optic disk edema is common.

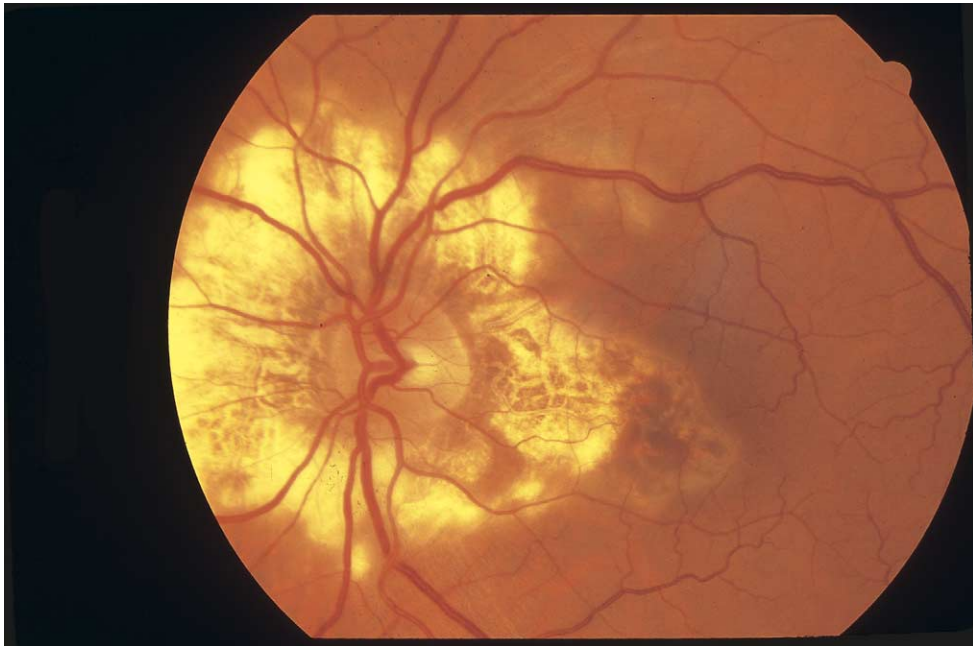• **BIRDSHOT CHORIORETINOPATHY** Gass and Maumenee published nearly simultaneously descriptions of a new, distinctive, posterior uveitis with radiating, deep, choroidal lesions.<sup>23,24</sup> What appeared to Gass to be a depigmentation similar to that seen in vitiligo of the skin resembled

the scatter of a shotgun blast to Maumenee. The vitiliginous chorioretinitis of Gass therefore emphasized the appearance of the lesions and the birdshot retinochoroidopathy of Ryan and Maumenee emphasized the pattern. The disease demonstrates both characteristics



**FIGURE 5.** Multifocal choroiditis with panuveitis (MFC) manifests with multiple inflammatory lesions located at the level of the retinal pigment epithelium and choroid. Vision loss usually is related to the development of choroidal neovascularization.

---



**FIGURE 6.** Serpiginous choroiditis is characterized by the presence of active and inactive lesions in the posterior fundus (usually in a peripapillary distribution). Acute lesions are slightly ill-defined, gray-white, jigsaw puzzle-shaped areas located adjacent to atrophic scars.

---

remarkably well and the characteristic fundus appearance is a key feature in diagnosis. Birdshot chorioretinopathy is probably the preferred term currently, although Gass's atlas still indexes the disease as vitiliginous chorioretinitis.<sup>25</sup>

Patients with birdshot chorioretinopathy often present with complaints of poor vision out of proportion to the loss of visual acuity. Since intraocular inflammation can be very mild and the spots are not always prominent in the early stages, the symptoms may be dismissed, leading to a



delay in diagnosis. Decreased night vision and paracentral scotomas, if articulated well by the patient, usually lead to thorough evaluation and diagnosis. Other common symptoms include floaters, photopsias, and problems with color vision.<sup>25</sup> Severe symptoms may persist even after treatment and resolution of the active inflammation. Conversely, just as some patients may detect the disease much earlier than their doctors, others seem to have no or minimal complaints until the disease is advanced with very prominent spots and post-inflammatory changes in the retinal vessels, optic nerve and macula. Reliance solely on patient symptoms to accurately predict the activity or stage of disease is therefore risky.

Anterior segment inflammation is generally minimal or absent.<sup>26</sup> Posterior synechiae do not occur. Vitritis is moderate and present in all cases.<sup>23</sup> Focal vitreous opacities or a pronounced vitreous haze are atypical. The yellow-orange lesions with indistinct borders that appear to radiate from the optic nerve head are the most reliable diagnostic features (Figure 2). The spots are seen mainly in the nasal retina and are symmetrically distributed in the two eyes.<sup>23</sup> Retinal vasculitis is an important component of the disorder.<sup>27</sup> Involvement of the large and small vessels in the posterior fundus is typical, especially in the earlier stages of disease. Retinal hemorrhaging or exudation is rare and most of the retinal vascular change is limited to arteriolar and venular narrowing. Macular edema and progressive optic nerve pallor often indistinguishable from glaucoma are characteristic of chronic disease.

IVFA provides important diagnostic and prognostic information. IVFA may detect active retinovascular leakage along the large retinal vessels, small vessel leakage, and cystoid or diffuse macular edema. Circulation times are often delayed<sup>28</sup> and the vessels empty much more rapidly than in a normal eye.<sup>23</sup> The birdshot lesions themselves are not usually visible unless there has been loss of the retinal pigment epithelium over them with creation of a window defect. ICG angiography shows the birdshot lesions very well as areas of blockage in the early to midphases of the angigram, which may persist into the late stages.<sup>29</sup> The lesions appear to line up along the large choroidal veins. Electroretinography is often abnormal with reduced rod and cone amplitudes and increased latencies.<sup>30-32</sup> Visual field testing can confirm overall depression of retinal function and scotomata.<sup>33</sup>

The etiology of birdshot chorioretinopathy is unknown. HLA-A29 positivity is strongly associated with birdshot chorioretinopathy<sup>34,35</sup> and is often considered necessary for the diagnosis. Recent histopathologic examination of autopsy eyes of a patient with birdshot showed mixed T and B cells in the choroidal lesions<sup>36</sup> and no organisms. Loss of retinal function is diffuse and may relate either to damage from the chronic retinovascular inflammation and hypoperfusion or to changes in the retinal pigment epithelium and choroid affecting the photoreceptors, or both.

Treatment with low doses of cyclosporine has been reported to be beneficial; some patients also required treatment with azathioprine.<sup>37,38</sup> Other treatments are low doses of systemic corticosteroids and intravitreal triamcinolone for refractory cystoid macular edema.<sup>39,40</sup> Complications of choroidal neovascularization may limit vision,<sup>41</sup> but visual impairment is usually accompanied by progressive vascular attenuation, macular edema or optic nerve atrophy. Patients suspected of having birdshot chorioretinopathy should have HLA-A29 typing. Consideration of alternative diagnoses such as sarcoidosis, Vogt-Koyanagi-Harada, retinal dystrophies, intraocular lymphoma, and other posterior uveitides is appropriate.

• **DIFFUSE UNILATERAL SUBACUTE NEURORETINITIS:** In 1978, Gass published a series of articles on 29 patients with unilateral "retinal wipe-out"<sup>42</sup> and subsequently a series of articles on 36 patients, two of whom had a single, motile subretinal roundworm.<sup>43</sup> He advanced the concept that movement of a single parasite in the subretinal space led to the clinical syndrome that he named diffuse unilateral subacute neuroretinitis (DUSN) because of the inflammatory changes in the optic nerve and retina.

Unilateral visual loss, often with central or paracentral scotomata, is the primary symptom. Only two cases have been reported with bilateral disease.<sup>43,44</sup> The accompanying vitritis will often produce complaints of floaters. Frank inflammatory signs and symptoms are unusual, but eye redness can occur. Two patients have been reported with hypopyon.<sup>43,45</sup>

Gass's original papers provide the most complete description of the syndrome.<sup>42,43</sup> In the early stages, vision loss, afferent pupillary defect, and optic nerve edema or mild atrophy were common. All patients had vitritis. Narrowing of the arterioles was noted in approximately half of the patients.<sup>43</sup> Clusters of multiple gray-white or yellow-white lesions in the deep retina that faded within days were found in the majority of these early stage patients (Figure 3). Recurrent crops of lesions occurred for up to 20 months. Progressive pigment epithelial changes occurred with resolution of the active lesions. In the late or inactive stages, pigment epithelial atrophy (and occasional hypertrophy) was prominent as well as arteriolar narrowing and sheathing, and optic disk atrophy. Choroidal neovascularization, hypertrophy of the retinal pigment epithelium, and subretinal fibrosis can occur. The average age at onset of first symptoms is 14 years.<sup>43</sup>

IVFA demonstrates the retinal pigment epithelium changes well. Active lesions are hypofluorescent in the early stage and stain at a later stage. Mild leakage may occur from the optic nerve and any areas of active retinal involvement.<sup>43</sup> The electroretinogram is usually moderately to severely affected, but not extinguished.<sup>43</sup> Direct visualization of the nematode is generally made on clinical examination with fundus contact lenses and by scrutiny of fundus photographs. However, examination with scanning

laser ophthalmoscopy (SLO) provides a high contrast image that may facilitate visualization of the nematode.<sup>46</sup> Live video imaging with the SLO may also help document motility.

The causative agent of DUSN is often suspected to be a toxocaral species. However, the infective second stage larvae of toxocara are somewhat smaller compared with the 400  $\mu\text{m}$  to 1000  $\mu\text{m}$  "Southern" worm found most often in patients from warm climates.<sup>47</sup> Additionally, it is unusual for toxocaral serum antibody titers to be unequivocally positive in patients with DUSN.<sup>47</sup> A second, larger "Northern" worm has been proposed to be the larval form of an intestinal parasite of raccoons, *Baylisascaris procyonis*.<sup>48,49</sup> Also, multiple intestinal roundworms (ascarides) from a variety of animal species can probably produce DUSN. One surgically extracted nematode was observed to be a third stage larva of a toxocaral species based on morphologic grounds<sup>50</sup> and one case was reported with markedly positive antitoxocaral titers and eosinophilia.<sup>51</sup>

Laser photocoagulation of visualized nematodes arrests the visual deterioration and should be attempted in all cases.<sup>47,52</sup> Treatment with antihelminthic medication has variable reports of success and is usually ineffective.<sup>47,53,54</sup> An acute focus of retinitis occurring 4 to 7 days after treatment with thiabendazole or ivermectin is presumptive evidence of death of the nematode.<sup>55</sup> Treatment with albendazole may be as effective as thiabendazole and better tolerated with fewer systemic side effects. Surgical extraction, either transclerally<sup>47</sup> or transvitreally<sup>50</sup> may be appropriate in young children who cannot tolerate laser photocoagulation. Diagnosis is made on clinical grounds and systemic evaluation is unlikely to be helpful. Information concerning residence, contact with soil, or contact with animals can help support the diagnosis.

• **MULTIPLE EVANESCENT WHITE DOT SYNDROME:** MEWDS primarily affects young adults between the ages of 20 and 45 years of age. There is a strong female predilection. Although typically unilateral, bilateral cases of MEWDS have been described.<sup>56</sup> There are no known racial or hereditary associations. Patients with MEWDS usually present with sudden visual alterations in one eye. Symptoms include blurred vision, temporal or paracentral scotomas, photopsia, and dyschromatopsia. A preceding viral illness has been reported in approximately one third of cases.

Visual acuity is variable and ranges from 20/20 to 20/400. A small degree of myopia is common. A relative afferent pupillary defect may be present. The anterior segment appears normal, without signs of inflammation. Vitreous cells are mild. The optic disk may be hyperemic or edematous. The characteristic lesions are multiple small, ill-defined white-dots located at the level of the outer retina or retinal pigment epithelium (Figure 4).<sup>57</sup> The lesions may be subtle and fade within the first few weeks of the disease. The fovea may have an unusual orange-yellow

granularity; this granularity may persist after resolution of the white dot lesions. Atypical findings include circum-papillary patches with or without paramacular involvement and choroidal neovascularization.<sup>58,59</sup>

Visual field testing reveals enlargement of the blind spot. Other temporal and paracentral scotomas may be detected. Fluorescein angiography demonstrates early and late hyperfluorescence of the white dots. The optic disk may be hyperfluorescent in the late phase of the study. ICG angiography reveals multiple small, round hypofluorescent spots in the posterior and midperipheral fundus. The number of spots seen on ICG may be more numerous than those seen clinically or with fluorescein angiography. Electrophysiologic testing may demonstrate a reduced a-wave on the ERG.<sup>60</sup> The EOG also may be abnormal. The ERG and EOG abnormalities usually normalize with resolution of symptoms.

The cause of MEWDS is unknown. A viral etiology has been suggested. Fluorescein angiographic and electrophysiologic studies have demonstrated the involvement of the retinal pigment epithelium and photoreceptors in MEWDS. The findings with ICG angiography suggest that MEWDS affects the choroidal circulation as well. The relationship of MEWDS with the other inflammatory white dot syndromes is controversial.<sup>61,62</sup> MEWDS has been associated with acute macular neuroretinopathy and multifocal choroiditis and panuveitis.<sup>63-65</sup> Controversy exists as to whether or not MEWDS is related to acute idiopathic blind spot enlargement syndrome.<sup>66,67</sup>

MEWDS resolves spontaneously without need for treatment. The prognosis is generally very good, with most patients achieving normal vision and visual fields within several weeks to months. However, visual field loss (blind spot enlargement), photopsia, and dyschromatopsia may persist. Recurrence is unusual but has been reported.

• **MULTIFOCAL CHOROIDITIS AND PANUVEITIS:** MFC is a syndrome simulating presumed ocular histoplasmosis syndrome but includes vitreous inflammation, anterior uveitis, and active choroidal lesions.<sup>68,69</sup> Punctate inner choroiditis (PIC) is a similar syndrome characterized by myopia, photopsia, and scotoma in women, with the choroidal lesions largely confined to the posterior pole.<sup>70</sup> PIC has no associated vitritis, but may progress to develop vitritis and widespread lesions indistinguishable from multifocal choroiditis. Some eyes with multifocal choroiditis may go on to develop Diffuse Subretinal Fibrosis (DSF) characterized by a coalescence of lesions and broad zones of subretinal fibrosis.<sup>71,72</sup> These three conditions, MFC, PIC, and DSF, likely represent a continuum of severity of a single syndrome.

Patients may present with decreased vision attributable to floaters and vitritis. Acute choroidal lesions beneath the macula center, cystoid macular edema (CME), or exudation secondary to choroidal neovascularization may cause decreased vision. Retinal pigment epithelial metaplasia



and the formation of fibrotic scars in the macula may also cause loss of vision.<sup>73</sup> Some patients may develop peripheral visual field loss not corresponding to focal areas of choroiditis.<sup>74</sup>

Punched-out chorioretinal scars with pigmented borders within the posterior pole and periphery similar to those found in presumed ocular histoplasmosis are typically found in patients with MFC. These lesions are usually 50  $\mu\text{m}$  to 100  $\mu\text{m}$  in diameter. Acute lesions are yellow-white and primarily involve the choroid and outer retina.<sup>68</sup> There is the frequent development of macular and juxtapapillary choroidal neovascularization, which is the most frequent cause of severe visual loss (Figure 5).<sup>73</sup> The presence of vitritis as well as anterior chamber inflammation is an important requirement for the definition of MFC, excluding a diagnosis of presumed ocular histoplasmosis. The disease is usually bilateral but may be asymmetric, with delayed development of disease in the second eye. There is a predilection for women, and most are affected within their third decade of life.<sup>68</sup>

IVFA may demonstrate lesions within the macula, which are not visible by ophthalmoscopy. Acute lesions demonstrate early hypofluorescence with late hyperfluorescent staining. Such lesions may develop in the course of observation of a patient. The fluorescein angiogram may demonstrate CME, leakage from acute lesions within the macula, and choroidal neovascularization arising from juxtapapillary or macular scars.<sup>68</sup> Visual field testing may demonstrate an enlarged blind spot<sup>74,75</sup> and peripheral visual field loss not corresponding to acute choroiditis.<sup>68</sup> Electrophysiologic study has yielded variable results. Some patients with MFC may have severely reduced ERGs, while others may have normal findings.<sup>68</sup> Multifocal electroretinography may demonstrate decreased function within the macula.<sup>76</sup>

The cause of MFC is unknown. It has been hypothesized that an exogenous pathogen may sensitize an individual to antigens within the photoreceptors, retinal pigment epithelium, or choroid.<sup>77</sup> Subsequent exacerbations may occur without an inciting pathogen. As the etiology of this syndrome is unknown, there remains controversy regarding whether MFC, PIC and DSF are separate entities or different manifestations of the same disease.<sup>78</sup> Gass has proposed that MFC along with MEWDS, AMN, and acute idiopathic blind spot enlargement syndrome be grouped within the AZOOR complex of disorders (see below).

MFC tends to be a chronic disorder lasting months to years. Visual prognosis is generally poor. Severe visual loss may occur because of diskiform macular scarring, macular fibrotic scarring, atrophy, or chronic CME.<sup>68,73</sup> The use of systemic or periocular corticosteroids is effective in controlling MFC, especially in the early stages of the disease before development of choroidal neovascularization or subretinal fibrosis.<sup>68</sup> Some patients may require immunosuppressive agents to control the disease.<sup>79</sup> Successful control of choroidal neovascularization with corticoste-

roids has been reported, although this may be the natural course of regression of some lesions. Recently photodynamic therapy has been used successfully to treat subfoveal choroidal neovascularization associated with MFC.<sup>80</sup>

• **SERPIGINOUS CHOROIDITIS:** Serpiginous choroiditis is a chronic, progressive inflammatory condition affecting the choroid and retinal pigment epithelium.<sup>81-84</sup> Recurrences are common and can occur weeks to years after the initial event. It is typically bilateral but may be asymmetric. Symptoms include blurred vision, photopsias, paracentral scotomas, metamorphopsia, and visual field loss.

On examination, the anterior segment is usually normal. If present, the vitritis is mild. Serpiginous choroiditis involves the peripapillary region and macula. Acute lesions are slightly ill-defined, gray-white, jigsaw puzzle-shaped lesions at the level of the choriocapillaris and retinal pigment epithelium (Figure 6). The active lesions may be associated with shallow subretinal fluid. Acute lesions are commonly located adjacent to atrophic scars. As the acute lesion clears, extensive atrophy of the choriocapillaris, retinal pigment epithelium, and retina is seen.<sup>85</sup> Areas of retinal pigment epithelium hyperpigmentation and subretinal fibrosis are common. Choroidal neovascularization may develop.<sup>86,87</sup>

IVFA shows early hypofluorescence of the active lesions. The late phase of the study demonstrates hyperfluorescence of the border of the active lesion that may extend centrally. ICG angiography is divided into 4 stages: (1) hypofluorescent lesions in the subclinical or choroidal stage, (2) hypofluorescent lesions in the active stage, larger than those defined on IVFA, (3) hyperfluorescence in the healing and subhealing stage, and (4) hypofluorescent lesions with clearly defined margins in the inactive stage.<sup>88</sup> Electrophysiologic studies are usually normal.

The etiology of serpiginous choroiditis is unknown. An immune-mediated mechanism has been postulated attributable to an increased frequency of HLA-B7 and retinal S antigen associations.<sup>89,90</sup> A possible association with Herpes viruses has also been postulated.<sup>91</sup> An elevation of factor VIII-von Willebrand antigen has been found in a small series of patients that were tested.<sup>92</sup>

Several treatments have been tried, but the low incidence of the disease has precluded a randomized treatment trial to date. Corticosteroids alone do not appear to be effective.<sup>93</sup> Immunosuppressive agents such as cyclosporine, azathioprine, chlorambucil, and cyclophosphamide have been tried in limited series.<sup>94-97</sup> These agents have significant side effects and one patient developed bladder cancer, a known complication of alkylating agents. Acyclovir has been used in a small number of cases as well. Laser photocoagulation or photodynamic therapy may be helpful in cases of choroidal neovascularization,<sup>98</sup> but neither is effective for the active inflammatory lesions. Visual loss results from direct foveal involvement or the development of choroidal neovascularization.

• **ACUTE ZONAL OCCULT OUTER RETINOPATHY:** AZOOR is a syndrome of one or more episodes of outer retinal dysfunction that occurs in young to middle age patients.<sup>99</sup> In patients with AZOOR, the areas of retinal dysfunction may progress to develop retinal cell death.<sup>99</sup>

The early symptoms of AZOOR are acute visual field loss and photopsias in one or both eyes. The photopsias in AZOOR can be very distinctive: patients describe photopsias as movement of colors or lights within the area of visual field loss. These photopsias are often chronic. Patients typically have no retinal findings on initial examination, making the diagnosis extremely difficult. Gass reports that vitreous cells are present in approximately one-half of patients in the first few months after onset.<sup>99</sup> An afferent pupillary defect develops in a minority of patients. Visual field loss often occurs in the temporal visual field near or including the blind spot. Over time, the visual field defect can enlarge and can move peripherally or centrally. Patients with large scotomas may develop retinal pigment epithelial atrophy and intraretinal pigment migration (simulating retinitis pigmentosa) in the areas of visual field loss.<sup>99</sup>

Although patients with AZOOR often have unilateral signs and symptoms on presentation, Gass and associates reported in a series of 51 patients with long-term follow up (minimum follow up of 3 years) that AZOOR developed into a bilateral condition in 39 (76%) of 51 patients.<sup>100</sup> This same series revealed that recurrent episodes of AZOOR occurred in one-third of patients. A variant of AZOOR has been described called acute annular outer retinopathy.<sup>101</sup> In these patients, the leading edge of dysfunctional retina exhibits an unusual gray intraretinal ring. This ring may be evidence of an intraretinal autoimmune reaction.<sup>102</sup>

IVFA is normal in patients with AZOOR. Visual field tests demonstrate zones of visual field loss that can be central or peripheral in location. The ERG in patients with AZOOR is useful in demonstrating outer retinal dysfunction. The nature of the ERG changes are variable as patients may demonstrate either rod or cone photoreceptor dysfunction.

The cause of this disorder is unknown. Medical examination of patients with AZOOR is typically negative. The long-term follow-up study by Gass and associates has shown a 28% incidence of autoimmune disease, including Hashimoto's thyroiditis, and relapsing transverse myelopathy.<sup>100</sup> The acute onset of AZOOR also suggests the possibility of viral or other infectious agents. The differential diagnosis for AZOOR includes optic neuritis and other causes of outer retinal dysfunction such as retinitis pigmentosa, cancer-associated retinopathy, and cone dystrophy. Although this condition is difficult to diagnose, AZOOR must be considered in patients with the following constellation of signs and symptoms: rapid onset of visual field loss in one or both eyes, photopsias within the area of visual

field loss, absence of retinal or optic nerve changes on fundus examination, and ERG abnormalities.

Some patients with AZOOR may have had or will develop other idiopathic retinal conditions including: acute idiopathic blind-spot enlargement syndrome, MEWDS, MFC, and AMN. The frequency of acute visual field loss and photopsias in patients with these retinal conditions suggests that AZOOR may be an underlying or associated condition.

No treatment has been found effective in treating AZOOR. The course of the disease is variable. In his series, Gass reports that 88% of patients had 20/40 or better visual acuity in at least one eye on final follow-up examination. In this same series, stabilization of visual field loss occurred in 78% of AZOOR patients within the first 6 months and improvement in visual field occurred in 20% of patients.<sup>102</sup>

---

## CONCLUSION

THE WHITE DOT SYNDROMES ARE A DISTINCTIVE GROUP OF disorders affecting the retina, retinal pigment epithelium, and choroid. For clinicians and researchers alike, they present significant diagnostic and therapeutic challenges. During the past five decades, beginning with his landmark publication on APMPPE in 1968,<sup>5</sup> Gass has described, compared, and contrasted the clinical findings of the white dot syndromes. His remarkable observational skills combined with his ability to analyze, synthesize, and apply information has provided significant insight into the characteristic features of these conditions. His contributions will continue to guide and shape the direction of future research to uncover the cause of the white dot syndromes and provide more effective treatment options.

---

## REFERENCES

1. Gass JDM. Stereoscopic atlas of macular diseases: diagnosis and treatment, 4th ed., St. Louis: Mosby, 1997.
2. Gass JDM. Acute zonal occult outer retinopathy. *J Clin Neuroophthalmol* 1993;13:79-97.
3. Gass JDM. Are acute occult outer retinopathy and the white spot syndromes (AZOOR Complex) specific autoimmune diseases? *Am J Ophthalmol* 2003;135:380-381.
4. Jampol LM, Becker KG. White spot syndromes of the retina: a hypothesis based on the common genetic hypothesis of autoimmune/inflammatory disease. *Am J Ophthalmol* 2003;135:376-379.
5. Gass JDM. Acute posterior multifocal placoid pigment epitheliopathy. *Arch Ophthalmol* 1968;80:177-185.
6. Allee SD, Marks SJ. Acute posterior multifocal placoid pigment epitheliopathy with bilateral central retinal vein occlusion. *Am J Ophthalmol* 1998;126:309-312.
7. Isahiki M, Koide H, Yamashita T, Ohba N. Acute posterior multifocal placoid pigment epitheliopathy associated with diffuse retinal vasculitis and late haemorrhagic macular detachment. *Br J Ophthalmol* 1986;70:255-259.

8. De Souza S, Aslanides IM, Altomare F. Acute posterior multifocal placoid pigment epitheliopathy associated with retinal vasculitis, neovascularization and subhyaloid hemorrhage. *Can J Ophthalmol* 1999;34:343–345.
9. Abu El-Asrar AM, Aljazairy AH. Acute posterior multifocal placoid pigment epitheliopathy with retinal vasculitis and papillitis. *Eye* 2002;16:642–644.
10. Wright BE, Bird AC, Hamilton AM. Placoid pigment epitheliopathy and Harada's disease. *Br J Ophthalmol* 1978;62:609–621.
11. Anderson K, Patel KR, Webb L, Dutton GN. Acute posterior multifocal placoid pigment epitheliopathy associated with pulmonary tuberculosis. *Br J Ophthalmol* 1996;80:186.
12. Lowder CY, Foster RE, Gordon SM, Gutman FA. Acute posterior multifocal placoid pigment epitheliopathy after acute group A streptococcal infection. *Am J Ophthalmol* 1996;122:115–117.
13. Bourges JL, Pisella PJ, Laurens C, Limon S. Multifocal placoid epitheliopathy and anti-hepatitis B vaccination. *J Fr Ophtalmol* 1998;21:696–700.
14. Borruat FX, Piguet B, Herbort CP. Acute posterior multifocal placoid pigment epitheliopathy following mumps. *Ocul Immunol Inflamm* 1998;6:189–193.
15. Chiquet C, Lumbroso L, Denis P, Papo T, Durieu I, Lehoang P. Acute posterior multifocal placoid pigment epitheliopathy associated with Wegener's granulomatosis. *Retina* 1999;19:309–313.
16. Di Crecchio, Parodi MB, Saviano S, Ravalico G. Acute posterior multifocal placoid pigment epitheliopathy and ulcerative colitis: a possible association. *Acta Ophthalmol Scand* 2001;79:319–321.
17. Hsu CT, Harlan JB, Goldberg MF, Dunn JP. Acute posterior multifocal placoid pigment epitheliopathy associated with a systemic necrotizing vasculitis. *Retina* 2003;23:64–68.
18. Dick DJ, Neuman PK, Richardson J, Wilkinson R, Morley AR. Acute posterior multifocal placoid pigment epitheliopathy and sarcoidosis. *Br J Ophthalmol* 1988;72:74–77.
19. Wolf MD, Folk JC, Nelson JA, Peeples ME. Acute, posterior, multifocal, placoid, pigment epitheliopathy and Lyme disease. *Arch Ophthalmol* 1992;110:750.
20. Wolf MD, Folk JC, Panknen CA, Goeken NE. HLA-B7 and HLA-DR2 antigens and acute posterior multifocal placoid pigment epitheliopathy. *Arch Ophthalmol* 1990;108:698–700.
21. Pagliarini S, Piguet B, Ffytche TJ, Byrd AC. Foveal involvement and lack of visual recovery in APMPE associated with uncommon features. *Eye* 1995;9:42–47.
22. Wilson CA, Choromokos EA, Sheppard R. Acute posterior multifocal placoid pigment epitheliopathy and cerebral vasculitis. *Arch Ophthalmol* 1988;106:796–800.
23. Gass JD. Vitiliginous chorioretinitis. *Arch Ophthalmol* 1981;99:1778–1787.
24. Ryan SJ, Maumenee AE. Birdshot retinochoroidopathy. *Am J Ophthalmol* 1980;89:31–45.
25. Gass JDM. Vitiliginous chorioretinitis (bird-shot retinochoroidopathy). *Stereoscopic atlas of macular diseases: diagnosis and treatment*, 4th ed., St. Louis: Mosby, 1997;710–713.
26. Levinson RD, Gonzales CR. Birdshot retinochoroidopathy: immunopathogenesis, evaluation, and treatment. *Ophthalmol Clin North Am* 2002;15:343–350.
27. Cassoux N, Lehoang P. [Birdshot retinochoroidopathy]. *Ann Med Interne (Paris)* 2000;151(1 Suppl):S45–S47.
28. Guex-Crosier Y, Herbort CP. Prolonged retinal arteriovenous circulation time by fluorescein but not by indocyanine green angiography in birdshot chorioretinopathy. *Ocul Immunol Inflamm* 1997;5:203–206.
29. Fardeau C, Herbort CP, Kullmann N, et al. Indocyanine green angiography in birdshot chorioretinopathy. *Ophthalmology* 1999;106:1928–1934.
30. Fuerst DJ, Tessler HH, Fishman GA, et al. Birdshot retinochoroidopathy. *Arch Ophthalmol* 1984;102:214–219.
31. Hirose T, Katsumi O, Pruett RC, et al. Retinal function in birdshot retinochoroidopathy. *Acta Ophthalmol (Copenh)* 1991;69:327–337.
32. Zacks DN, Samson CM, Loewenstein J, Foster CS. Electroretinograms as an indicator of disease activity in birdshot retinochoroidopathy. *Graefes Arch Clin Exp Ophthalmol* 2002;240:601–607.
33. de Courten C, Herbort CP. Potential role of computerized visual field testing for the appraisal and follow-up of birdshot chorioretinopathy. *Arch Ophthalmol* 1998;116:1389–1391.
34. Lehoang P, Ozdemir N, Benhamou A, et al. HLA-A29.2 subtype associated with birdshot retinochoroidopathy. *Am J Ophthalmol* 1992;113:33–35.
35. Nussenblatt RB, Mittal KK, Ryan S, et al. Birdshot retinochoroidopathy associated with HLA-A29 antigen and immune responsiveness to retinal S-antigen. *Am J Ophthalmol* 1982;94:147–158.
36. Gaudio PA, Kaye DB, Crawford JB. Histopathology of birdshot retinochoroidopathy. *Br J Ophthalmol* 2002;86:1439–1441.
37. Nussenblatt RB. Reduction of cyclosporine dosage with ketoconazole in a patient with birdshot retinochoroidopathy. *Am J Ophthalmol* 1998;126:742.
38. Vitale AT, Rodriguez A, Foster CS. Low-dose cyclosporine therapy in the treatment of birdshot retinochoroidopathy. *Ophthalmology* 1994;101:822–831.
39. Ladas JG, Arnold AC, Holland GN. Control of visual symptoms in two men with birdshot retinochoroidopathy using low-dose oral corticosteroid therapy. *Am J Ophthalmol* 1999;128:116–118.
40. Martidis A, Duker JS, Puliafito CA. Intravitreal triamcinolone for refractory cystoid macular edema secondary to birdshot retinochoroidopathy. *Arch Ophthalmol* 2001;119:1380–1383.
41. Brucker AJ, Deglin EA, Bene C, Hoffman ME. Subretinal choroidal neovascularization in birdshot retinochoroidopathy. *Am J Ophthalmol* 1985;99:40–44.
42. Gass, J DM, Scelfo, R. Diffuse unilateral subacute neuroretinitis. *J R Soc Med* 1978;71:95–111.
43. Gass JD, Gilbert WR Jr., Guerry RK, Scelfo R. Diffuse unilateral subacute neuroretinitis. *Ophthalmology* 1978;85:521–545.
44. de Souza EC, Abujamra S, Nakashima Y, Gass JD. Diffuse bilateral subacute neuroretinitis: first patient with documented nematodes in both eyes. *Arch Ophthalmol* 1999;117:1349–1351.
45. Muccioli C, Belfort R, Jr. Hypopyon in a patient with presumptive diffuse unilateral subacute neuroretinitis. *Ocul Immunol Inflamm* 2000;8:119–121.
46. Moraes LR, Cialdini AP, Avila MP, Elsner AE. Identifying live nematodes in diffuse unilateral subacute neuroretinitis by using the scanning laser ophthalmoscope. *Arch Ophthalmol* 2002;120:135–138.
47. Gass JD, Braunstein RA. Further observations concerning the diffuse unilateral subacute neuroretinitis syndrome. *Arch Ophthalmol* 1983;101:1689–1697.
48. Goldberg MA, Kazacos KR, Boyce WM, Ai E, Katz B. Diffuse unilateral subacute neuroretinitis. Morphometric,

- serologic, and epidemiologic support for Baylisascaris as a causative agent. *Ophthalmology* 1993;100:1695-1701.
49. Mets MB, Noble AG, Basti S. Eye findings of diffuse unilateral subacute neuroretinitis and multiple choroidal infiltrates associated with neural larva migrans due to *Bbaylisascaris procyonis*. *Am J Ophthalmol* 2003;135:888-890.
  50. de Souza EC, Nakashima Y. Diffuse unilateral subacute neuroretinitis. Report of transvitreal surgical removal of a subretinal nematode. *Ophthalmology* 1995;102:1183-1186.
  51. Oppenheim S, Rogell G, Peyser R. Diffuse unilateral subacute neuroretinitis. *Ann Ophthalmol* 1985;17:336-338.
  52. Raymond LA, Gutierrez Y, Strong LE, Wander AH, Buten R, Cordan D. Living retinal nematode (filarial-like) destroyed with photocoagulation. *Ophthalmology* 1978;85:944-949.
  53. Gass JD, Callanan DG, Bowman CB. Successful oral therapy for diffuse unilateral subacute neuroretinitis. *Trans Am Ophthalmol Soc* 1991;89:97-112.
  54. Casella AM, Farah ME, Belfort R, Jr. Antihelminthic drugs in diffuse unilateral subacute neuroretinitis. *Am J Ophthalmol* 1998;125:109-111.
  55. Gass JD, Callanan DG, Bowman CB. Oral therapy in diffuse unilateral subacute neuroretinitis. *Arch Ophthalmol* 1992;110:675-680.
  56. Aaberg TM, Campo RV, Joffe L. Recurrences and bilaterality in the multiple evanescent white-dot syndrome. *Am J Ophthalmol* 1985;100:29-37.
  57. Jampol LM, Sieving PA, Pugh D, Fishman GA, Gilbert H. Multiple evanescent white dot syndrome. I. Clinical findings. *Arch Ophthalmol* 1984;102:671-674.
  58. Luttrull JK, Marmor MF, Nanda M. Progressive confluent circumpapillary multiple evanescent white-dot syndrome. *Am J Ophthalmol* 1999;128:378-380.
  59. Oh KT, Christmas NJ, Russell SR. Late recurrence and choroidal neovascularization in multiple evanescent white dot syndrome. *Retina* 2001;21:182-184.
  60. Sieving PA, Fishman GA, Jampol LM, Pugh D. Multiple evanescent white dot syndrome. II. Electrophysiology of the photoreceptors during retinal pigment epithelial disease. *Arch Ophthalmol* 1984;102:675-679.
  61. Gass JD. Acute zonal occult outer retinopathy. Donders Lecture: The Netherlands Ophthalmological Society, Maastricht, Holland, June 19, 1992. *J Clin Neuroophthalmol* 1993;13:79-97.
  62. Reddy CV, Brown J Jr., Folk JC, Kimura AE, Gupta S, Walker J. Enlarged blind spots in chorioretinal inflammatory disorders. *Ophthalmology* 1996;103:606-617.
  63. Gass JD, Hamed LM. Acute macular neuroretinopathy and multiple evanescent white dot syndrome occurring in the same patients. *Arch Ophthalmol* 1989;107:189-193.
  64. Callanan D, Gass JD. Multifocal choroiditis and choroidal neovascularization associated with the multiple evanescent white dot and acute idiopathic blind spot enlargement syndrome. *Ophthalmology* 1992;99:1678-1685.
  65. Bryan RG, Freund KB, Yannuzzi LA, Spaide RF, Huang SJ, Costa DL. Multiple evanescent white dot syndrome in patients with multifocal choroiditis. *Retina* 2002;22:317-322.
  66. Hamed LM, Glaser JS, Gass JD, Schatz NJ. Protracted enlargement of the blind spot in multiple evanescent white dot syndrome. *Arch Ophthalmol* 1989;107:194-8.
  67. Volpe NJ, Rizzo RF 3rd, Lessell S. Acute idiopathic blind spot enlargement syndrome: a review of 27 new cases. *Arch Ophthalmol* 2001;119:59-63.
  68. Dreyer RF, Gass JDM. Multifocal choroiditis and panuveitis: a syndrome that mimics ocular histoplasmosis. *Arch Ophthalmol* 1984;102:1776-1784.
  69. Morgan CM, Schatz H. Recurrent multifocal choroiditis. *Ophthalmology* 1986;93:1138-1147.
  70. Watzke RC, Packer AJ, Folk JC, Benson WE, Burgess D, Ober RR. Punctate Inner Choroidopathy. *Am J Ophthalmol* 1984;98:572-584.
  71. Cantrill HL, Folk JC. Multifocal choroiditis associated with progressive subretinal fibrosis. *Am J Ophthalmol* 1986;15:101:170-180.
  72. Palestine AG, Nussenblatt RB, Parver LM, Knox DL. Progressive subretinal fibrosis and uveitis. *Br J Ophthalmol* 1985;68:667-673.
  73. Brown J Jr., Folk JC, Reddy CV, Kimura AE. Visual prognosis of multifocal choroiditis, punctate inner choroidopathy, and the diffuse subretinal fibrosis syndrome. *Ophthalmology* 1996;103:1100-1105.
  74. Reddy CV, Brown J Jr., Folk JC, Kimura AE, Gupta S, Walker J. Enlarged blind spots in chorioretinal inflammatory disorders. *Ophthalmology* 1996;103:606-617.
  75. Khorram KD, Jampol LM, Rosenberg MA. Blind spot enlargement as a manifestation of multifocal choroiditis. *Arch Ophthalmol* 1991;109:1403-1407.
  76. Oh KT, Folk JC, Maturi RK, Moore P, Kardon RH. Multifocal electroretinography in multifocal choroiditis and the multiple evanescent white dot syndrome. *Retina* 2001;21:581-589.
  77. Folk JC, Gehrs KM. Multifocal choroiditis with panuveitis, diffuse subretinal fibrosis, and punctate choroidopathy. In: *Retina*, Vol 2, 3rd ed., St. Louis: Andrew P. Schachat, 2001:1709-1720.
  78. Brown J Jr., Folk JC. Current controversies in the white dot syndromes. Multifocal choroiditis, punctate inner choroidopathy, and the diffuse subretinal fibrosis syndrome. *Ocul Immunol Inflamm* 1998;6:125-127.
  79. Michel SS, Ekong A, Baltatzis S, Foster CS. Multifocal choroiditis and panuveitis: immunomodulatory therapy. *Ophthalmology* 2002;109:378-383.
  80. Spaide RF, Freund KB, Slakter J, Sorenson J, Yannuzzi LA, Fisher Y. Treatment of subfoveal choroidal neovascularization associated with multifocal choroiditis and panuveitis with photodynamic therapy. *Retina* 2002;22:545-549.
  81. Gass JDM. Stereoscopic atlas of macular diseases: a fundoscopic and angiographic presentation. St. Louis: Mosby, 1970:66.
  82. Hamilton AM, Bird AC. Geographical choroidopathy. *Br J Ophthalmol* 1974;58:784-797.
  83. Laatikainen L, Erkkila H. Serpiginous choroiditis. *Br J Ophthalmol* 1974;58:777-783.
  84. Schatz H, Maumenee AE, Patz A. Geographic helicoids peripapillary choroidopathy: Clinical presentation and fluorescein angiographic findings. *Trans Am Acad Ophthalmol Otolaryngol* 1974;78:747-761.
  85. Chisholm IH, Gass JD, Hutton WL. The late stage of serpiginous (geographic) choroiditis. *Am J Ophthalmol* 1976;82:343-351.
  86. Jampol LM, Orth D, Daily MJ, Rabb MF. Subretinal neovascularization with geographic (serpiginous) choroiditis. *Am J Ophthalmol* 1979;88:683-689.
  87. Laatikainen L, Erkkila H. Subretinal and disk neovascularization in serpiginous choroiditis. *Br J Ophthalmol* 1982;66:326-331.
  88. Bouchenaki N, Cimino L, Auer C, Tao Tran V, Herbort CP. Assessment and classification of choroidal vasculitis in posterior uveitis using indocyanine green angiography. *Klin Monatsbl Augenheilkd* 2002;219:243-249.
  89. Broekhuysse RM, van Herck M, Pinckers AJ, et al. Immune

- responsiveness to retinal S-antigen and opsin in serpiginous choroiditis and other retinal diseases. *Doc Ophthalmol* 1988;69:83–93.
90. Erkkila H, Laatikainen L, Jokinen E. Immunological studies on serpiginous choroiditis. *Graefes Arch Clin Exp Ophthalmol* 1982;219:131–134.
  91. Priya K, Madhavan HN, Reiser BJ, et al. Association of herpes viruses in the aqueous humor of patients with serpiginous choroiditis: a polymerase chain reaction-based study. *Ocul Immunol Inflamm* 2002;10:253–261.
  92. King DG, Grizzard WS, Sever RJ, Espinoza L. Serpiginous choroidopathy associated with elevated factor VIII-von Willebrand factor antigen. *Retina* 1990;10:97–101.
  93. Christmas NJ, Oh KT, Oh DM, Folk JC. Long-term follow-up of patients with serpiginous choroiditis. *Retina* 2002;22:550–556.
  94. Secchi AG, Tognon MS, Maselli C. Cyclosporine-A in the treatment of serpiginous choroiditis. *Int Ophthalmol* 1990;14:395–9.
  95. Akpek EK, Baltatzis S, Yang J, Foster CS. Long-term immunosuppressive treatment of serpiginous choroiditis. *Ocul Immunol Inflamm* 2001;9:153–167.
  96. Hooper PL, Kaplan HJ. Triple agent immunosuppression in serpiginous choroiditis. *Ophthalmology* 1991;98:944–951.
  97. Akpek EK, Jabs DA, Tessler HH, Joondeph BC, Foster CS. Successful treatment of serpiginous choroiditis with alkylating agents. *Ophthalmology* 2002;109:1506–1513.
  98. Navajas EV, Costa RA, Farah ME, Cardillo JA, Bonomo PP. Indocyanine green-mediated photothrombosis combined with intravitreal triamcinolone for the treatment of choroidal neovascularization in serpiginous choroiditis. *Eye* 2003;17:563–566.
  99. Gass JDM. Acute zonal occult outer retinopathy. Donders lecture: The Netherlands Ophthalmological Society, Maastricht, Holland, June 19, 1992. *J Clin Neurol Ophthalmol* 1993;13:79–97.
  100. Gass JDM, Agarwal A, Scott IU. Acute zonal occult outer retinopathy: a long-term follow-up study. *Am J Ophthalmol* 2002;134:329–339.
  101. Gass JDM, Stern C. Acute annular outer retinopathy as a variant of acute zonal occult outer retinopathy. *Am J Ophthalmol* 1995;119:330–334.
  102. Fekrat S, Wilkinson CP, Chang B, et al. Acute annular outer retinopathy (AAOR). *Am J Ophthalmol* 2000;130:636–44.