

Therapeutic Effects of Tacrolimus Ointment for Refractory Ocular Surface Inflammatory Diseases

Dai Miyazaki, MD, Takeshi Tominaga, MD, Akiko Kakimaru-Hasegawa, MD, Yuiko Nagata, MD, Jiro Hasegawa, MD, Yoshitsugu Inoue, MD

Purpose: To investigate the therapeutic effects of topical tacrolimus ointment on refractory ocular surface inflammatory diseases.

Design: Retrospective interventional consecutive case series.

Participants: Ten consecutive patients with severe ocular surface inflammatory diseases who were suspected to be steroid responders (elevation of intraocular pressure [IOP]) or were refractory to standard steroid therapy were studied. One patient had peripheral ulcerative keratitis with impending corneal perforation, 1 had a Mooren's ulcer, 2 had scleroperikeratitis, 5 had atopic keratoconjunctivitis, and 1 had vernal keratoconjunctivitis.

Methods: The clinical findings and therapeutic responses after treatment with 0.02% topical tacrolimus ointment were determined by conventional ophthalmological examinations.

Main Outcome Measures: Resolution of the ocular surface diseases (e.g., decrease of hyperemia, ulceration, size of papillae) and IOP. The necessity to use steroids was also assessed.

Results: In all cases, marked to moderate improvement was obtained, including suppression of the melting reaction of the inflamed cornea, remission of scleroperikeratitis, and reduction of a giant papilla and corneal epithelial defect in severe atopic keratoconjunctivitis. The elevated IOP was reduced in steroid responders after successful cessation of steroid therapy. No adverse side effect was noted for 2 to 26 months of continuous treatment.

Conclusions: Topical tacrolimus ointment is effective in treating refractory ocular surface inflammatory diseases and should be considered as an alternative to higher doses, steroid supplementation, or surgical intervention. *Ophthalmology* 2008;115:988–992 © 2008 by the American Academy of Ophthalmology.



The management of refractory immune-mediated ocular surface diseases generally requires high doses of steroids or systemic immune suppressants. Cases of severe peripheral ulcerative keratitis, scleroperikeratitis, and atopic keratoconjunctivitis fall into this category of diseases. Systemic steroids and immune suppressants are generally used as therapeutic alternatives, but they can cause drug-induced renal dysfunction, hyperglycemia, osteoporosis, and cataracts. In addition, intense topical steroid treatment frequently causes an elevation of intraocular pressure (IOP), and the eye may become refractory to antiglaucoma medications.

Tacrolimus, a potent immunosuppressive macrolide, was originally isolated from *Streptomyces tsukubaensis*¹ and has been approved for prophylactic use to prevent allograft rejection of liver, kidney, bone marrow, heart, lung, and pancreas.² Topical tacrolimus is well known to be effective

in treating atopic dermatitis.³ In contrast to the many reports of the systemic and dermal use of tacrolimus, reports on its use for ocular diseases, especially ocular surface or corneal disorders, are limited.^{4–8}

The purpose of this study was to determine whether topical tacrolimus can be effective in the treatment of refractory ocular surface inflammatory disorders and to evaluate its effectiveness in eyes with atopic keratoconjunctivitis, vernal keratoconjunctivitis, peripheral ulcerative disease, and scleroperikeratitis. We examined 10 patients with ocular surface immune-mediated diseases who were treated with 0.02% topical tacrolimus ointment.

Materials and Methods

Ten patients with severe anterior segment inflammation who were treated with 0.02% topical tacrolimus ointment at the Tottori

The authors have no proprietary interests related to the article.

Correspondence and reprint requests to Dai Miyazaki, MD, 36-1 Nishi-cho Yonago, Tottori, Japan, 683-8504. E-mail: dm@grape.med.tottori-u.ac.jp.

Originally received: February 13, 2007.

Final revision: July 8, 2007.

Accepted: July 23, 2007.

Available online: September 27, 2007.

Manuscript no. 2007-203

From the Division of Ophthalmology and Visual Science, Tottori University Medical School, Yonago, Japan.

University Hospital, Tottori, Japan from April 2003 through February 2007 were studied. Topical tacrolimus was applied as a 0.02% ointment to the eye 1 to 4 times a day after obtaining informed consent.

The inclusion criteria were (1) severe ocular surface inflammatory diseases without posterior segment inflammation, (2) suspected steroid responders (elevation of IOP), and (3) refractory to or not suitable for standard steroid therapy. The first criterion was selected because of the low penetrance of topical tacrolimus into the anterior chamber (AC) and posterior segment.⁹

The off-label use of dermatological tacrolimus ointment for ophthalmic diseases was recently reported by Joseph et al.^{5,6} However, dermatologically intended ointments are viscous and not appropriate for tear film stability, as they lead to blurred vision. This formulation restricts the long-term use of dermatological tacrolimus ointment for eye diseases. In 2003, we developed a preparation of 0.02% tacrolimus ointment, which was prepared by diluting 0.1% tacrolimus ointment (Protopic, Astellas Pharma, Tokyo, Japan) with ofloxacin ocular ointment (Tarivid, Santen Pharmaceutical, Osaka, Japan). The base of the ofloxacin ocular ointment is purified lanolin, which is an emollient that forms a layer that slows the evaporation of tears and increases the moisture content by increasing water-holding capacity.

The clinical outcomes of tacrolimus treatment were analyzed by scoring the changes in representative parameters. Anterior segment inflammation was scored as an inflammation score of 0, none; 1, mild hyperemia; 2, moderate hyperemia; 3, severe but localized hyperemia without AC reactions; and 4, extensive hyperemia with ciliary injection or deeper scleral lesions with pain or iritis. The clinical parameters of atopic keratoconjunctivitis or vernal keratoconjunctivitis were scored 0, none; 1, papilla (<1 mm); 2, giant papilla (>1 mm) or diffuse punctate corneal staining; 3, giant papilla in eyelid (>3 mm); and 4, shield ulcer with giant papilla in the eyelid. These scores are a modification of previously reported criteria.¹⁰

The antiinflammatory effects and necessity to use steroid were scored 0, none; 1, topical nonsteroidal anti-inflammatory drugs or mast cell stabilizers; 2, topical fluoromethoron; 3, topical betamethasone; and 4, systemic steroid or immune suppression with topical betamethasone.

The study protocol conformed to the tenets of the Declaration of Helsinki, and the procedures used were approved by the Tottori University Ethics Committee.

Results

The characteristics and treatment parameters of the 10 patients with refractory ocular surface inflammatory disorders who were treated with 0.02% topical tacrolimus ointment are shown in Table 1. The mean age of the patients was 39 ± 8 years (range, 14–80). All patients were refractory to 0.1% topical betamethasone, 4 times daily, and all had histories of or were suspected to have an increase of IOP with topical steroids (i.e., steroid responders). Of these 10 patients, 5 eyes of 3 had glaucomatous visual field (VF) defects with enlarged cupping. Thus, the long-term use of topical steroid was not indicated.

The duration of the ocular surface disorders before tacrolimus treatment ranged from 2 months to 18 years, and the duration of follow-up after tacrolimus treatment ranged from 2 to 26 months (mean, 10 ± 3). None of the patients had a history of herpetic keratitis.

In patients with ulcerative keratitis, topical tacrolimus had potent antiinflammatory effects. Thus, in case 1 the steroid-resistant ulcer began to heal with remission of the marginal infiltrates in a few days. In case 2, tacrolimus treatment suppressed recurrence of the ulcer, and the remission was maintained. This enabled cataract surgery, which is generally contraindicated when keratitis is uncontrolled. In both cases, topical tacrolimus enabled

Table 1. Summary of Patients Treated with Topical Tacrolimus

Case	Diagnosis	Age	Gender	Duration before Tacrolimus Treatment (mos)	Duration of Topical Tacrolimus Treatment (mos)	IOP before Tacrolimus Treatment (mmHg) (Right Eye/ Left Eye)	IOP after Tacrolimus Treatment (mmHg) (Right Eye/ Left Eye)	Inflammation Score before Tacrolimus Treatment (Right Eye/ Left Eye)	Inflammation Score after Tacrolimus Treatment (Right Eye/ Left Eye)	Steroid Score before Tacrolimus Treatment	Steroid Score after Tacrolimus Treatment
1	Peripheral ulcerative keratitis	42	Male	7	26	41	12	3	1	4	0
2	Mooren's ulcer	75	Male	54	12	30/22	19/15	3/3	0/0	3	0
3	Scleroperikeratitis	56	Male	3	8	21	16	3	0	4	2
4	Scleroperikeratitis with Wegener's syndrome	80	Female	2	8	15	13	4	2	4	0
5	Atopic keratoconjunctivitis	37	Male	96	8	18/18	10/10	3/3	1/1	3	0
6	Atopic keratoconjunctivitis	16	Male	2	11	24	11	4	2	3	2
7	Atopic keratoconjunctivitis	14	Male	66	12	13/16	10/10	4/4	2/2	3	0
8	Atopic keratoconjunctivitis	31	Female	216	22	24/18	14/16	4/4	1/1	3	0
9	Atopic keratoconjunctivitis	17	Female	17	2	29/35	15/15	3/3	2/2	3	0
10	Vernal keratoconjunctivitis	18	Female	72	7	14	12	2/2	1/1	3	0

IOP = intraocular pressure.

a discontinuation or tapering of topical steroid without an increase in the incidence of relapses.

In the patients with scleroperikeratitis (cases 3 and 4), the peripheral corneal infiltrates adjacent to the refractory anterior scleritis were initially treated with topical betamethasone. However, this did not resolve the symptoms, and 1 to 2 subconjunctival injections of dexamethasone a week before tacrolimus treatment were added. This treatment caused a steroid-induced IOP elevation; however, the scleral hyperemia, indurated swelling, and pain were not resolved. Because an uncontrolled scleral inflammation can cause scleromalacia as well as sustained IOP elevation, systemic steroids were recommended, but the patients declined them. The patients agreed to topical tacrolimus. The topical tacrolimus ointment had an additive therapeutic effect to topical steroid and significantly reduced the scleral inflammation.

In case 3, topical betamethasone began to be tapered 1 week after the start of the tacrolimus treatment. When case 3 was switched to topical tacrolimus and fluoromethorone, IOPs were reduced from 24 to 16 mmHg with remission of the scleral inflammatory response. Fluoromethorone was discontinued, and tacrolimus treatment was tapered thereafter. Over an 18-month period, the scleral inflammation was well controlled with occasional use of tacrolimus 1 to 2 times a month.

In case 4, topical tacrolimus treatment also had beneficial effects; however, additional subconjunctival dexamethasone injections (1–4/week) were required, until the inflammation was finally controlled with topical tacrolimus only.

In patients with atopic keratoconjunctivitis (5 patients) and vernal keratoconjunctivitis (1 patient), the diffuse conjunctival injection and superficial punctate keratopathy were refractory to the standard treatment. Three patients (cases 6, 7, and 10) had a shield ulcer with corneal stromal scarring (Fig 1 [available at <http://aaojournal.org>]), and 5 patients (cases 6–10) had a giant papilla (>1 mm in diameter), edematous induration, and hyperemia in the upper eyelids (Table 2). All cases had been treated with topical betamethasone, the symptoms and signs persisted, and their IOPs increased.

When tacrolimus treatment was begun, all patients reported a marked improvement of their symptoms within 2 to 4 weeks. Topical steroids were then discontinued, with continued use of tacrolimus. Five patients (cases 5 and 7–10) maintained substantially diminished conjunctival hyperemia, papilla formation, and induration without relapse of the shield ulcer or superficial keratopathy for 2 to 22 months.

Representative parameters of the inflammation were evaluated in all of the 10 cases. The mean hyperemic score was significantly reduced, from 3.3 ± 0.2 to 1.2 ± 0.2 , after treatment ($P < 0.01$, Wilcoxon signed rank test; Table 1). In all 10 cases, tacrolimus

treatment enabled a discontinuation or tapering of steroids, and the inflammatory responses were mainly controlled by topical tacrolimus. The steroid score before tacrolimus treatment was significantly reduced, from 3.3 ± 0.2 to 0.4 ± 0.3 , after treatment ($P < 0.05$, Wilcoxon signed rank test; Table 1). The reduction of the steroids also led to a marked decrease in IOP. The mean IOP was 22.3 ± 2.3 before tacrolimus treatment and was significantly reduced to 13.6 ± 0.8 after tacrolimus with cessation of steroid therapy ($P < 0.01$, paired *t* test; Table 1). The IOP reduction was especially notable in cases 1 and 10, which had decreases in IOP of 29 mmHg and 20 mmHg, respectively.

The side effects of topical tacrolimus were a burning sensation of the eyelids and conjunctiva in 9 of 10 cases. However, all of the patients reported that this effect was tolerable and disappeared 2 to 4 weeks after continuous use. None of the patients developed lesions or other suspected infection during their follow-up. No corneal deposits, drug-induced conjunctival hyperemia, ocular surface staining, or other adverse changes were noted related to the use of topical tacrolimus.

Discussion

Our results showed that 0.02% topical tacrolimus ointment is highly effective in alleviating refractory ocular surface inflammatory diseases. The mechanism of action of tacrolimus is mainly as a competitive blocker of calcineurin, which is required for NFAT (nuclear factor of activated T-cells)-dependent T-cell activation or induction of inflammatory cytokine arrays.¹¹ This is similar to its predecessor, cyclosporine, which had also been isolated from soil fungus decades before.¹² However, the potency of tacrolimus is 30 times greater than that of cyclosporine in terms of its inhibitory effects (median inhibitory concentration) on calcineurin phosphatase activity.¹³ The immune suppressive effects of tacrolimus are not limited to T-lymphocytes, because the NFAT-dependent activation cascade also acts on B-cells and mast cells.^{14,15} Thus, tacrolimus should have therapeutic effects for other immune-mediated ocular diseases.

When tacrolimus is used systemically, the side effects include renal toxicity, hyperglycemia, and hypertension.¹⁶ Because of the limited amounts of tacrolimus applied as a topical medication, it should not induce these systemic side effects. Topical tacrolimus ointment is approved for treating

Table 2. Summary of Patients with Allergic Keratoconjunctivitis Treated with Topical Tacrolimus

Case	Characteristics before Tacrolimus Treatment	Clinical Score before Tacrolimus Treatment (Right Eye/Left Eye)	Clinical Score after Tacrolimus Treatment (Right Eye/Left Eye)
5	Persistent diffuse punctate epitheliokeratopathy with giant papilla	3/3	2/2
6	Shield ulcer with stromal scarring	3	0
7	Shield ulcer with stromal scarring	4/2	2/1
8	Giant papilla	3/2	2/1
9	Giant papilla	2/2	2/2
10	Shield ulcer with stromal scarring	2/2	0/0
	Mean	2.5 ± 0.2	1.3 ± 0.3

The mean clinical score was significantly reduced after tacrolimus treatment ($P < 0.05$, Wilcoxon signed rank test).

atopic dermatitis and is highly efficacious for severe dermatitis lesions.³ Because more potent topical steroid ointment may be replaced by tacrolimus ointment without worsening the therapeutic outcome, the potency of tacrolimus appears equivalent to that of betamethasone or dexamethasone.³ However, we believe that steroid therapy may also be required when topical tacrolimus is initiated. Considering molecular mechanisms, steroids have more diverse effects than calcineurin inhibitors. This may account for its efficacy in severe cases such as case 1.

Because of the potent anti-inflammatory effects of topical tacrolimus for allergic skin reactions, topical tacrolimus was believed to be efficacious for severe allergic eye diseases.^{5,8,17,18} Earlier, tacrolimus eyedrops had been occasionally used as an in-hospital prescription,¹⁹ and it was evaluated by Fujisawa Healthcare in clinical trials for vernal keratoconjunctivitis. Our hospital participated in phases II and III of the clinical trials, and our observations showed that tacrolimus had a potent therapeutic effect on vernal keratoconjunctivitis without significant side effects (unpublished observation). This prompted us to develop a long-lasting topical formulation of tacrolimus. Earlier studies showed that the 0.03% tacrolimus used for dermatological diseases had good results for eyelid diseases.^{4,17,20} Thus, Joseph et al reported that instillation of a dermatological formulation of 0.03% tacrolimus ointment onto the eye was effective in treating blepharoconjunctivitis and atopic keratoconjunctivitis.⁵ However, this formulation was not suitable for long-term ocular use.

Tacrolimus eyedrops (0.06%) were evaluated as a prophylactic agent for normal-risk penetrating keratoplasty¹⁹; however, topical tacrolimus had not yet been reported for the treatment of immune-mediated corneal diseases or scleritis, except for cases with eyelid involvement. Our initial patient with severe peripheral keratitis with impending cornea perforation (case 1) was a steroid responder with contraindications for systemic steroids or immune suppressants. Thus, we attempted topical tacrolimus ointment. The outcome was remarkably efficacious, and tectonic regrafting was avoided. This effect was independent of the possible effect of ofloxacin ointment, because adjunctive therapy using ofloxacin ointment simply switched to tacrolimus ointment. This remarkable outcome prompted us to consider topical tacrolimus as an alternative agent when systemic steroid is indicated. Thereafter, topical tacrolimus was used for scleroperikeratitis and severe atopic keratoconjunctivitis with very good results.

The beneficial effects of topical tacrolimus ointment appear relatively well sustained, and when signs and symptoms were completely resolved, patients with atopic keratoconjunctivitis switched to intermittent (e.g., once a week or month) use of topical tacrolimus ointment. The patients were able to judge the frequency of the treatment, and the intermittent treatment appeared to be effective in blocking relapses. These observations are similar to those reported by patients for the control of dermatitis lesions of atopy.³ The relatively sustained effects seem independent of the systemic effects of tacrolimus. We did not detect tacrolimus in the serum (case 1) during topical application of tacrolimus. Indeed, systemic uptake of tacrolimus is detected only when

it was applied to a larger body surface area.²¹ However, there still remains the possibility that the absorption kinetics of the ocular surface may differ from that of the skin. To assess the systemic safety on our formulation, careful analysis of local pharmacokinetics will be required.

Side effects of topical tacrolimus have been reported in the dermatological literature to be a transient burning sensation and recurrent herpetic lesions.²¹ Our patients also reported a burning sensation in the treated eyes; however, this was transient and tolerable. For the possible association with herpetic keratitis, topical tacrolimus eyedrops were shown associated with its recurrence.⁵ In our series, we did not observe herpetic keratitis (some cases were tested for presence of herpes simplex virus genome by real-time polymerase chain reaction when suspected); however, caution must be taken for possible association with herpetic keratitis as a complication.

In summary, we have described 10 patients with inflammatory ocular surface diseases that were treated with topical tacrolimus ointment. Tacrolimus was especially efficacious for peripheral ulcerative keratitis and atopic keratoconjunctivitis. The treatment was well tolerated for long periods without adverse effects and elevation of IOP. Additional studies are necessary to determine the optimal dose and therapeutic regimen for inflammatory ocular surface diseases. We believe that topical tacrolimus ointment is an efficacious alternative for ocular surface inflammatory disorders, especially when the use of systemic steroid or immune suppressant is contraindicated.

“Appendix” (available at <http://aaojournal.org>) contains 3 representative case histories (cases 1, 2, and 5).

References

1. Kino T, Hatanaka H, Hashimoto M, et al. FK-506, a novel immunosuppressant isolated from a *Streptomyces*. I. Fermentation, isolation, and physico-chemical and biological characteristics. *J Antibiot (Tokyo)* 1987;40:1249–55.
2. McAlister VC, Haddad E, Renouf E, et al. Cyclosporin versus tacrolimus as primary immunosuppressant after liver transplantation: a meta-analysis. *Am J Transplant* 2006;6:1578–85.
3. Nakagawa H. Comparison of the efficacy and safety of 0.1% tacrolimus ointment with topical corticosteroids in adult patients with atopic dermatitis: review of randomised, double-blind clinical studies conducted in Japan. *Clin Drug Investig* 2006;26:235–46.
4. Kymionis GD, Tsilimbaris MK, Iliaki OE, et al. Treatment of atopic eyelid disease using topical tacrolimus following corticosteroid discontinuation in a patient with open-angle glaucoma. *Cornea* 2004;23:828–30.
5. Joseph MA, Kaufman HE, Insler M. Topical tacrolimus ointment for treatment of refractory anterior segment inflammatory disorders. *Cornea* 2005;24:417–20.
6. Michel JL, Gain P. Topical tacrolimus treatment for ocular cicatricial pemphigoid [in French]. *Ann Dermatol Venereol* 2006;133:161–4.
7. Cheng AC, Yuen K, Chan W. Topical tacrolimus ointment for treatment of refractory anterior segment inflammatory disorders [letter]. *Cornea* 2006;25:634.
8. Virtanen HM, Reitamo S, Kari M, Kari O. Effect of 0.03% tacrolimus ointment on conjunctival cytology in patients with

- severe atopic blepharoconjunctivitis: a retrospective study. *Acta Ophthalmol Scand* 2006;84:693–5.
9. Fei WL, Chen JQ, Zhong SL, et al. The pharmacokinetics of FK506 and its nanoparticles in aqueous humor of rabbits [in Chinese]. *Zhonghua Yan Ke Za Zhi* 2006;42:305–8.
 10. Tanaka M, Dogru M, Takano Y, et al. The relation of conjunctival and corneal findings in severe ocular allergies. *Cornea* 2004;23:464–7.
 11. Martinez-Martinez S, Redondo JM. Inhibitors of the calcineurin/NFAT pathway. *Curr Med Chem* 2004;11:997–1007.
 12. Borel JF, Feurer C, Gubler HU, Stahelin H. Biological effects of cyclosporin A: a new antilymphocytic agent. *Agents Actions* 1976;6:468–75.
 13. Schwaninger M, Blume R, Oetjen E, Knepel W. The immunosuppressive drugs cyclosporin A and FK506 inhibit calcineurin phosphatase activity and gene transcription mediated through the cAMP-responsive element in a nonimmune cell line. *Naunyn Schmiedebergs Arch Pharmacol* 1993;348:541–5.
 14. Glynne R, Akkaraju S, Healy JJ, et al. How self-tolerance and the immunosuppressive drug FK506 prevent B-cell mitogenesis. *Nature* 2000;403:672–6.
 15. Harrison CA, Bastan R, Peirce MJ, et al. Role of calcineurin in the regulation of human lung mast cell and basophil function by cyclosporine and FK506. *Br J Pharmacol* 2007;150:509–18.
 16. Haddad EM, McAlister VC, Renouf E, et al. Cyclosporin versus tacrolimus for liver transplanted patients. *Cochrane Database Syst Rev* 2006;(4):CD005161.
 17. Rikkers SM, Holland GN, Drayton GE, et al. Topical tacrolimus treatment of atopic eyelid disease. *Am J Ophthalmol* 2003;135:297–302.
 18. Vichyanond P, Tantimongkolsuk C, Dumrongkigchaiporn P, et al. Vernal keratoconjunctivitis: result of a novel therapy with 0.1% topical ophthalmic FK-506 ointment. *J Allergy Clin Immunol* 2004;113:355–8.
 19. Reinhard T, Mayweg S, Reis A, Sundmacher R. Topical FK506 as immunoprophylaxis after allogeneic penetrating normal-risk keratoplasty: a randomized clinical pilot study. *Transpl Int* 2005;18:193–7.
 20. Mayer K, Reinhard T, Reis A, et al. FK 506 ointment 0.1%—a new therapeutic option for atopic blepharitis: clinical trial with 14 patients [in German]. *Klin Monatsbl Augenheilkd* 2001;218:733–6.
 21. Soter NA, Fleischer AB Jr, Webster GF, et al. Tacrolimus ointment for the treatment of atopic dermatitis in adult patients: part II, safety. *J Am Acad Dermatol* 2001;44(suppl):S39–46.

Appendix: 3 Representative Case Histories (Cases 1, 2, and 5)

Case 1

A 42-year-old man with a corneal perforation caused by peripheral ulcerative keratitis was referred to our hospital for emergency care. The inferonasal peripheral cornea of his left eye was perforated by stromal melting, and the iris was incarcerated in the wound. The AC was shallow, with infiltrates. His history included cerebral palsy at birth, but no sign of autoimmune inflammatory disease was detected. His best-corrected visual acuity (BCVA) was 20/200 in the affected eye. A therapeutic soft contact lens with topical betamethasone and antibiotics (ofloxacin ointment) was begun; however, the AC depth (ACD) did not recover. This led us to perform tectonic lamellar keratoplasty. The ACD recovered and was maintained with topical betamethasone and systemic betamethasone (1 mg/day).

Despite the intensive treatment, corneal infiltrations recurred in the original affected area, and the grafted tissue developed ulcerative infiltrates and began to thin. Systemic steroids and systemic immune suppressant were not indicated because of poorly controlled diabetes and hepatic dysfunction, respectively.

To alleviate the inflammatory responses, amniotic membrane transplantation was performed 3 months after lamellar keratoplasty; however, the transplanted amniotic membrane began to melt, and gradual thinning still developed. Topical betamethasone and subconjunctival injections of dexamethasone (non-depo-steroid, 2–3 times a week) were performed. This partially decreased the degree of infiltration; however, IOP increased to 41 mmHg. Oral acetazolamide and topical carteolol were given to try to control the IOP, but it remained at 38 mmHg. This led us to reduce the subconjunctival injections to once a week. This treatment was not sufficient to suppress the inflammatory responses, and a thinning of the graft began to extend deep into the stroma (Fig 2A). A cumulative therapeutic effect of dexamethasone injections was not detected, and it was discontinued to avoid further increase in IOP. The BCVA at this time was 20/200.

Because the patient did not consent to surgical replacement of the tectonic graft, topical tacrolimus treatment was initiated, with continued use of topical betamethasone (6 times a day). After a few days of treatment, the patient had a substantial improvement in his symptoms, and the ulcerative infiltrates and conjunctival hyperemia began to resolve. The corneal epithelium began to grow and cover the affected area, leaving only superficial punctate staining. The topical betamethasone was tapered and switched to fluorometholon 1 month after topical tacrolimus use. The elevated IOP was reduced to 12 mmHg without oral acetazolamide or topical aqueous suppressant. Other medications were also tapered, and the inflammatory responses were well controlled over 26 months with continued topical tacrolimus ointment and 0.1% fluorometholon, twice daily. Thereafter, occasional mild conjunctival hyperemia was seen surround-

ing the grafted corneal lesion (Fig 2B), with visual acuity (VA) maintained at 20/50.

Case 2

A 75-year-old man with bilateral Mooren's ulcer and open-angle glaucoma had a 5-year history of frequent relapsing episodes of undermining ulcerative keratitis of the superotemporal rim of the left eye or superonasal rim of the right eye. Despite the continuous use of topical 0.1% betamethasone and prednisolone ointment, the peripheral ulcer gradually expanded, with frequent inflammatory episodes. When active thinning and uncontrolled limbal inflammatory responses developed (Fig 3A), a resection of the affected limbal conjunctiva (Brown's operation) and keratoepithelioplasty, previously reported by Kinoshita et al,^{*} were performed on both eyes. The surgery was followed by continued topical 0.1% betamethasone and 0.05% cyclosporine, which reduced the inflammatory response. However, occasional relapses were still observed, with gradual thinning of the peripheral cornea. With a combination of topical carteolol and dorzolamide, twice daily, the IOP ranged from 19 to 30 mmHg in both eyes, and the vertical cup-to-disc (C/D) ratio was 0.9 to 1.0. Under this therapeutic regimen, there was severe VF loss (Aulhorn stage V) in both eyes, and spontaneous relapses of the peripheral ulcerative inflammatory responses were still observed, with gradual corneal thinning (Fig 3B). Attempts to reduce the IOP by adjunctive topical latanoprost were made; however, the interval of the relapses shortened, and therefore, the treatment regimen was discontinued.

Topical 0.1% betamethasone and cyclosporine were not sufficient to suppress inflammatory relapse and peripheral thinning. In addition, IOP was not controlled by the topical aqueous suppressants. Therefore, topical tacrolimus was initiated twice a day when a marginal ulcer recurred in the upper rim of his left eye, and he was being considered for surgical intervention. After 2 weeks of treatment, there was a marked improvement in the undermining ulcer and inflammatory responses, as well as markedly reduced IOP after cessation of steroid therapy. When the glaucoma medications were discontinued to reduce the undesirable epithelial toxicity or inflammatory responses, his IOPs were maintained at 19 mmHg (right eye) and 15 mmHg (left eye) without glaucoma medication. Relapses did not develop during the 18 months with continued topical tacrolimus once a day. Because of a gradual development of a preexisting senile cataract, cataract surgery was performed in the left eye through the unaffected corneal rim (6-o'clock) under the cover of topical tacrolimus. Again, no relapse was observed during the 6-month postoperative period (Fig 3D).

Case 5

A 37-year-old man, with atopic skin disease and steroid-induced open-angle glaucoma, presented with an 8-year history of eyelid and ocular surface disorders. The disorders included persistent diffuse punctate epitheliokeratopathy and giant papilla formation caused by severe atopic blepharoconjunctivitis in both eyes. Because of the uncontrolled IOP, trabeculotomy had been performed on his left eye 4

months before his referral to Tottori University hospital. He had been treated with preservative-free topical sodium cromoglicate, 0.3% hyaluronate sodium, and oral acetazolamide without noticeable resolution of the diffuse punctate epitheliopathy and severe photophobia. His VAs were 20/25 (right eye) and 20/200 (left eye), and his IOP was 20 mmHg in both eyes with oral acetazolamide. Vertical C/D ratios were 0.7 (right eye) and 0.8 (left eye), with a VF defect in his left eye (Aulhorn stages I–II). Preservative-free topical cyclosporine was initiated; however, no noticeable response was observed, and whirling epithelial migratory responses were still observed.

In an attempt to suppress the atopic inflammatory responses, topical tacrolimus was prescribed twice daily on his right eye. Because there was marked improvement in his symptoms and the epithelial defect in the right eye within 2

weeks, the treatment was continued on both eyes. The persistent epitheliopathy gradually resolved over 2 weeks, and topical cyclosporine was discontinued. With continued use of topical tacrolimus twice daily, the keratoepitheliopathy became localized and sparse, with marked reduction of an edematous giant papilla in the upper eyelid. His vision improved to 20/15 (right eye) and 20/25 (left eye) at his last visit. Intraocular pressures were significantly reduced to 11 mmHg (right eye) and 10 mmHg (left eye).

Reference

- * Kinoshita S, Ohashi Y, Ohji M, Manabe R. Long-term results of keratoepithelioplasty in Mooren's ulcer. *Ophthalmology* 1991;98:438–45.

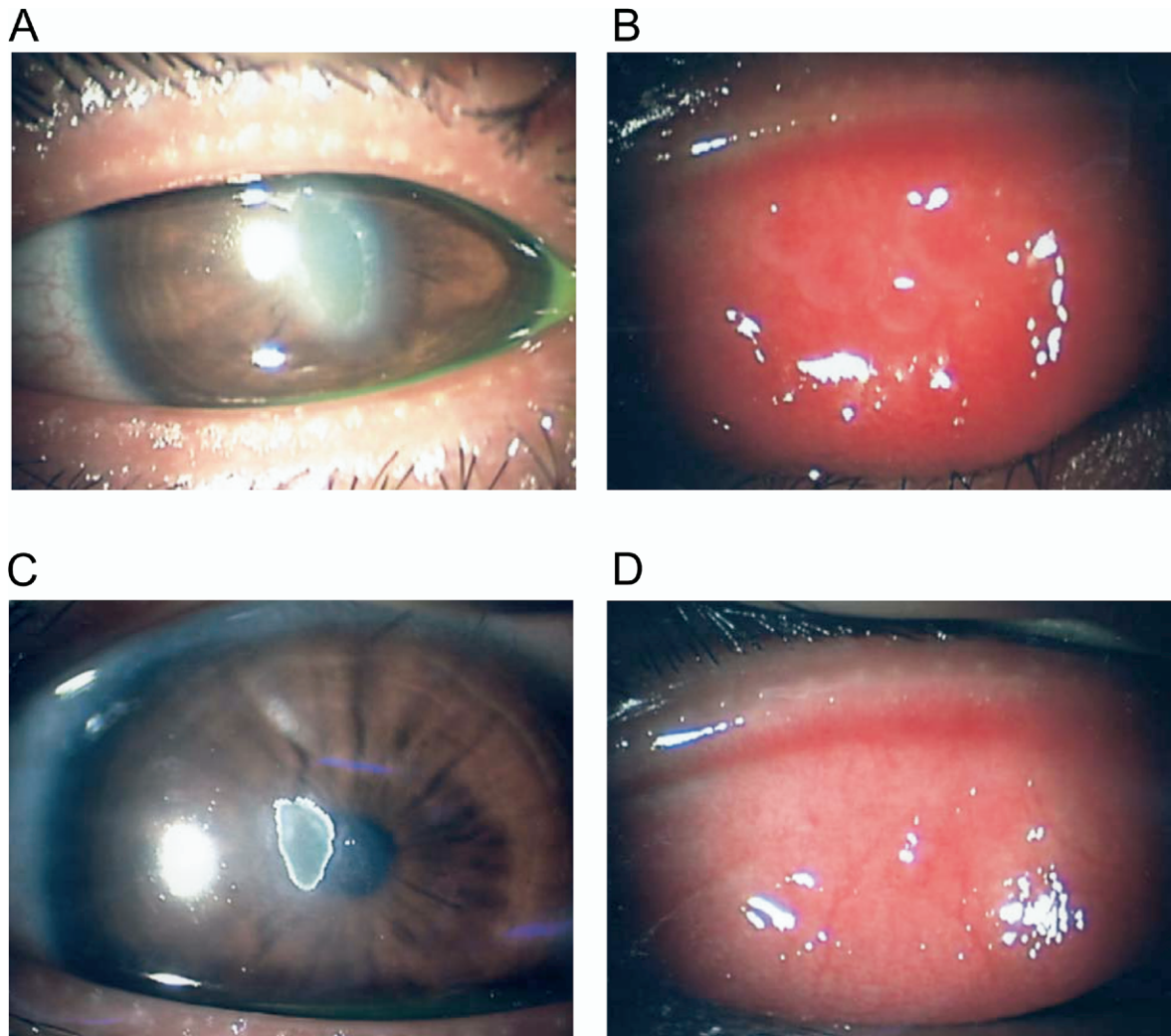


Figure 1. Effect of topical tacrolimus on case 7. Before topical tacrolimus treatment, showing shield ulcer (A) and giant papilla formation in the patient's right eye (B). After topical tacrolimus treatment, showing resolved shield ulcer and remaining epithelial plaque (C) and markedly reduced papilla and conjunctival edema (D).

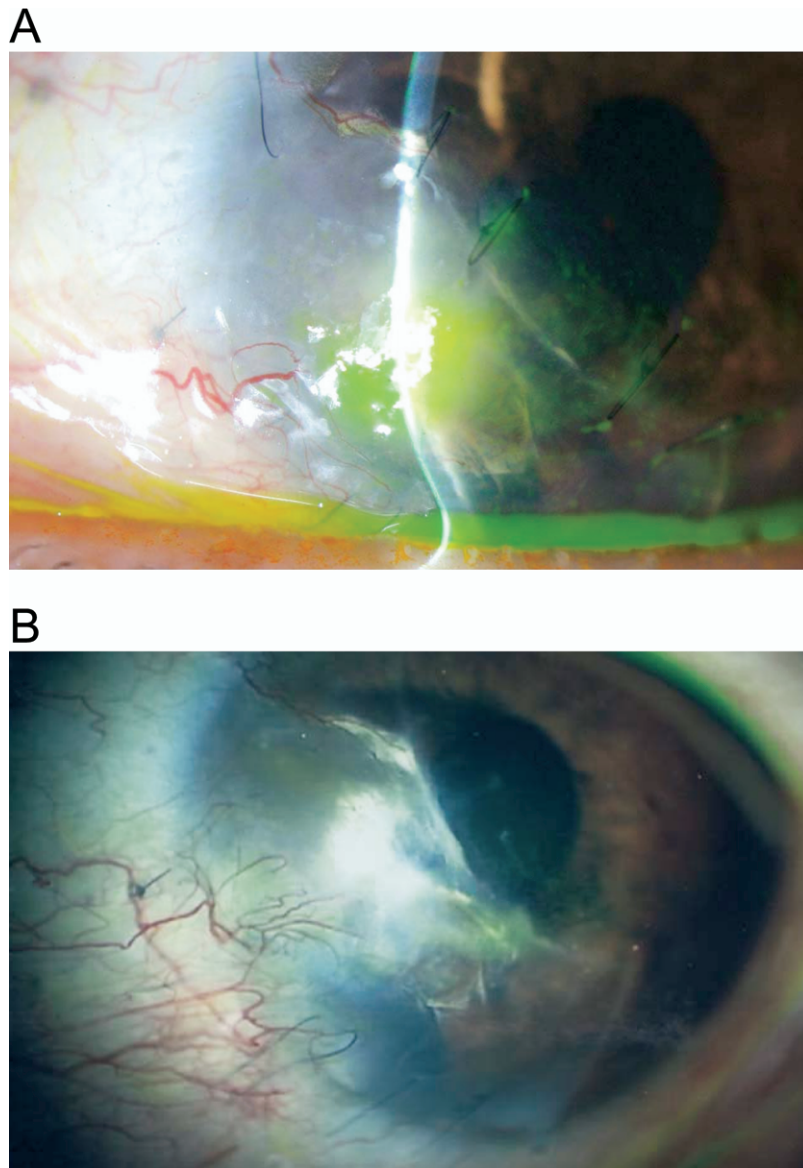


Figure 2. Effect of topical tacrolimus on a case of corneal perforation caused by peripheral ulcerative keratitis (case 1). **A,** Left eye before topical tacrolimus treatment. Ulcerative thinning of the graft deep into the stroma can be seen. **B,** Four months after topical tacrolimus treatment, showing a resolution of the ocular surface inflammatory response.

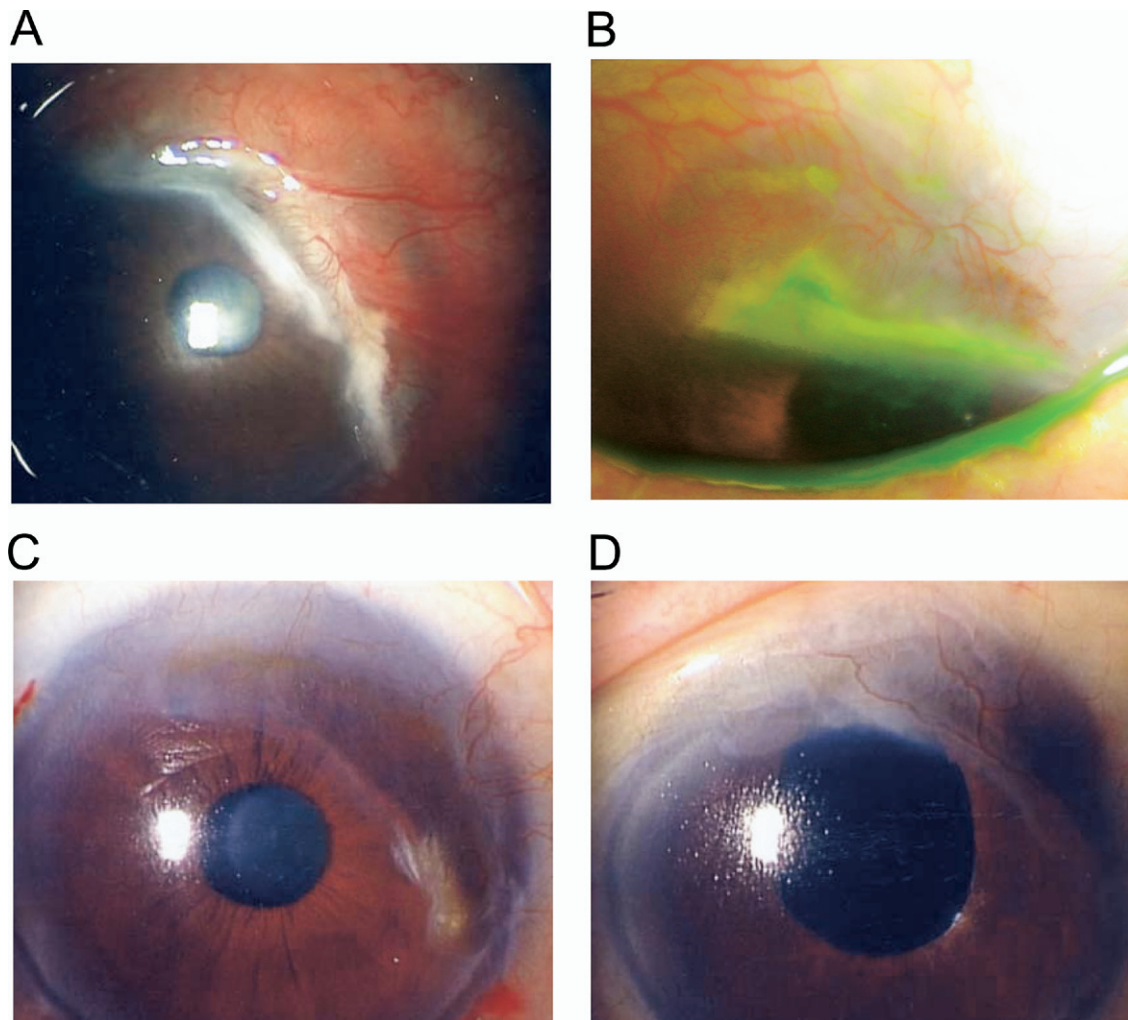


Figure 3. Effect of topical tacrolimus on a Mooren's ulcer in a case of ulcerative keratitis (case 2). **A**, Right eye before conjunctival resection and keratoepithelioplasty, showing severe undermining ulcerative responses. **B**, Left eye, showing an episode of undermining ulcerative responses in the upper rim after surgical intervention. **C**, Right eye, 2 years after the start of topical tacrolimus treatment. **D**, Left eye, 6 months after cataract surgery, showing maintained resolution of undermining ulcerative responses.