

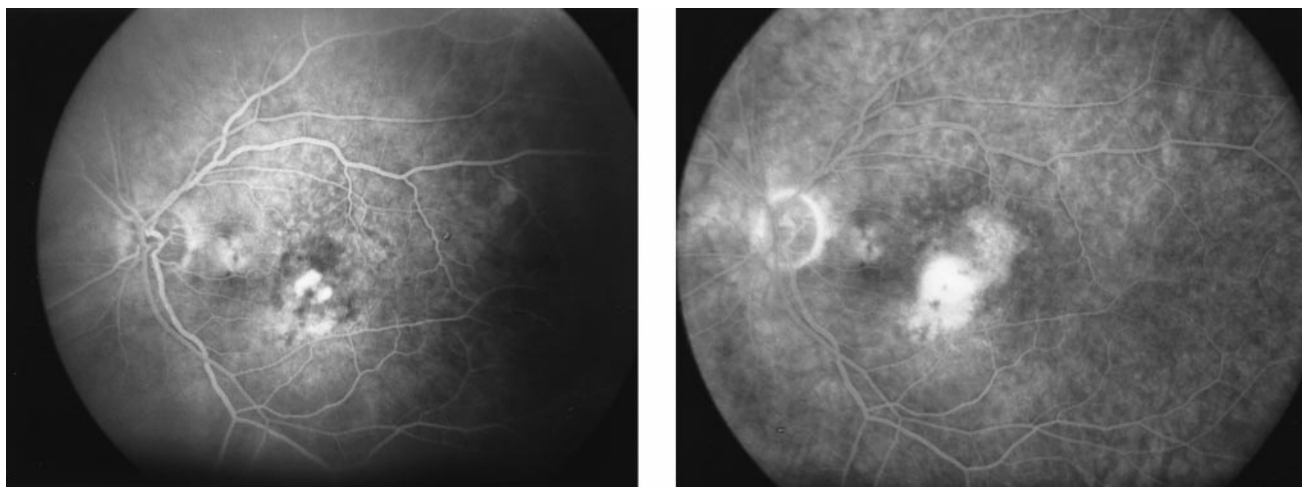FIGURE 1. Case 4. (Left) Fluorescein angiogram of right fundus shows early fluorescence of choroidal neovascular membrane. (Right) Late angiogram. Good agreement existed among observers that this was a mixed classic-occult neovascular membrane (kappa coefficient .76), but 33.3% of observers estimated its size as greater than two disk areas and 42.8% estimated between one and two disk areas (kappa coefficient = .00).

interpretation of fluorescein angiography, however, is just one of several factors that goes into determining prognosis and in making therapeutic decisions.

The results of this study indicate that reasonably good interobserver consistency exists among specialists in classifying choroidal neovascular membranes according to type, but in some cases, interpretation can vary considerably. Greater interobserver variability exists in estimating membrane area than in type. The assessment of certain angiographic features of choroidal neovascular membranes may become even more important with the development of photodynamic therapy because beneficial treatment has been limited to choroidal neovascular membranes having a predominately classic angiographic pattern.<sup>5</sup>

#### REFERENCES

1. Macular Photocoagulation Study Group. Subfoveal neovascular lesions in age-related macular degeneration. Guidelines for evaluation and treatment in the Macular Photocoagulation Study. *Arch Ophthalmol* 1991;109:1242–1257.
2. Macular Photocoagulation Study Group. Occult choroidal neovascularization. Influence on visual outcome in patients with age-related macular degeneration. *Arch Ophthalmol* 1996;114:400–412.
3. Macular Photocoagulation Study Group. Laser photocoagulation of subfoveal neovascular lesions of age-related macular degeneration; updated findings from two clinical trials. *Arch Ophthalmol* 1993;111:1200–1209.
4. Macular Photocoagulation Study Group. Visual outcome after laser photocoagulation for subfoveal choroidal neovascularization secondary to age-related macular degeneration; the influence of initial lesion size and initial visual acuity. *Arch Ophthalmol* 1994;112:480–488.
5. Treatment of Age-related Macular Degeneration with Photodynamic Therapy (TAP) Study Group. Photodynamic therapy of subfoveal choroidal neovascularization in age-related mac-

ular degeneration with verteporfin. *Arch Ophthalmol* 1999; 117:1329–1345.

## Caterpillar Setae–Induced Acute Anterior Uveitis: A Case Report

John Conrath, MD, Eve Hadjadj, MD, Bertrand Balansard, MD, and Bernard Ridings, MD

**PURPOSE:** To report uveitis secondary to ocular penetration of caterpillar hairs (setae).

**METHODS:** Case report. A documented attack of acute anterior uveitis was caused by initially overlooked penetration of caterpillar setae.

**RESULTS:** A 66-year-old man presenting with unilateral hypertensive keratouveitis was treated with antiherpes simplex medication (along with local anti-inflammatory and cycloplegic agents) after anterior chamber paracentesis and serologic testing. Laboratory testing was negative. Resolution occurred after 5 days, and corneal clearing showed a predescemetic caterpillar seta.

**CONCLUSION:** Patient history taken in an anterior uveitis setting should include gardening habits and searching for possible exposure to insects or arachnids. (*Am J Ophthalmol* 2000;130:841–843. © 2000 by Elsevier Science Inc. All rights reserved.)

Accepted for publication June 20, 2000.

From the Ophthalmology Department, Timone Hospital, Marseille, France.

Inquiries to John Conrath, MD, Ophthalmology Department, Timone Hospital, 264 Rue Saint Pierre, F-13385, Cedex 05 Marseille, France; fax: 33-491385033; e-mail: jconrath@pacwan.fr

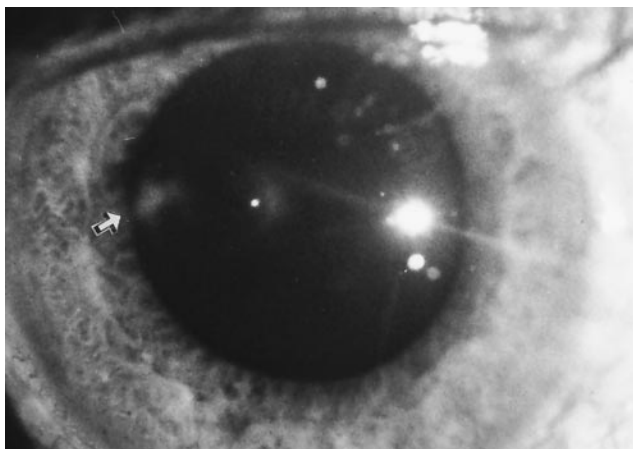


FIGURE 1. Slit-lamp photograph of left eye at day 3 shows ciliary injection. Corneal infiltrate (arrow) visible on nasal aspect of midperipheral cornea.



FIGURE 2. Slit-lamp photograph of left eye at day 5 shows seta (arrow) deeply embedded in the cornea. Inflammation has subsided.

A 66-YEAR-OLD PATIENT WAS REFERRED BY A GENERAL ophthalmologist to the university hospital eye clinic for management of acute anterior uveitis of the left eye. Symptoms started 4 days earlier. Two days before presentation, visual acuity markedly decreased and pain and redness appeared. Ophthalmic examination showed a visual acuity of RE: 20/20 and LE: 20/80. Slit-lamp examination of the left eye showed conjunctival hyperemia and diffuse corneal edema more prominent on the nasal aspect with a mild fluorescein staining. Anterior chamber examination showed moderately severe (3+) flare with prepupillary fibrin and moderate (2+) cells. Relative miosis without synechiae and a clear lens were observed. Intraocular pressure was RE: 13 mm Hg and LE: 25 mm Hg. Fundus examination of the left eye evidenced neither vitreous cells nor chorioretinal abnormality.

The patient was hospitalized for laboratory tests. Red and white blood cell counts were unremarkable, and erythrocyte sedimentation, fibrin, and C-reactive protein were normal. Chest x-ray, tuberculin skin testing, and human leukocyte antigen typing were performed, as well as anterior chamber paracentesis (with herpes simplex and zoster and toxoplasma titers), blood titers of antinuclear antibodies, herpes simplex, zoster, cytomegalovirus, Epstein-Barr virus, toxoplasma antibodies, and a Venereal Diseases Research Laboratories test. All were negative. Intravenous acyclovir (500 mg  $\times$  3/day) was started as well as local treatment with acyclovir pomade 5 times daily, dexamethasone-gentamicin drops 5 times daily, and atropine drops 2 times daily.

Improvement was marked after 3 days of treatment (Figure 1), and at day 5, careful slit-lamp examination after corneal clearing showed a single microscopic filament deeply embedded in the corneal stroma (Figure 2). When asked if he had encountered caterpillars in the previous days, the patient answered positively, saying that he had

done gardening in a pine grove to remove pine processionary caterpillars 12 days before hospitalization, not remarking any ocular foreign bodies at the time.

Ocular inflammation secondary to penetration of caterpillar setae has been classified by Cadera and associates<sup>1</sup> into 5 types, the later 2 pertaining to intraocular inflammation (type 4, iritis and type 5, vitreoretinal involvement). Pathophysiology of inflammation is assumed to be both partially mechanical<sup>2</sup> (progression caused by distal end-oriented barbs on each hair) and partly toxic<sup>3</sup> (thaumetopoein secreted from the venom gland connected to the hair shaft). Intraocular inflammation is observed when the seta penetrates inside the eye. In this case, the particularity was the absence of visible setae on initial examination, masked by corneal stromal edema. We may have removed aqueous setae or toxin at paracentesis, unknowingly. Follow-up is now 12 months, and the patient has showed no further inflammation. The sole seta observed at day 5 has not moved since, becoming somewhat translucent and remaining visible in a predesmetic position.

In cases of prolonged intraocular inflammation, acute endophthalmitis, or vitritis, vitrectomy has been successful.<sup>2,4,5</sup> The clinical course of ophthalmia nodosa is variable, and this diagnosis should always be considered when evaluating patients presenting with ocular inflammation, especially in a region endemic for caterpillars.

#### REFERENCES

1. Cadera W, Pachtman MA, Fountain JA, Ellis FD, Wilson FM. Ocular lesions caused by caterpillar hairs (ophthalmia nodosa). *Can J Ophthalmol* 1984;19:40-44.
2. D'Hermies F, Parent de Curzon H, Mathieu L, Furia M, Campinchi R. Les chorioretinopathies par migration de poil de chenille. *J Fr Ophtalmol* 1985;8:471-478.
3. Lamy M, Pastureaud MH, Novak F, et al. Thaumetopoein: an urticating protein from the hairs and integument of the pine

processionary caterpillar (*Thaumetopoea pityocampa* Schiff). *Toxicon* 1986;24:347–356.

- Fraser SG, Dowd TC, Bosanquet RC. Intraocular caterpillar hairs (setae): clinical course and management. *Eye* 1994;8: 596–598.
- Shibui H, Kawashima H, Kamata K, et al. Vitrectomy for caterpillar seta-induced endophthalmitis. *Arch Ophthalmol* 1997;115:555–556.

## Tubercular Endophthalmitis Simulating Retinoblastoma

Usha K. Raina, MD, FRCS, FRCOphth,  
Deven Tuli, MS, Ritu Arora, MD,  
Dinesh K. Mehta, MS, MNAMS, and  
Mukesh Taneja, DO, DNB

**PURPOSE:** To report a case of tubercular endophthalmitis simulating retinoblastoma.

**METHODS:** Case report. An 8-year-old female presented with a history of complete loss of vision and a white pupillary reflex in the left eye of 3 month's duration.

**RESULTS:** Retinoblastoma could not be excluded on the basis of clinical examination and relevant investigational studies. In the left eye, a computed tomography (CT) scan demonstrated a large vitreous mass with foci of calcification. Enucleation in the left eye was performed, and histopathological examination revealed a chronic granulomatous endophthalmitis and acid-fast bacilli consistent with tubercular pathology.

**CONCLUSION:** This case illustrates that tubercular endophthalmitis with leukocoria and a vitreous mass containing focal calcification may simulate retinoblastoma. (*Am J Ophthalmol* 2000;130:843–845. © 2000 by Elsevier Science Inc. All rights reserved.)

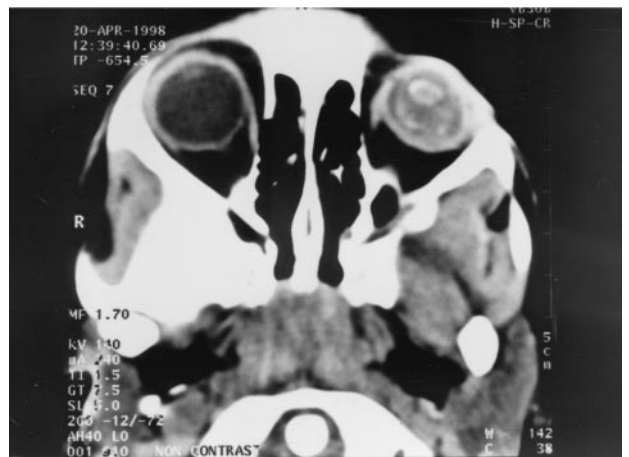
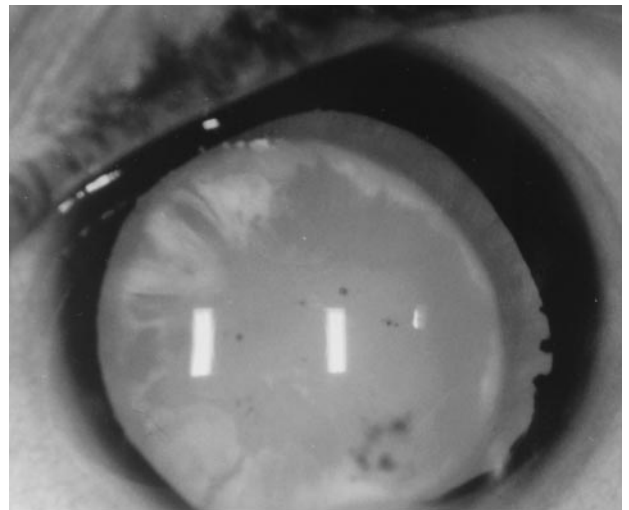
**O**CULAR CONDITIONS OTHER THAN RETINOBLASTOMA that present with leukocoria are collectively referred to as pseudoretinoblastoma. In most situations, it is possible, based on clinical examination and relevant investigations, to pinpoint the exact cause of leukocoria and institute the appropriate treatment. But in cases in which the diagnosis of retinoblastoma cannot be ruled out, it is best to proceed with excision of the eyeball and seek a histopathological diagnosis. This is particularly justified if the eye is painful and without useful vision.<sup>1</sup>

• **CASE:** An 8-year-old female reported to the Pediatric Ophthalmology Service with complaints of loss of vision in the left eye associated with a white pupillary reflex for 3

Accepted for publication June 29, 2000.

From the Guru Nanak Eye Center, Maulana Azad Medical College, New Delhi, India.

Inquiries to Usha K. Raina, MD, FRCS, FRCOphth, 427 Hawa Singh Block, Asiad Village Complex, New Delhi 110049, India; fax: 91-11-6855408; e-mail: vraina@vsnl.com



**FIGURE 1.** (Top) Photograph shows the mass in the vitreous seen behind the subluxated and cataractous lens. Surface vessels over the mass are evident. (Bottom) Axial computed tomography scan reveals calcification in the mass.

months. Perception of light was absent in the affected left eye, and the right eye was essentially normal. Examination of the left eye revealed clear cornea with leukocoria. Cells or keratic precipitates (KPs) were not observed in the anterior chamber. The pupil was dilated and nonreactive to light. The iris showed rubeosis and diffuse iris atrophy. The lens showed cataractous changes and was subluxated. Retrolental space revealed a whitish mass occupying the entire vitreous cavity with surface vascularization (Figure 1, top). No other fundus details could be visualized. The intraocular pressure was RE: 20 mm Hg and LE: 14 mm Hg.

No history of trauma existed. At the onset of decreased vision in the left eye, the patient had mild redness and pain in the affected eye but no eyelid edema. The child had been seen by a pediatrician and found to have no foci of systemic infection.

Complete blood count and x-rays of the chest and paranasal sinuses revealed no abnormality. The patient had received a course of topical and systemic antibiotics