

# Management and Outcome of Microbial Anterior Scleritis

Matthew A. Cunningham, MD, Jamie K. Alexander, BA, Alice Y. Matoba, MD,  
Dan B. Jones, MD, and Kirk R. Wilhemus, MD, PhD

**Purpose:** To evaluate the prevalence, predisposing factors, and outcomes of bacterial and fungal scleritis.

**Methods:** We reviewed the clinical findings, therapeutic interventions, and visual outcomes of patients with suppurative scleral inflammation without preceding microbial keratitis who had microorganisms isolated from scleral scrapings.

**Design:** Retrospective interventional case series.

**Results:** Of 349 patients with scleritis diagnosed from 1999 to 2009, 6 adults (1.7%) presented with suppurative inflammation of the anterior sclera due to *Pseudomonas aeruginosa* (2), *Streptococcus pneumoniae* (2), *Staphylococcus aureus* (1), and *Scedosporium apiospermum/Pseudallescheria boydii* (1). Each had ocular surgery of the affected eye before presentation. Intraocular extension occurred in 2 eyes. After local and systemic antimicrobial therapy, all improved without evisceration or enucleation, and 4 attained vision of 20/60 or better.

**Conclusions:** Bacterial or fungal scleritis is an uncommon ocular infection that can belatedly follow anterior segment procedures. Antimicrobial therapy and surgical intervention can successfully control progressive suppuration and reduce vision-limiting complications.

**Key Words:** infection, microbial scleritis, ocular microbiology, scleral graft

(*Cornea* 2011;30:1020–1023)

Scleritis is an ocular manifestation of an immune-mediated process. Reactive scleral inflammation occasionally arises during the course of infectious diseases such as syphilis, tuberculosis, and zoster.<sup>1</sup> Bacterial or fungal invasion into the sclera is uncommon, accounting for less than 1% of all eye infections.<sup>2</sup> Scleral infection can develop during progressive

microbial keratitis or panophthalmitis<sup>3,4</sup> and has rarely occurred in the absence of contiguous disease.<sup>5</sup>

Microorganisms gain a direct portal of entry into the sclera from ocular trauma or surgery. For example, infections associated with scleral buckling material or sutures present as equatorial or posterior scleral inflammation.<sup>6</sup> Focal infection of the anterior sclera also has developed after ocular surface surgery, radiotherapy, or chemical exposure, often with a delayed onset.<sup>3</sup>

Exogenous microbial scleritis presents as a suppurative nodule, abscess, or ulcer. Reported causes include pathogens that are also responsible for microbial keratitis, such as Gram-negative rods, Gram-positive cocci, and filamentous fungi.<sup>5,7</sup> Because of the relative rarity of scleral infections, we reviewed our experience with bacterial and fungal scleritis over an 11-year period to evaluate the clinical and visual outcomes with medical and surgical management.

## MATERIALS AND METHODS

The clinical records of 349 patients with anterior scleritis, as categorized by diagnostic codes (379.00, 379.03, 379.04, 379.06, or 379.09) of the International Classification of Diseases, Ninth Revision, who were treated at the Cullen Eye Institute between January 1999 and December 2009 were retrospectively reviewed after authorization by the Baylor College of Medicine Institutional Review Board. Information on patients with culture-positive infection of the anterior sclera was collected from clinical, photographic, and laboratory files. The dimensions of scleral ulceration and suppuration obtained using an eyepiece reticule were used to estimate the elliptical area of scleral inflammation. Scleral scrapings were inoculated directly onto blood, chocolate, and Sabouraud agar plates, and microbial identification was based on standard microbiological criteria. Culture positivity of scleral scrapings was defined as bacterial or fungal growth on 1 or more primary culture media. Clinical data included previous surgery of the affected eye, initial and final Snellen visual acuity, inflammatory complications during follow-up, medical management, and surgical interventions. All patients who were diagnosed with scleritis were evaluated with a full review of systems, medical history (including systemic conditions associated with scleral inflammation), and medication history. Cure was defined as resolution of ocular inflammation during antimicrobial therapy without recurrence after treatment was discontinued.

## RESULTS

An average of 32 patients were diagnosed with scleritis, either infective or immune-mediated, each year during the study period. Six patients (1.7%), 4 men and 2 women who were aged between 46 and 82 years (Table 1), had microbial infection of the anterior sclera without preceding microbial

Received for publication August 9, 2010; revision received October 24, 2010; accepted November 27, 2010.

From the Cullen Eye Institute, Department of Ophthalmology, Baylor College of Medicine, Houston, TX.

Supported by a core grant (EY02520) from the National Eye Institute and by grants from the Sid W. Richardson Foundation and Research to Prevent Blindness, Inc.

The authors have no financial conflicts/proprietary interests in any products named in this article.

Reprints: Dr. K.R. Wilhemus, Sid W. Richardson Ocular Microbiology Laboratory, Baylor College of Medicine, Department of Ophthalmology, 6565 Fannin Street, Houston, TX 77030 (e-mail: kharano@bcm.edu).

Copyright © 2011 by Lippincott Williams & Wilkins

**TABLE 1.** Case Series of Microbial Scleritis

Case/Sex/Age (yrs)/Eye	Pathogen	Previous Surgery	Location (Area, mm <sup>2</sup> )	Latent Period*	Initial Vision	Final Vision	Surgical Intervention	Complications
1/F/46/L	<i>S. pneumoniae</i>	Pterygium excision	Nasal (12.5)	4 yrs	20/40	20/20	None	Exudative retinal detachment, glaucomatous cupping
2/M/62/R	<i>S. pneumoniae</i>	Pterygium excision	Nasal (82)	1 mo	20/80	20/40	Sclerectomy	Nuclear sclerotic cataract
3/M/73/R	<i>P. aeruginosa</i>	Pterygium excision	Nasal (35.5)	30 yrs	20/30	20/60	Scleral debridement, scleral patch graft, conjunctival flap	Choroidal detachment, posterior synechiae, nuclear sclerotic cataract, transient hypotony
4/M/79/R†	<i>P. aeruginosa</i>	Conjunctival excision and radiotherapy for recurrent squamous cell carcinoma	Temporal (200)	2 yrs	LP	1/200	Amniotic membrane graft	Endophthalmitis, death because of chronic lymphocytic leukemia
5/M/82/R	<i>S. aureus</i>	Trabeculectomy	Inferior (5.5)	1 mo	20/40	20/50	None	None
6/F/71/L	<i>S. apiospermum</i>	Cataract extraction	Nasal (13.5)	1 yr	20/70	20/100	Amniotic membrane graft, conjunctival flap	Vitreitis, recrudescence scleritis, cystoid macular edema

\*Latent period is the time from surgery to symptomatic onset of scleritis.

†Patient 4 had systemic immunosuppression secondary to chronic lymphocytic leukemia. No other patients had a non-ocular medical history, review of systems, or active medication use that would predispose to secondary infection.

F, female; L, left; LP, light perception; M, male; R, right.

keratitis for more than 11 years (approximately 1 patient with microbial anterior scleritis every 1.8 years). The initial visual acuity at the time of diagnosis ranged from 20/40 to light perception. Each individual had previously undergone surgery of the affected eye, which included pterygium excision with  $\beta$ -irradiation (3), conjunctival squamous carcinoma excision with  $\beta$ -irradiation (1), trabeculectomy (1), and cataract extraction (1). Microbial isolates included *Pseudomonas aeruginosa* (2), *Streptococcus pneumoniae* (2), *Staphylococcus aureus* (1), and *Scedosporium apiospermum/Pseudallescheria boydii* (1).

Endophthalmitis, defined as intraocular inflammation with microbial recovery from aqueous or vitreous specimens, occurred in 2 patients with pseudomonal scleritis. One of these patients was treated with intravitreal antibiotics and the other was treated with subconjunctival tobramycin and systemic ciprofloxacin. One patient with fungal scleritis had vitreitis, but intraocular fluids were not examined. Other transient complications included exudative retinal detachment (1), cystoid macular edema (1), choroidal detachment (1), and hypotony (1). Of these complications, there was complete resolution of the hypotony and exudative retinal and choroidal detachments.

All patients were initially administered a combination of a topical cephalosporin and a topical aminoglycoside, fluoroquinolone, or vancomycin. Topical natamycin was begun when fungal filaments were recognized on smears of scleral scrapings. Three patients were administered subconjunctival or sub-Tenon injections of ceftazidime (2) or tobramycin (1). Five patients received oral ciprofloxacin (2), moxifloxacin (1), amoxicillin (1), or voriconazole (1). Topical prednisolone acetate 1% was added during antibacterial treatment for 4 eyes with bacterial scleritis, and 2 also received oral prednisone. Surgical interventions included lamellar sclerectomy (1), scleral patch graft (1), and amniotic membrane graft (2) with or without a conjunctival flap. Five patients had complete resolution of ocular infection, and 1

patient was improving when he developed leukemic complications and was lost to ophthalmologic follow-up. Final visual acuity ranged from 20/20 to 20/60 for 4 eyes, 20/100 for 1, and worse than 20/400 for 1 (Table 1).

## CASE REPORTS

### Case 1

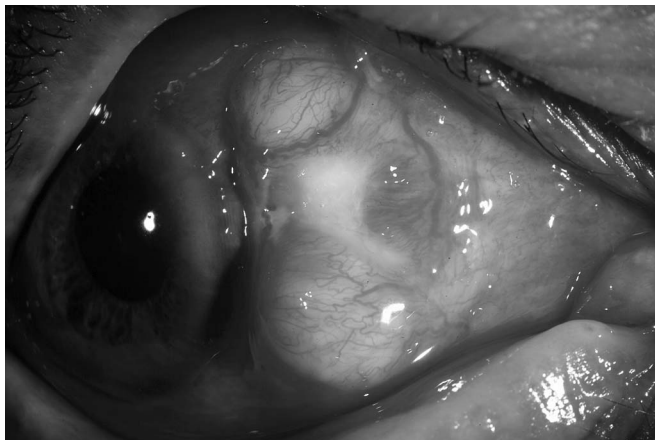A 46-year-old woman presented with necrotizing suppurative scleral ulceration, inferior exudative retinal detachment, and visual acuity of 20/40 of her left eye. She had undergone a nasal pterygium excision with  $\beta$ -irradiation 51 months previously. Initial treatment included hourly moxifloxacin 0.5%, subconjunctival ceftazidime 25 mg, oral moxifloxacin, and oral prednisone. Scleral scrapings yielded *S. pneumoniae*. Complete resolution of scleral inflammation occurred over a 10-week-period, and no surgical intervention was performed.

### Case 2

A 62-year-old man presented 1 month after excision of a nasal pterygium with severe right eye pain, purulent scleral necrosis, and adjacent scleral abscesses (Fig. 1). Initial treatment included superficial sclerectomy with subconjunctival ceftazidime 25 mg, hourly topical ceftazidime 5% and moxifloxacin 0.5%, and oral amoxicillin. Scleral scrapings yielded *S. pneumoniae*. After repeat debridement, ocular inflammation subsided, and medications were discontinued after 2 weeks of therapy.

### Case 3

A 73-year-old man presented with a painful scleral plaque and 20/30 visual acuity (Fig. 2A) 30 years after nasal pterygium excision with  $\beta$ -irradiation of the right eye. A hypopyon developed over the next week, and scleral scrapings and an anterior chamber aspirate yielded *P. aeruginosa*. Initial treatment included hourly ceftazidime 5% and ciprofloxacin 0.3%, subconjunctival tobramycin 20 mg, and twice-daily oral ciprofloxacin. A scleral patch graft with rotating conjunctival flap was subsequently performed for residual scleral thinning (Fig. 2B). Final visual acuity was 20/60.



**FIGURE 1.** Case 2. *S. pneumonia* scleritis after pterygium surgery. A large scleral nasal abscess with associated purulent material noted centrally. After sclerectomy and drainage with subconjunctival, topical, and oral antibiotics, there was complete resolution of the scleritis 14 days after initiation of the treatment.

## DISCUSSION

Microbial scleritis is an infrequent ocular infection. The prevalence of primary bacterial or fungal scleritis among patients with scleritis is estimated to be 1.7% in our cohort and in a previously reported case series.<sup>8</sup> Scleral infection can commence a few weeks after anterior segment surgery or arise decades later. Cataract extraction,<sup>9</sup> trabeculectomy,<sup>10</sup> and pars plana vitrectomy<sup>11,12</sup> have preceded infectious scleritis. However, based on our experience and recent case reports, pterygium excision seems to be the most common procedure predisposing to microbial anterior scleritis.<sup>3,13–17</sup> Although not a prerequisite for scleral infection, adjunctive use of irradiation or antimetabolites adds to the risk of scleral thinning and avascular necrosis that provide a nidus for microbial adherence.<sup>17</sup>

Specific treatment depends on the identification of microorganisms from scleral specimens. Laboratory criteria for culture-positive scleral infection have not yet been adequately defined. Because of the retrospective nature of this study and the available microbiological data, bacterial or fungal growth on 1 or more primary culture media was used to indicate culture positivity in this study. The development of rapid diagnostic assays may enable estimation of the intensity of the microbial load that could be used to guide treatment to predict outcome.

We typically used a regimen of broad-spectrum antimicrobials that was modified based on microbial recovery. Topical therapy was often supplemented with subconjunctival and systemic agents.<sup>10,15</sup> Most cases are because of *Pseudomonas*, staphylococci, and streptococci, although other bacteria are occasionally encountered. Fungi such as *Scedosporium* sp. are also capable of infecting the sclera.<sup>18,19</sup> Among available antifungal agents, voriconazole has proved useful in controlling ocular scedosporiosis<sup>20,21</sup> and other causes of fungal scleritis.<sup>22</sup>

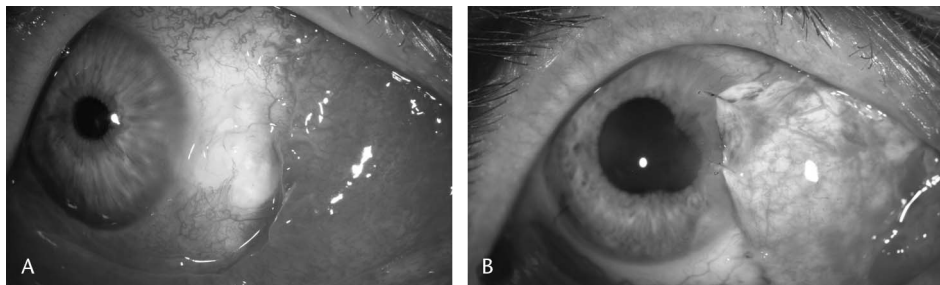
Medical therapy aims to control microbial proliferation, but surgical intervention can be appropriate for some eyes. Debridement and sclerectomy debulk necrotic tissue and may facilitate antibiotic access.<sup>23</sup> A patch graft helps to restore structural integrity of the globe.<sup>24</sup> Although vascularization might speed the resolution of infection, we generally defer conjunctival flap and other grafting procedures until scleral inflammation is medically controlled.

Adjunctive corticosteroid use remains controversial in the management of corneal and scleral infections.<sup>10,25</sup> We initiated topical and oral corticosteroids during the course of antibacterial therapy for patients with bacterial scleritis. Although we did not encounter treatment-related adverse effects, the role of immunosuppression in the management of scleral infectious disease remains uncertain but promising.<sup>26</sup>

Vision-limiting sequelae of microbial scleritis include cataract, exudative retinal detachment, choroidal effusion, glaucoma, and phthisis bulbi. In recent case series, nearly one-fourth of the eyes with microbial scleritis were removed because of progressive inflammation and other complications.<sup>9,10,23,27,28</sup> Enucleation during scleritis may be more likely with pyogenic scleral infection than granulomatous vasculitis.<sup>29</sup> Good vision has previously been obtained in only approximately half of the treated patients,<sup>9,10,27,28</sup> but 5 of 6 eyes in this study regained visual acuity better than 20/200.

All patients who had good visual outcome had visual acuity of 20/200 or better at the time of diagnosis, each had intensive antibiotic management, and 3 patients underwent early surgical intervention. Although the limited number of patients in our study precludes statistical analyses, a previous study also indicated that combined medical and surgical management improved visual outcome compared with medical treatment alone.<sup>28</sup> The cumulative experience suggests that better initial visual acuity correlates with a less intense ocular infection, greater opportunity for therapeutic response, and better visual outcome.

**FIGURE 2.** Case 3. *P. aeruginosa* scleritis after pterygium surgery. A, Calcified scleral plaque with inflammation. B, After 8 weeks of antibacterial therapy, scleral patch graft with rotating conjunctival flap was performed.



Effective management, guided by laboratory evaluation, can improve the structural and visual outcome of microbial scleritis. Antimicrobial agents, judicious surgical intervention, and prudent antiinflammatory treatment offer the opportunity to control the inflammatory complications of infections affecting the sclera.

### ACKNOWLEDGMENTS

The authors are grateful to Dr Milton Boniuk, who provided clinical information for one of the patients in this report, and for the assistance of microbiologists at the Sid W Richardson Ocular Microbiology Laboratory and the Methodist Hospital.

### REFERENCES

- Hemady R, Sainz de la Maza M, Raizman MB, et al. Six cases of scleritis associated with systemic infection. *Am J Ophthalmol.* 1992;114:55–62.
- Ramesh S, Ramakrishnan R, Bharathi MJ, et al. Prevalence of bacterial pathogens causing ocular infections in South India. *Indian J Pathol Microbiol.* 2010;53:281–286.
- Su CY, Tsai JJ, Chang YC, et al. Immunologic and clinical manifestations of infectious scleritis after pterygium excision. *Cornea.* 2006;25:663–666.
- Moreno Honrado M, del Campo Z, Buil JA. A case of necrotizing scleritis resulting from *Pseudomonas aeruginosa*. *Cornea.* 2009;28:1065–1067.
- Okhravi N, Odufuwa B, McCluskey P, et al. Scleritis. *Surv Ophthalmol.* 2005;50:351–363.
- Wirostko WJ, Covert DJ, Han DP, et al. Microbiological spectrum of organisms isolated from explanted scleral buckles. *Ophthalmic Surg Lasers Imaging.* 2009;40:201–202.
- Biber JM, Schwam BL, Raizman MB. Scleritis. In: Krachmer JH, Mannis MJ, Holland EJ, eds. *Cornea.* 3rd ed. Philadelphia, PA: Mosby Elsevier; 2005: 1253–1265.
- Foster CS, Sainz de la Maza M. *The Sclera.* New York, NY: Springer-Verlag; 1994:242–277.
- Jain V, Garg P, Sharma S. Microbial scleritis—experience from a developing country. *Eye.* 2009;23:255–261.
- Helm CJ, Holland GN, Webster RG, et al. Combination intravenous ceftazidime and aminoglycosides in the treatment of pseudomonal scleritis. *Ophthalmology.* 1997;104:838–843.
- Feiz V, Redline DE. Infectious scleritis after pars plana vitrectomy because of methicillin-resistant *Staphylococcus aureus* resistant to fourth-generation fluoroquinolones. *Cornea.* 2007;26:238–240.
- Rich RM, Smiddy WE, Davis JL. Infectious scleritis after retinal surgery. *Am J Ophthalmol.* 2008;145:695–699.
- Moriarty AP, Crawford GJ, McAllister IL, et al. Severe corneoscleral infection: a complication of beta irradiation scleral necrosis following pterygium excision. *Arch Ophthalmol.* 1993;111:947–952.
- Lin CP, Shih MH, Su CY. Scleritis (letter). *Surv Ophthalmol.* 2006;51: 288–289.
- Meallet MA. Subpalpebral lavage antibiotic treatment for severe infectious scleritis and keratitis. *Cornea.* 2006;25:159–163.
- Lee JE, Oum BS, Choi HY, et al. Methicillin-resistant *Staphylococcus aureus* sclerokeratitis after pterygium excision. *Cornea.* 2007;26: 744–746.
- Paula JS, Simão ML, Rocha EM, et al. Atypical pneumococcal scleritis after pterygium excision: case report and literature review. *Cornea.* 2006; 25:115–117.
- Singh RP, McCluskey P. *Scedosporium prolificans* sclerokeratitis 10 years after pterygium excision with adjunctive mitomycin C. *Clin Experiment Ophthalmol.* 2005;33:433–434.
- Jhanji V, Yohendran J, Constantinou M, et al. *Scedosporium* scleritis or keratitis or both: case series. *Eye Contact Lens.* 2009;35:312–315.
- Shah KB, Wu TG, Wilhelmus KR, et al. Activity of voriconazole against corneal isolates of *Scedosporium apiospermum*. *Cornea.* 2003; 22:33–36.
- Bunya VY, Hammersmith KM, Rapuano CJ, et al. Topical and oral voriconazole in the treatment of fungal keratitis. *Am J Ophthalmol.* 2007; 143:151–153.
- Fincher T, Fulcher SF. Diagnostic and therapeutic challenge of *Aspergillus flavus* scleritis. *Cornea.* 2007;26:618–620.
- Reynolds MG, Alfonso E. Treatment of infectious scleritis and keratoscleritis. *Am J Ophthalmol.* 1991;112:543–547.
- Sangwan VS, Jain V, Gupta P. Structural and functional outcome of scleral patch graft. *Eye.* 2006;21:930–935.
- Hindman HB, Patel SB, Jun AS. Rationale for adjunctive topical corticosteroids in bacterial keratitis. *Arch Ophthalmol.* 2009;127: 97–102.
- Lee GA, Gray TB, Dart JKG, et al. *Acanthamoeba* sclerokeratitis: treatment with systemic immunosuppression. *Ophthalmology.* 2002;109: 1178–1182.
- Hsiao CH, Chen JY, Huang SCM, et al. Intrasceral dissemination of infectious scleritis following pterygium excision. *Br J Ophthalmol.* 1998; 82:29–34.
- Huang FC, Huang SP, Tseng SH. Management of infectious scleritis after pterygium excision. *Cornea.* 2000;19:34–39.
- Riono WP, Hidayat AA, Rao NA. Scleritis: a clinicopathologic study of 55 cases. *Ophthalmology.* 1999;106:1328–1333.