

Subpalpebral Lavage Antibiotic Treatment for Severe Infectious Scleritis and Keratitis

M. A. Meallet, MD

Objective: To report the subpalpebral lavage therapy for the treatment of infectious scleritis and keratitis.

Method: Six patients were admitted for treatment of severe infectious scleritis and keratitis and were initiated on the subpalpebral lavage system after showing no improvement with topical fortified antibiotics. A continuous antibiotic lavage was applied until clinical sterility was achieved and topical steroids were gradually added to control concomitant inflammation.

Results: All 6 patients had resolution of their infections and achieved a stable ocular surface with no inflammation. One patient required a corneal transplant for active inflammation and corneal thinning, 1 had a transplant for a dense central corneal scar, and 1 patient underwent corneal transplant and cataract extraction. One case was a *Pseudomonas* keratitis in a blind eye, which rapidly resolved and has remained stable. Four patients required additional surgeries, which included 3 corneal transplants, 2 cataract extractions, and 1 glaucoma aqueous shunt.

Conclusion: Continuous irrigation of the eye can improve scleral penetration of antibiotics. Subpalpebral lavage provides continuous irrigation and may be effective in the treatment of infectious scleritis of a variety of etiologies.

Key Words: infection, scleritis, keratitis, keratoscleritis, *Pseudomonas*, antibiotics

(*Cornea* 2006;25:159–163)

Infectious scleritis after pterygium surgery with adjunctive beta-radiation and mitomycin C has been widely reported and represents one of the most difficult complications seen with pterygium excision.^{1–7} The use of either of these adjunctive treatments may destroy episcleral and conjunctival vessels and tissues, and inhibit adequate wound healing, leaving the sclera a limited capacity to resist infection.³ Faulty surgical

techniques, including excessive cautery and the use of bare sclera techniques, are also believed to contribute to infectious scleritis.^{6,8} Poor contact lens care, coexisting neurotropism, and nonhealing epithelial defects contribute to the risk of developing corneal and scleral infections. In cases of *Pseudomonas* infection the most commonly implicated organism in infectious scleritis, the elaboration of collagenases by activated neutrophils is an important factor in tissue destruction, especially when the sclera is left bare to the ocular surface and remains susceptible to these degradation processes.¹

Traditional antibiotic regimens, such as topical fortified preparations, systemic antibiotics, and subconjunctival injections, prove to be inadequate in light of poor tissue penetration for each of these preparations. This is again the result of the avascularity of the sclera and the dense structure of the collagen fibers. The subpalpebral lavage technique was briefly described by Hessburg and Rowsey. We report a series of 6 cases of infectious scleritis and keratitis of various causes that were successfully treated with a novel variation of the original subpalpebral lavage technique.

MATERIALS AND METHODS

A corneal protector is placed on the eye and the upper eyelid is injected with 3 mL of 2% lidocaine with epinephrine. An 18-gauge spinal needle is passed into the superior fornix to emerge through the skin of the upper lid (Fig. 1A). A 22-gauge spinal needle is passed through the hub of a butterfly catheter and advanced to 5 mm from the end of the cut tube (Fig. 1B). The 22-gauge needle is inserted into the lumen of the 18-gauge needle and both were pulled through the superior fornix as a guide for the tube (Fig. 1C). The spinal needles were removed and the end of the tube is tied into a knot and ligated with a single 6-0 Prolene suture to keep it from unraveling. The knot is pulled into the fornix and irrigation is initiated using an IV pump with a flow rate of 20 mL/min and the occlusion pressure set to maximum to overcome the resistance in the tubing. The concentrations used were tobramycin 100 mg/mL and levofloxacin 500 mg/100 mL. These solutions are prepared in standard intravenous solutions and concentrations and exceed the minimal inhibitory concentration of each organism by at least 20-fold.

CASE REPORTS

Case 1

A 42-year-old, Hispanic woman presented with decreased vision and a painful left eye of 1 weeks' duration. She had pterygium

Received for publication September 15, 2004; revision received May 18, 2005; accepted May 25, 2005.

From the Doheny Eye Institute and the Department of Ophthalmology, Keck School of Medicine, University of Southern California, Los Angeles, CA. Supported in part by an unrestricted grant from Research to Prevent Blindness, Inc., New York, NY, and core grant EY03040.

Reprints: Mario A. Meallet, MD, Ocular Surface Center, LA County + USC Medical Center Department of Ophthalmology/Doheny Eye Institute, 1450 San Pablo Street, Los Angeles, CA 90033 (e-mail: meallet@usc.edu).

Video copies of the technique can also be requested by sending a blank CD and self-addressed, stamped envelope to the above address.

Copyright © 2006 by Lippincott Williams & Wilkins

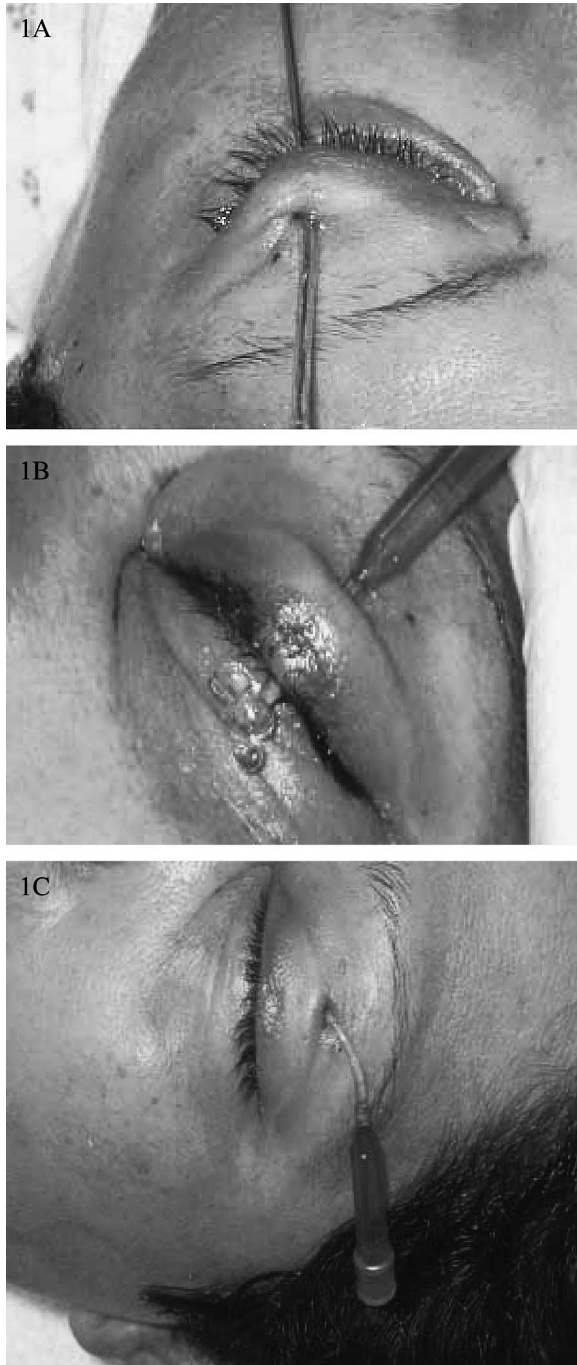


FIGURE 1. A, 18-gauge spinal needle passed from fornix through upper lid and cannulated with 22-gauge needle as guide for butterfly tubing. B, Tube end tied off and trimmed at level of knot. C, Knot pulled into fornix and ready for lavage.

excision 3 years earlier with adjunctive beta-radiation. On examination, best-corrected visual acuity was count-fingers in the left eye and 20/30 in the right eye. Slit-lamp examination of the left eye was notable for a focal area of bare sclera at the nasal limbus, with extensive thinning and necrosis (Fig. 2A). A diffuse infiltrate extended posteriorly underneath the area of intact conjunctiva, and there was a diffuse fibrinoid reaction in the anterior chamber with

a small layered hypopyon. Motility was limited on adduction and ultrasound revealed diffuse scleral thickening with an area of thinning at the site of medial rectus muscle insertion. There was thickening of the belly of the medial rectus muscle, and an underlying choroidal effusion. Microbiologic studies revealed *Pseudomonas aeruginosa*.

A subpalpebral lavage (SPL) was placed and irrigation with tobramycin (100 mg/L) was given for 8 days in addition to intravenous gentamicin (80 mg IV every 8 hours) for 3 weeks. The patient was then switched to topical fortified tobramycin and was discharged, with complete resolution of the infection 3 weeks later. The patient developed a cataract with a decrease in her vision to 20/100 and she underwent cataract extraction with intraocular lens implantation and an eventual visual acuity of 20/40 + 2. At the last follow-up visit she had a stable area of scleral thinning and minimal inflammation (Fig. 2B).

Case 2

A 49-year-old woman was referred by an outside ophthalmologist with a sclerokeratitis of the left eye. Pterygium excision had been performed 3 weeks earlier, and she developed pain and inflammation 2 weeks later. Her condition worsened with topical antibiotics, and 1 week later she was referred to the LAC+USC Medical Center for further management. At presentation she had hand motions vision with a large area of scleral necrosis and extensive thinning inferonasally at the limbus (Fig. 2C). The infiltrate extended onto the cornea with a small hypopyon. SPL with levofloxacin was started on the same day and cultures were positive for *P. aeruginosa* 1 week later. She was switched to a tobramycin lavage and showed stabilization during the next 6 days. The SPL was discontinued at day 10 and she was placed on fortified tobramycin drops every 30 minutes and 1% prednisolone acetate drops 4 times per day. She was discharged 2 weeks later and was eventually switched to 1% ofloxacin acetate eye drops; the inflammation resolved during the next 2 months (Fig. 2D). She developed a cataract and corneal scar with vision of 20/400 and underwent cataract surgery to 20/50, but developed progressive corneal edema with a drop in vision to 20/200. She had a corneal transplant 2 months later, and at last follow-up the graft was clear with best-corrected vision of 20/50.

Case 3

A 54-year-old woman with a history of cosmetic contact lens wear and poor lens hygiene presented with complaints of pain, irritation, and visual loss of the right eye for 6 days. She was found to have a large central corneal ulcer, with involvement of the nasal sclera, and a 2-mm central descemetocoele with hypopyon (Fig. 2E). Ultrasound showed only mild vitreous opacities. She was Seidel (-) at this time and was started on fortified tobramycin and fortified cefazolin every 30 minutes alternating. Cultures were positive for *P. aeruginosa* 3 days later, and SPL was initiated with tobramycin as described in case 1. One week later the lavage tube was noted to be eroding the superior cornea with approximately 50% thinning and the tube was removed. Fortified tobramycin drops were initiated. Three days later, the descemetocoele showed diffuse leakage with iris to the wound and cyanoacrylate glue and a contact lens was placed (Fig. 2F). The SPL was resumed at this time, taking care to cut the end of the tube flush with the knot to prevent further erosion of the cornea. She showed stabilization during the course of the next week and was discharged. Three days later, she presented with complaints of pain and was found to have a hyphema. She underwent corneal transplantation, and 1 week after surgery she was comfortable with a slightly edematous graft. Cultures performed on the host tissue remained negative, and histopathologic studies revealed no organisms.

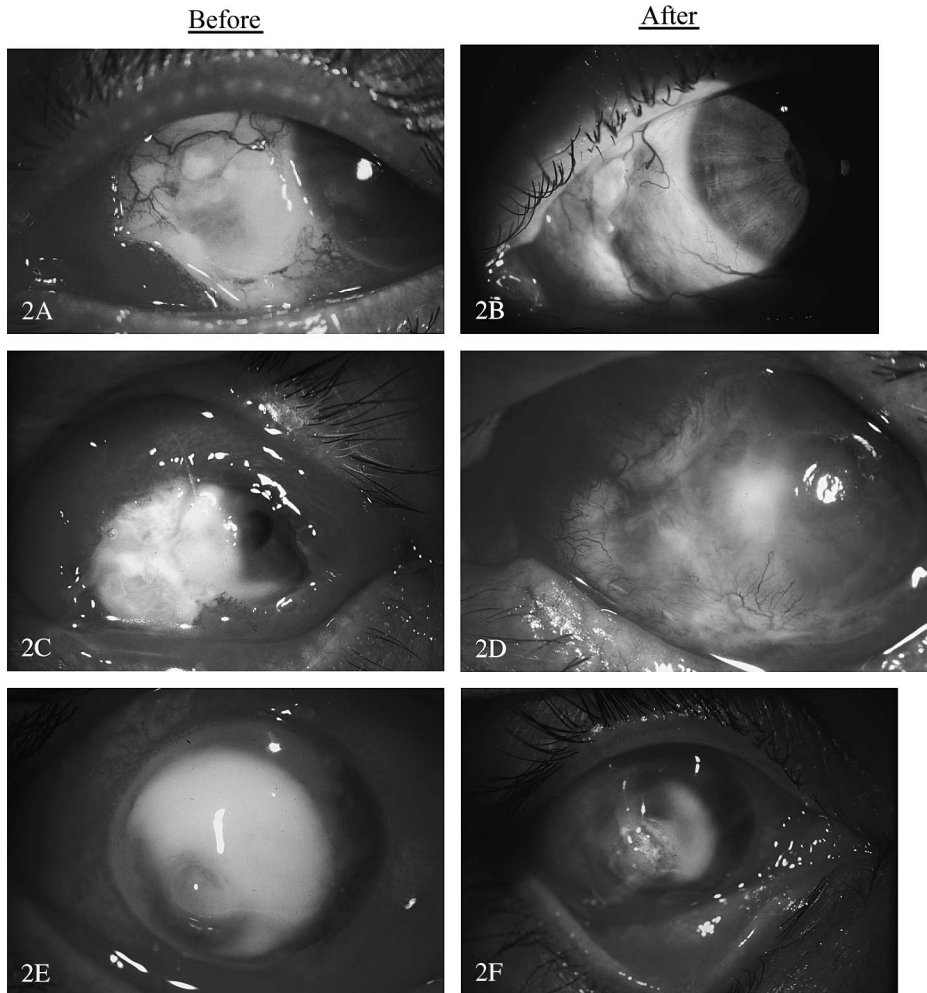


FIGURE 2. A and B, 42-year-old woman with *Pseudomonas* scleritis after pterygium excision with adjunctive beta-irradiation and 2 months after treatment. C and D, 49-year-old woman with *Pseudomonas* scleritis after pterygium excision with adjunctive mitomycin C and 2 months after treatment. E and F, 54-year-old woman with contact lens-related *Pseudomonas* keratoscleritis and after corneal perforation and tissue glue application.

DISCUSSION

The avascular nature and the tightly bound collagen structure of the sclera and cornea make these tissues relatively impermeable to the common preparations of topical and systemic antibiotics. Infections involving these tissues prove to be among the most difficult eye infections to manage, often with dire outcomes despite appropriate management. *Pseudomonas*, in particular, may remain dormant in deep intrascleral lamellae for long periods without inciting an inflammatory response.^{7,9} The identification of the offending organism is not always possible, and treatment often requires long-term management with broad spectrum antibiotics, which are usually fortified and given at frequent dosing regimens. With meticulous culturing technique and a bit of luck, the offending bacteria often can be identified, and therapy can be tailored and applied with the same type of fortified preparations and frequent dosing.

The visual prognosis of eyes affected by infectious scleritis remains poor despite aggressive and prolonged topical and systemic antibiotics. Surgical management, such as lamellar and penetrating corneoscleral grafts, has been suggested for keratoscleritis or scleritis that does not improve within the first few days of antibiotic treatment.^{9,10} However, grafts performed

in the active phase of an infection have a high risk of necrosis, sloughing, and rejection.^{7,11} Our best efforts to control these types of infections have been inadequate; as much as one-half of all eyes with severe scleral involvement eventually require enucleation or evisceration. In a literature review of reported cases of infectious keratoscleritis, approximately 60% of the eyes were eviscerated, enucleated, or were left with no light perception despite intensive treatment.^{9,10}

The subpalpebral lavage technique allowed us to cure infectious scleritis and keratitis in 6 severely affected patients. Three of these patients had positive cultures for *Pseudomonas* and received monotherapy with tobramycin. One patient was initially treated with levofloxacin, which was switched to tobramycin when *Pseudomonas* was isolated. The remaining 2 cases were culture-negative and were treated with the broader spectrum levofloxacin solution for the entire course. Any antibiotic with proven usage in treating ocular surface infections could be substituted for the antibiotics used in this study. The concentrations for each of the antibiotics used are noted in Table 1.

The subpalpebral lavage technique was associated with irritation in one of these patients, whereas it was well tolerated in the remaining patients. In 1 patient, it had to be

TABLE 1. Summary of Clinical Data

Case No./Age/Gender	Type of Infection	Lavage Solution (Concentration)	Days on Lavage Treatment	Visual Acuity Change (Pre → Post Lavage)	Follow-up	Complications/Comments
1/42/F	<i>Pseudomonas</i> keratoscleritis OS	Tobramycin (100 mg/L)	2 weeks	20/400 → 20/40	19 mos	Prior pterygium excision with beta-radiation. Cataract extraction performed after infection healed.
2/40/M	Contact Lens-related Infectious keratitis OS (culture -)	Levofloxacin (500 mg/100 mL)	2 weeks	LP → 20/300	7 mos	Optical corneal transplant done. Pt. had wound dehiscence after trauma with visual loss. Glaucoma aqueous shunt done.
3/49/F	Postsurgical <i>Pseudomonas</i> keratoscleritis	Levofloxacin (500 mg/100 mL) Tobramycin (100 mg/L)	6 days 4 days	20/200 → 20/50	5 mos	Optical corneal transplant and cataract extraction done
4/45/F	<i>Pseudomonas</i> keratitis OS	Tobramycin (100 mg/L)	1 week	20/200 → CF	7 mos	Patient had vision of 20/60 OD and 20/100 OS from prior neurosurgery
5/54/F	Contact Lens-related <i>Pseudomonas</i> keratoscleritis OS	Tobramycin (100 mg/L)	2 weeks	HM → HM	2 mos	Subpalpebral lavage done over two one week sessions. Therapeutic corneal transplant done
6/45/F	Large central corneal ulcer of unknown etiology culture (-)	Levofloxacin (500 mg/100 mL)	1 week	HM → HM	3 weeks	Tube removed by patient after 1 week. Treated with fortified Tobramycin and Ancef to complete resolution.

discontinued after noting that the subpalpebral tube was in contact with the superior cornea and had caused mild thinning. This patient, however, recovered well after the device was removed and the technique was modified in this patient when the SPL was replaced 1 week later. To prevent erosion of the cornea, the end of tube was cut flush with the knot to avoid exposure of the cut end to the corneal surface. This proved to be well tolerated in this patient and the subsequent 2 cases.

There was significant morbidity associated with these infections: 1 patient developed a cataract and had a corneal transplant and cataract extraction with excellent visual recovery, 1 patient developed intractably high intraocular pressures, and 1 other patient required a corneal transplant as the result of poor healing of the corneal ulcer. The corneal buttons of the 3 corneal transplant patients proved to be free of bacteria on microbiologic and histopathologic studies, illustrating that the infections were effectively treated.

In addition to delivery of antibiotics, this technique also serves to cleanse necrotic debris and decrease the free bacterial load from the ocular surface. We would expect a decrease in the likelihood of recurrence with this technique, a concept that is supported by the observation that neither of the latter 2 patients has had a recurrence of infection after therapeutic corneal transplants. The patient with high intraocular pressures eventually required a corneal transplant, cataract extraction, and Baerveldt glaucoma implant with well-controlled pressures for 3 weeks after surgery. He later suffered trauma to this eye with wound dehiscence and has had persistent graft edema and high pressures since that time. Patient 4 was not a candidate for corneal transplant, because her baseline vision is very poor. Patient 6, although she is a candidate for corneal transplant, is a homeless woman and has been lost to follow-up.

The obvious advantages of using this technique are outlined above. The less obvious, but equally important, advantages are highlighted by case 6 (a homeless patient). In our county hospital, we see the most severe forms of eye infections in patients who have limited access to medical care and who often are homeless or otherwise debilitated. Patient 6 also had a history of mental illness and substance abuse and was resistant to care by many of the hospital staff. The technique we have described is ideal because the tube can be inserted in less than 30 minutes, and the only additional nursing care required is changing the antibiotic bag, every 3 days for tobramycin or every 1½ days for levofloxacin. By applying this device, we effectively managed her infection while decreasing the burden on the nursing staff. Ultimately, the treatment course was uncomplicated and she was discharged with an intact, healed ocular surface.

This technique offers tremendous advantages over our standard treatment of these severe infections. In our hospital population at the LAC+USC medical center, we now use this technique as first-line treatment in infections that have clearly violated the sclera and as second-line therapy (after a short course of fortified topical antibiotics) in cases of severe keratitis that threatens to involve the sclera. We have salvaged each of the 6 eyes treated thus far, and will continue to report on the success of this technique as we gather more experience.

An additional benefit of this technique is that it serves to cleanse necrotic debris and bacteria from the ocular surface. The question of systemic absorption has not been addressed in these patients, and we hope to pursue this in subsequent cases. We caution that the antibiotic preparations can be mistaken for intravenous usage and that the nursing staff must be clearly instructed on their proper administration. We hope to offer more information on this technique, including the potential use for fungal infections, in future reports.

REFERENCES

1. Dusenbery KE, Alul IH, Holland EJ, et al. Beta irradiation of recurrent pterygia: results and complications. *Int J Radiat Oncol Biol Phys.* 1992; 24:315–320.
2. Grimmer MR, Holland EJ, Krachmer JH. Management of pterygium. *Cornea.* 1997.
3. Mackenzie FD, Hirst LW, Kynaston B, et al. Recurrence rate and complications after beta irradiation for pterygia. *Ophthalmology.* 1991;98: 1776–1780.
4. Margo CE, Polack FM, Hood CI, et al. Aspergillus panophthalmitis complicating treatment of pterygium. *Cornea.* 1988;7:285–289.
5. Moriarty AP, Crawford GJ, McAllister IL, et al. Bilateral streptococcal corneoscleritis complicating beta irradiation induced scleral necrosis. *Br J Ophthalmol.* 1993;77:251–252.
6. Moriarty AP, Crawford GJ, McAllister IL, et al. Severe corneoscleral infection. A complication of beta irradiation scleral necrosis following pterygium excision. *Arch Ophthalmol.* 1993;111:947–951.
7. Raber IM, Laibson PR, Kurz GH, et al. Pseudomonas corneoscleral ulcers. *Am J Ophthalmol.* 1981;92:353–362.
8. Rubinfeld RS, Pfister RR, Stein RM, et al. Serious complications of topical mitomycin-C after pterygium surgery. *Ophthalmology.* 1992;99: 1647–1654.
9. Alfonso E, Kenyon KR, Ormerod LD, et al. Pseudomonas corneoscleritis. *Am J Ophthalmol.* 1987;103:90–98.
10. Reynolds MG, Alfonso E. Treatment of infectious scleritis and kerato-scleritis. *Am J Ophthalmol.* 1991;112:543–547.
11. Tarr KH, Constable IJ. Late complications of pterygium treatment. *Br J Ophthalmol.* 1980;64:496–505.