



Eye platelet-rich plasma in the treatment of ocular surface disorders

Jorge L. Alio^{a,b}, Alejandra E. Rodriguez^c, and Dominika WróbelDudzińska^d

Purpose of review

Blood-derived products [autologous serum, eye platelet-rich plasma (E-PRP), plasma rich in growth factors] are successful therapies for ocular surface disorders, which compromise the integrity of the cornea surface and conjunctiva.

Recent findings

The most noteworthy and recent research has been directed towards hemoderivatives that include platelets. PRP for ophthalmologic use (E-PRP) has achieved successful outcomes as reported in the peer-review literature in the treatment of dry eye, post-laser in-situ keratomileusis ocular surface syndrome, dormant ulcers, and for ocular surface surgical reconstruction after corneal perforation associated to amniotic membrane transplantation, bovine pericardium membrane transplantation, or autologous fibrin membrane combined with solid PRP clot.

Summary

PRP is a portion of the patient's own blood having a platelet concentration above baseline. The main advantage of PRP over other products is the presence of the platelets and associated with this the prolonged release of growth factors that are involved in the wound healing process of the cornea and conjunctival surface. E-PRP seems to be a reliable and effective therapeutic approach to enhance epithelial wound healing and promote ocular surface regeneration in different pathological conditions.

Keywords

autologous fibrin membrane, autologous serum, ocular surface, plasma rich in growth factor, platelet-rich plasma

INTRODUCTION

There are many conditions in which the ocular surface is severely affected as keratoconjunctivitis sicca, persistent epithelial corneal defect, recurrent corneal erosion, neurotrophic keratopathy, post-laser in-situ keratomileusis (LASIK) ocular surface syndrome (OSS), dormant corneal ulcer, graft-versus-host disease, ocular cicatricial pemphigoid, and neurotrophic changes. The treatment of ocular surface disorders has a multifactorial approach and conventional therapy is often not enough to solve the problem. Scientists and clinicians have been searching for a long time for a substance that would be similar to tears in composition and possessing similar features and, which especially, may incite the process of biological regeneration of the tissues affected in ocular surface disorders.

PLATELETS AND EYE PLATELET-RICH PLASMA (E-PRP)

Platelets were discovered as an important reservoir of proteins and growth factors precipitating in hemostasis, tissue regeneration, immune response,

and wound healing. Alpha granules of the platelets include over 30 known biologically active substances such as platelet-derived growth factor, transforming growth factor β 1 and β 2 and insulin-like growth factor 1, vascular endothelial growth factor, epidermal cell growth factor, fibroblast growth factor 2, and insulin-like growth factor [1].

DIFFERENCES BETWEEN EYE PLATELET-RICH PLASMA AND OTHERS HEMODERIVATIVES

There is huge variety of autologous blood-derived products with variable amounts of platelets and

^aDepartment of Cornea and Refractive Surgery, VISSUM Corporation, ^bSchool of Medicine, Miguel Hernandez University, ^cResearch & Development Department, VISSUM Corporation and ^dResearch Fellow, VISSUM Corporation, Alicante, Spain

Correspondence to Jorge L. Alio, MD, PhD, VISSUM Corporacion Oftalmologica, Avda. de Denia s/n, 03016 Alicante, Spain. Tel: +34 902333444; fax: +34 965160468; e-mail: jlalio@vissum.com

Curr Opin Ophthalmol 2015, 26:325–332

DOI:10.1097/ICU.000000000000169

KEY POINTS

- The present work shows the uses of the platelet-rich plasma in ophthalmology.
- The present work describes the application of 100% autologous E-PRP for treatment of ocular surface disorders.
- The present work explains how to prepare the different types of E-PRP (eye drops, clots, fibrin membrane).
- The present article summarizes the clinical results obtained after the treatment with E-PRP in dry eye, ocular surface syndrome post-LASIK, dormant ulcers, and corneal perforations.

growth factors. Marx introduced a method of obtaining PRP from autologous blood using a double centrifugation technique and activating PRP just before using it [2], and the first therapeutic use of human PRP as an autologous transfusion component was proposed by Ferrari *et al.* [3]. In ophthalmology, we use eye platelet-rich plasma (E-PRP), which is an autologous preparation of plasma rich in platelets, but different from the PRP described by Marx and significantly different from plasma rich in growth factors (PRGF). E-PRP preparation requires one-step centrifugation using sodium citrate as an anticoagulant. E-PRP is used as topical eye drops for surface application and as a clot (solid E-PRP) for surgical procedures in ocular reconstruction. PRGF preparation requires specially designed devices (Endoret system centrifuge, Endoret Ophthalmologic Kit) and is based on a double centrifugation technique [4], whereas E-PRP preparation uses commercial tubes to obtain the blood and typical laboratory centrifuge to separate plasma.

Moreover, PRGF needs sodium calcium chloride as a clot activator. According to Alio *et al.* [5], calcium chloride is only used for the activation of liquid E-PRP when clots are needed for surgical procedures, such as corneal perforation treatment. Eye drops of E-PRP contain 100% autologous plasma and the maximum amount of platelets in suspension after a single centrifugation, without any other additive.

PRGF was first used in the treatment of persistent corneal epithelial defects [6] and latter for dry eye [7]. However, in 2004, Hartwig *et al.* [8,9] had showed the epitheliotropic capacity of growth factor preparations in an in-vitro cell culture model.

Autologous serum is also being used in the treatment of ocular surface [10]. The first positive effect of dry eye treatment with the application of 50% diluted autologous serum was described by Fox *et al.* [11] and Tsubota *et al.* [12] proved the efficacy of

20% autologous serum drops for treatment of dry eye with Sjögren's syndrome. Autologous serum is a body fluid, so it is capable of spreading infectious disease [13], as probably other preparations with blood derivatives. Also, some authors demonstrated a decreased serum effect when it was combined with antibiotics [14]. Generally, autologous serum treatment is well tolerated but one complication was described in the literature [15].

PREPARATION OF EYE PLATELET-RICH PLASMA

E-PRP preparation is made under strict sterile conditions using sterile and disposable materials and operating inside a laminar flow hood. Neither special equipment nor bovine thrombin is needed to obtain it [16]. Whole patient's blood was extracted aseptically using 3.2% sodium citrate as anticoagulant.

After the centrifugation (10 min at 1600 rpm), three layers were obtained. Platelet poor plasma (PPP) on the top, PRP below, and at the bottom separated white and red cells. PRP was aspirated and 3–4 ml aliquots are transferred into 10 ml new sterilized amber glass bottles with eye drop applicators. The bottle in use should be kept in the refrigerator at +4°C for 1 week, the rest of the bottles in the freezer at –20°C [17].

MECHANISM OF ACTION

Platelets deliver plenty of growth factors, cell adhesion molecules, and cytokines from alpha granules. The growth factors released prompts a cascade of many reactions responsible for migration, mitosis, extracellular matrix formation, and angiogenesis promoting proliferation and differentiation of corneal cells [18]. The major effects of PRP are derived from platelet-derived growth factor, which is the first growth factor to appear in the wound to increase the number of repaired cells, stimulate angiogenesis, and support the development of new blood vessels and the activated macrophages. Transforming growth factor is responsible for chemotaxis and controlling epithelial proliferation and maintaining cells in an indifferent state. The epidermal cell growth factor accelerates corneal epithelial proliferation and vascular endothelial growth factor and fibroblast growth factor 2 take part in angiogenesis. A wide range of clinical applications of PRP have been documented such as acute and chronic skin ulcers [19], cosmetic surgery (skin rejuvenation or hair loss disorders) [20,21], and macular hole repair in eye surgery [22]. There are many indications for the use of PRP in treatment in

orthopedics and sports medicine [23] and also in many dental and oral surgical procedures [24].

CLINICAL USE OF EYE PLATELET-RICH PLASMA IN OPHTHALMOLOGY

Dry eye

Dry eye, or *keratoconjunctivitis sicca*, is a multifactorial disease of the ocular surface. The standard treatment for dry eye is artificial tears, although topical corticosteroids have also been used [25].

Our group undertook a prospective study on patients with moderate and severe dry eye syndrome, including Sjögren's syndrome and Stevens-Johnson syndrome, according to the triple classification of Madrid [26]. After 4–6 times per day E-PRP treatment, 89% of patients reported improvement and absence of subjective symptoms. The increase in visual acuity was observed in 28% of patients. In 56% of patients, an increase in the tear meniscus height and tear break-up time was noticed. Improvement in fluorescein staining and significant reduction of the inflammation was found along with an increase in the density of conjunctival goblet cells [27]. In summary, topical treatment with E-PRP eye drops proved to be a successful therapeutic method to relieve symptoms of dry eye and improve regeneration of the ocular surface.

Ocular surface syndrome after laser in-situ keratomileusis

LASIK surgery is the most common refractive procedure and the post-LASIK OSS may appear causing dissatisfaction in many patients and may have medico-legal implications for the refractive surgeon [28]. Patients develop dryness and irritation, associated with suboptimal levels of uncorrected and corrected vision after LASIK surgery. The mechanism of post-LASIK OSS is still unknown, although it is acknowledged today that it is caused by a neurotropic mechanism [29,30]. Corneal denervation after surgery results in changes in tear film quality and quantity [31]. After LASIK, the observed loss of conjunctival goblet cells aggravates the situation. The first-line treatment with artificial tears is not satisfactory and alternative methods such as punctal occlusion, treatment of meibomian gland dysfunction, or anti-inflammatory therapy are used [25].

E-PRP has been proposed as an efficient therapy for this disorder considering the good results obtained for dry eye and dormant corneal ulcers [5,27]. The patients were all affected by severe-to-moderate dry eye syndrome for at least 6 months after LASIK surgery [32]. In all patients, we noticed

impaired vision, fluorescein staining, and a tear break-up time between 4 and 9 s. After 1 month of treatment, the vast majority of patients had improved subjective symptoms. Clinically, we observed complete resolution of punctate epithelial keratitis, increase of tear break-up time, and improvement in visual acuity ranging from 1 to 4 lines. We found beneficial effects of promoting epithelial status after LASIK but no positive effect in the recovery of corneal sensitivity [33*].

Dormant corneal ulcers

Dormant ulcers are described as persistent corneal epithelial defects that have not responded to previous conventional topical treatment. The most common reasons for nonhealing ulcers are dry eye, neurotrophic keratopathy, metaherpetic disease, alkali burns, and immunological disorders. Patients with chronic corneal ulcers were included in the study (12 neurotrophic ulcers, 9 herpetic ulcers, 5 immunological ulcers). They used E-PRP eye drops topically six times per day. A reduction in size and depth of the corneal ulcer and the improvement in best-corrected visual acuity were observed (Fig. 1). Furthermore, patients declared a reduction in pain, photophobia, and discomfort. Examination revealed a decrease hyperemia and conjunctival edema. To sum up, clinical improvement was observed in 95% of the patients, 50% of the ulcers healed/completely reepithelialized, and in 58% of patients distance vision improved [5].

SURGICAL USE OF EYE PLATELET-RICH PLASMA AND OCULAR SURFACE RECONSTRUCTION

Small corneal perforations can be treated by bandage contact lens or using an corneal adhesive cyanoacrylate glue, fibrin glue, and conjunctival flaps, whereas large/extensive corneal perforations require surgical intervention such as amniotic membrane transplantation (AMT) or corneal transplantation [34]. More innovative strategies of treatment of corneal perforations are cultivated corneal, oral mucosal epithelial transplantation, and autologous cultivated corneal limbal epithelial transplantation [35]. The combination of solid E-PRP and tectonic elements to close a perforated eye has been subjected in several reports.

Solid eye platelet-rich plasma as a surgical tool in corneal perforations

To prepare solid E-PRP clot, 40–60 ml of blood were collected from the patients just before surgery. The

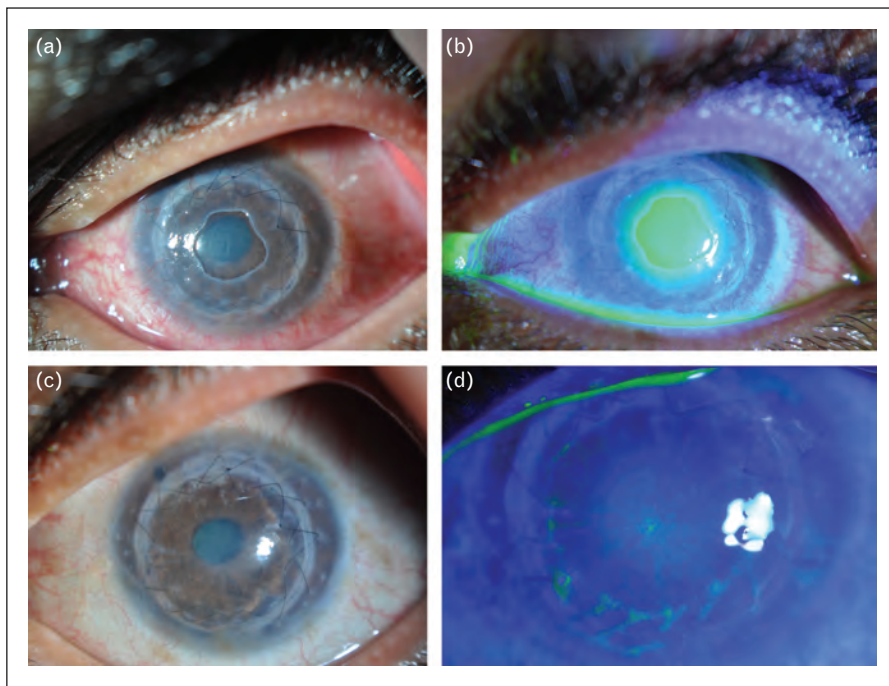


FIGURE 1. (a, b) Patient with dormant ulcer after penetrating keratoplasty and before treatment. (c, d) The same patient after eye platelet-rich plasma treatment.

blood was centrifuged and the PPP was aspirated and reserved to prepare the autologous fibrin membrane. Meanwhile, PRP was harvested to prepare the E-PRP clot: 1 ml of E-PRP and 50 μ l of 10% calcium chloride (Braun) are incubated at 37°C for 30 min. E-PRP clots have a platelet concentration two to three times the concentration in blood. Clots prepared in this way can be used in the three different surgical techniques that we explain below.

Amniotic membrane transplantation combined with clot of eye platelet-rich plasma

Our team performed a study on the therapy of corneal perforations and impending perforation because of deep ulcers. Eyes were treated surgically with AMT combined with a clot of autologous E-PRP as previously described [5]. The aim of this procedure was to improve the benefits of the amniotic membrane, adding fresh clots of E-PRP just over the perforation. After wound debridement and application of amniotic membrane with the epithelial side up, a clot of autologous E-PRP was put just under the amniotic membrane. Topical antibiotics and dexamethasone were instilled, and a temporal tarsorrhaphy was performed (Fig. 2). A reduction in size and depth of the corneal ulcer and improvement in best-corrected visual acuity were found after this treatment. Seventy-one percent of eyes had a complete resolution of the perforations and deep

ulcers, and in 57% of cases vision improved and inflammation decreased. The greatest disadvantage of amniotic membrane is that it is a heterologous transplant [36]. Second, it is biological tissue so its quality and efficiency depend on many variables [37]. Taking this into consideration, Alio *et al.* tried to find another low biological risk tissue to manage corneal perforations.

Bovine pericardium membrane (Tutopatch) combined with clot of autologous eye platelet-rich plasma

We used a new technique to treat perforated corneal ulcers. In this study, a bovine pericardium membrane (Tutopatch) combined with solid E-PRP was used as a surgical method to seal perforations [38]. Tutopatch is a collagenous membrane obtained from bovine pericardium in a multistep process. First, the epithelium around the perforation was debrided, and then the pericardium membrane was sutured. E-PRP clots were placed on the debrided area underneath the collagenous membrane. Furthermore, stitches were used to fixate the Tutopatch. At the end of the procedure, a temporal partial tarsorrhaphy was performed (Fig. 3). The tarsorrhaphy was opened and examination revealed stable closure of the corneal perforation, and no evidence of infection or inflammation. The patients were followed up for 3 months with no evidence of relapses or perforations in most cases [38].

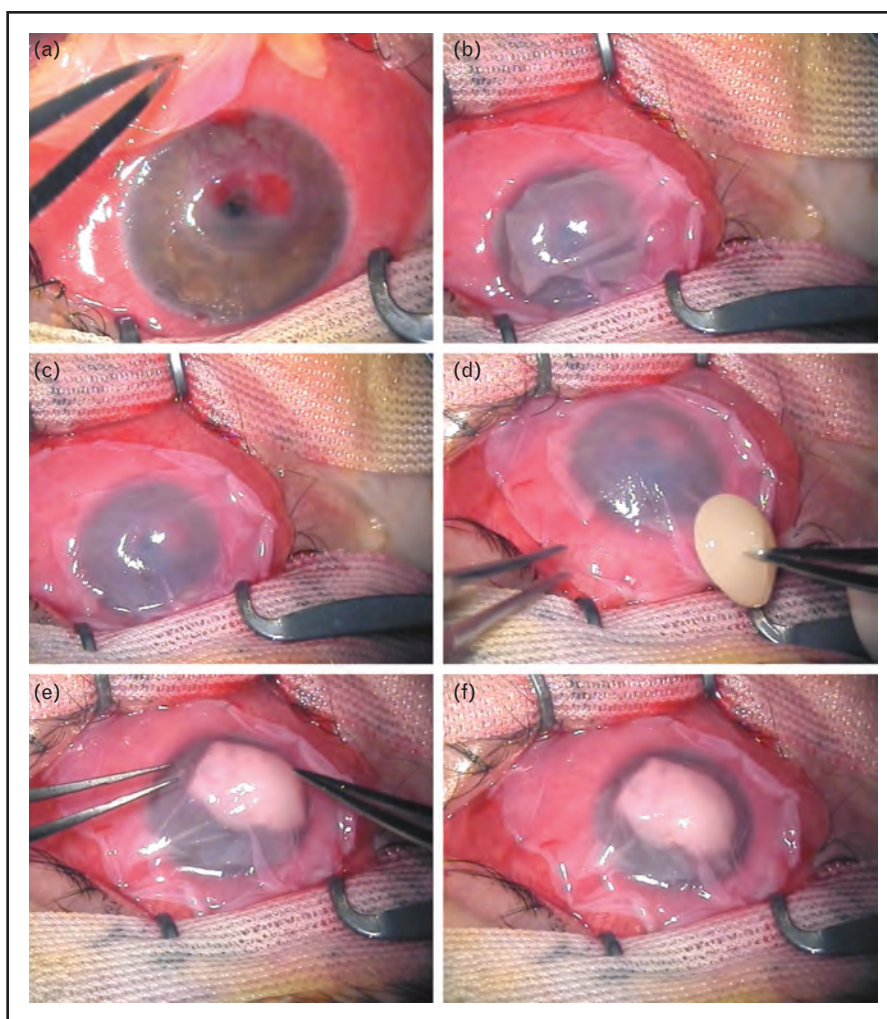


FIGURE 2. (a) Perforated eye before treatment with amniotic membrane transplantation combined with a clot of autologous eye platelet-rich plasma (E-PRP). (b, c) Amniotic membrane transplantation. (d) The clot of E-PRP. (e) Introducing the clot of E-PRP under the amniotic membrane. (f) Final result after amniotic membrane transplantation with the clot of E-PRP in perforated eye.

Tutopatch with solid E-PRP seems to be a highly effective method for treatment of perforated corneal ulcers. Probably, the only drawback would be the fact that it looks absolutely white, opaque, and is not flexible or soft for the eye.

Autologous fibrin membrane combined with solid eye platelet-rich plasma

The more recent study of Alio *et al.* [39^{***}] has demonstrated the effectiveness of using autologous fibrin membrane combined with solid E-PRP in the management of perforated corneal ulcers.

Preparation of the autologous fibrin membrane

After centrifugation, 5 ml of PPP were placed in a beaker previously sterilized with 500 μ l of 10% calcium chlorite and 1 ml of previously prepared

autologous thrombin. The mix was incubated at 37°C for 1 h. After the incubation, the fibrin membrane obtained was circular, with a diameter of between 18 and 22 mm, and its thickness was approximately 1 mm (Fig. 4). With this shape and size, the fibrin membrane was perfectly manageable and suitable for application on the damaged ocular surface.

All cases (11 eyes) had developed corneal perforation secondary to a severe corneal ulcerative disease. Fibrin membrane was sewn onto the conjunctiva and E-PRP clots were placed into the corneal perforation underneath the fibrin membrane. A temporal partial tarsorrhaphy was performed at the end (Fig. 4). In all patients, corneal perforation was sealed with no evidence of leakage.

The fibrin membrane was present for the first 3–5 days then disappeared. Patients were free of

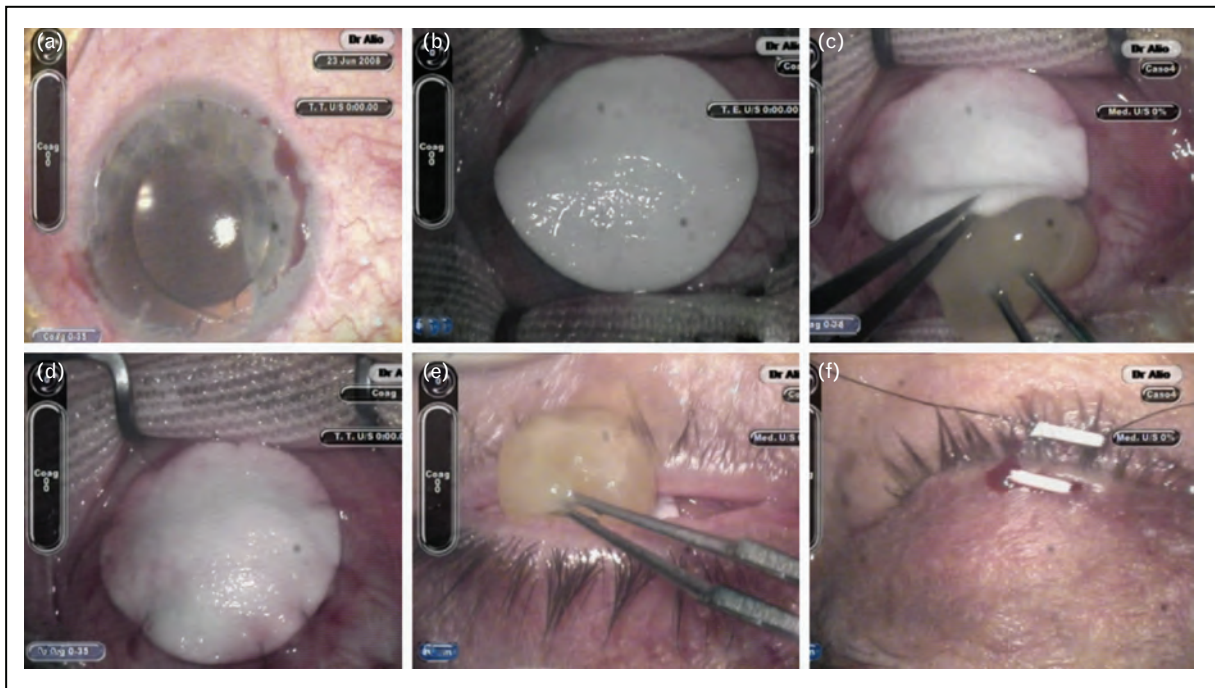


FIGURE 3. (a) Chronic epithelial defect after debridement of epithelium. (b) Bovine pericardium membrane (Tutopatch). (c) Introducing the clot of eye platelet-rich plasma under the Tutopatch. (d) Sutured bovine pericardium membrane. (e) Introducing the clot of platelet-rich plasma underneath the eyelids. (f) Temporal partial tarsorrhaphy.

subjective symptoms such as pain and discomfort. At 7 days postoperatively, some cases showed epithelial closure over a stromal thinning and others showed healing of both the epithelium and stroma.

No relapses occurred in any of the cases before the definite corneal grafting surgery that was performed in 7 of the 11 patients. The main drawback of this technology is the cost relative to other techniques

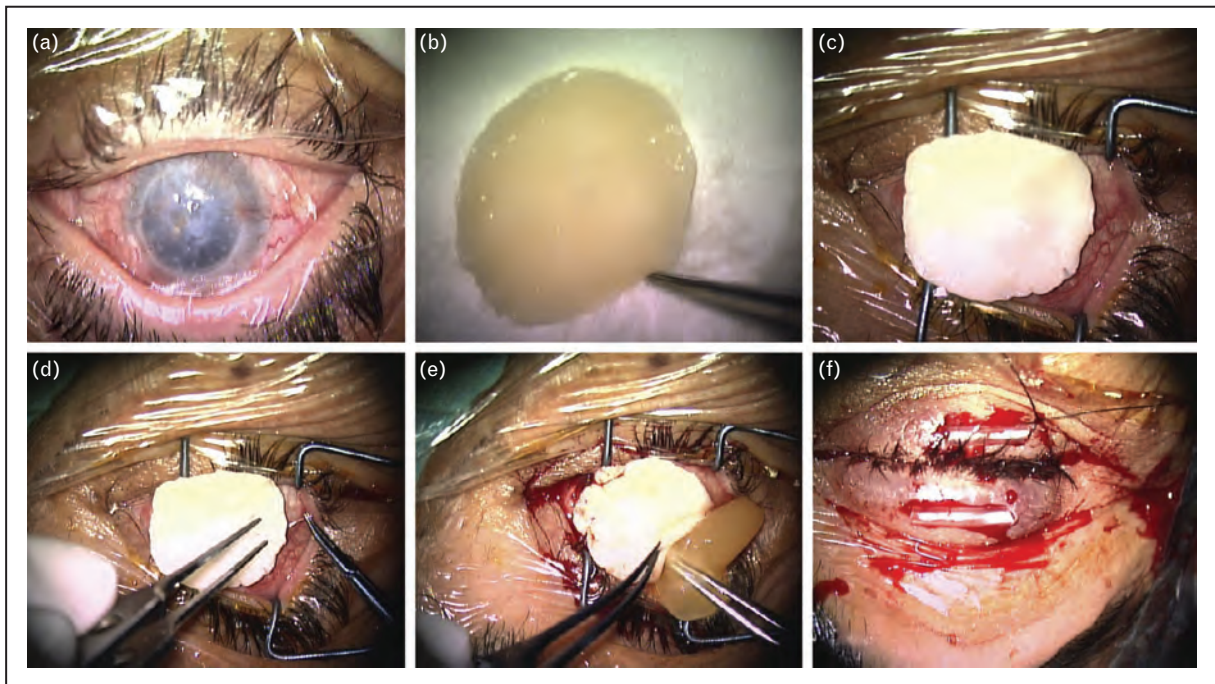


FIGURE 4. (a) Dormant ulcer after keratoplasty just before surgical procedure. (b) Fibrin membrane. (c) Introducing the fibrin membrane onto the cornea. (d) Stitches to fixate the fibrin membrane. (e) Introducing a clot of autologous eye platelet-rich plasma underneath the fibrin membrane. (f) Temporal partial tarsorrhaphy.

and the time spent in preparation and the main advantage is that it is 100% autologous.

There are still many ambiguities concerning the real effect of the molecules contained in the hemoderivatives. Some of them, for example, immunoglobulins, antibodies, or the complement may interfere in the proper wound healing process especially in autoimmune disorders. Most of these molecules are proteins; therefore, the heating process seems to be a good solution to inactivate the complement components or immunoglobulin and antibodies. However, on the contrary, heating causes a denaturizing effect, which may affect other factors included in plasma or serum [40]. Therefore, the future direction for PRP treatment in ophthalmology may include patients with autoimmune diseases such as Stevens–Johnson syndrome, ocular cicatricial pemphigoid, and graft-versus-host disease.

CONCLUSION

In this work, we summarize our experience using E-PRP to treat some of the disorders affecting the ocular surface. The evidence available on E-PRP seems to confirm the safety and effectiveness of E-PRP treatment for ocular surface disorders. Autologous E-PRP eye drop application improves regeneration of the ocular surface and relieves symptoms in patients with symptomatic dry eye and post-LASIK OSS.

Regarding the surgical applications of E-PRP as a clot combined with AMT, Tutopatch or Autologous Fibrin Membrane may be used as a solution for the urgent management of corneal perforations, taking into consideration that only the combination with fibrin membrane is 100% autologous. Although very good results were obtained with E-PRP therapy in the pathologies showed in this manuscript, there are still many unknown aspects regarding the mechanism of action. Numerous important questions rise about long-term stability of E-PRP, concentration, and bioactivity level or potency of growth factors contained in the E-PRP. Furthermore, clinical comparative studies and long-term observations are required to provide clear evidence of the effectiveness of E-PRP treatment.

Acknowledgements

None.

Financial support and sponsorship

This study has been supported in part by a grant from the Spanish Ministry of Health, Instituto Carlos III, Red Temática de Investigación Cooperativa en Salud ‘Patología ocular del envejecimiento, calidad visual y calidad de vida’, Subproyecto de Calidad Visual (RD07/0062),

and a grant from the Spanish Ministry of Economy and Competitiveness, Instituto Carlos III, Red Temática de Investigación Cooperativa en Salud (RETICS) ‘Prevención, detección precoz y tratamiento de la patología ocular prevalente, degenerativa y crónica’. Subprograma ‘Dioptrio ocular y patologías frecuentes’ (RD12/0034/0007).

Conflicts of interest

There are no conflicts of interest.

REFERENCES AND RECOMMENDED READING

Papers of particular interest, published within the annual period of review, have been highlighted as:

- of special interest
- of outstanding interest

1. Nurden A. Platelets, inflammation and tissue regeneration. *Thromb Haemostasis* 2011; 105 (Suppl 1):13–33.
2. Marx RE. Platelet-rich plasma (PRP): what is PRP and what is not PRP? *Implant Dent* 2001; 10:225–228.
3. Ferrari M, Zia S, Valbonesi M, *et al.* A new technique for hemodilution, preparation of autologous platelet-rich plasma and intraoperative blood salvage in cardiac surgery. *Int J Artif Organs* 1987; 10:47–50.
4. Anitua E. Plasma rich in GFs: preliminary results of use in the preparation of future sites for implants. *Int J Oral Maxillofac Implants* 1999; 14:529–535.
5. Alio JL, Abad M, Artola A, *et al.* Use of autologous platelet-rich plasma in the treatment of dormant corneal ulcers. *Ophthalmology* 2007; 114:1286–1293.
6. López-Plandolit S, Morales MC, Freire V, *et al.* Plasma rich in GFs as a therapeutic agent for persistent corneal epithelial defects. *Cornea* 2010; 29:843–848.
7. Lopez-Plandolit S, Morales MC, Freire V, *et al.* Efficacy of plasma rich in GFs for the treatment of dry eye. *Cornea* 2011; 30:1312–1317.
8. Hartwig D, Harloff S, Liu L, *et al.* Epitheliotropic capacity of a GF preparation produced from platelet concentrates on corneal epithelial cells: a potential agent for the treatment of ocular surface defects? *Transfusion* 2004; 44:1724–1731.
9. Hartwig D, Herminghaus P, Wedel T, *et al.* Topical treatment of ocular surface defects: comparison of the epitheliotropic capacity of fresh frozen plasma and serum on corneal epithelial cells in an in vitro cell culture model. *Transfus Med* 2005; 15:107–113.
10. Quinto GG, Campos M, Behrens A. Autologous serum for ocular surface diseases. *Arq Bras Oftalmol* 2008; 71:2008; 6 Suppl:47–54.
11. Fox RI, Chan R, Michelson J, *et al.* Beneficial effect of artificial tears made with autologous serum in patients with keratoconjunctivitis sicca. *Arthritis Rheum* 1984; 29:577–583.
12. Tsubota K, Goto E, Fujita H, *et al.* Treatment of dry eye by autologous serum application in Sjögren’s syndrome. *Br J Ophthalmol* 1999; 83:390395.
13. Geerling G, MacLennan S, Hartwig D. Autologous serum eye drops for ocular surface disorders. *Br J Ophthalmol* 2004; 88:1467–1474.
14. Nakamura M, Nishida T, Mishima H, *et al.* Effects of antimicrobials on corneal epithelial migration. *Curr Eye Res* 1993; 12:733–740.
15. McDonnell PJ, Schanzlin DJ, Rao NA. Immunoglobulin deposition in the cornea after application of autologous serum. *Arch Ophthalmol* 1988; 106:1423–1425.
16. Fréchette JP, Martineau I, Gagnon G. Platelet-rich plasma: GF content and roles in wound healing. *J Dent Res* 2005; 84:434–439.
17. Alio JL, Arnalich-Montiel F, Rodríguez AE. The role of ‘eye platelet rich plasma’ (E-PRP) for wound healing in ophthalmology. *Curr Pharm Biotechnol* 2012; 13:1257–1265.
18. Tandon A, Tovey JC, Sharma A, *et al.* Role of transforming GF Beta in corneal function, biology and pathology. *Curr Mol Med* 2010; 10:565–578.
19. Kim SA, Ryu HW, Lee KS, *et al.* Application of platelet-rich plasma accelerates the wound healing process in acute and chronic ulcers through rapid migration and upregulation of cyclin A and CDK4 in HaCaT cells. *Mol Med Rep* 2013; 7:476–480.
20. Kim DH, Je YJ, Kim CD, *et al.* Can platelet-rich plasma be used for skin rejuvenation? Evaluation of effects of platelet-rich plasma on human dermal fibroblast. *Ann Dermatol* 2011; 23:424–431.
21. Li ZJ, Choi HI, Choi DK, *et al.* Autologous platelet-rich plasma: a potential therapeutic tool for promoting hair growth. *Dermatol Surg* 2012; 38 (7 Pt 1): 1040–1046.

22. Blumenkranz MS, Ohana E, Shaikh S, *et al.* Adjuvant methods in macular hole surgery: intraoperative plasma-thrombin mixture and postoperative fluid-gas exchange. *Ophthalmic Surg Lasers* 2001; 32:198–207.
23. Taylor DW, Petrera M, Hendry M, *et al.* A systematic review of the use of platelet-rich plasma in sports medicine as a new treatment for tendon and ligament injuries. *Clin J Sport Med* 2011; 21:344–352.
24. Albanese A, Licata ME, Polizzi B, *et al.* Platelet-rich plasma (PRP) in dental and oral surgery: from the wound healing to bone regeneration. *Immun Ageing* 2013; 10:23.
25. Yang CQ, Sun W, Gu YS. A clinical study of the efficacy of topical corticosteroids on dry eye. *J Zhejiang Univ Sci B* 2006; 7:675–678.
26. Murube J, Benitez del Castillo JM, Chenzhuo L, *et al.* The Madrid triple classification of dry eye. *Arch Soc Esp Oftalmol* 2003; 78:587–593.
27. Alió JL, Colecha JL, Pastor S, *et al.* Symptomatic dry eye treatment with autologous platelet-rich plasma. *Ophthalmic Res* 2007; 39:124–129.
28. Ramos-Esteban JC, Wilson S. Dry eye. In: Alió JL, Azar DT, editors. *Management of complications in refractive surgery*, 1st ed. Berlin, Germany: Springer; 2008. pp. 74–85.
29. Wilson SE, Ambrósio R. Laser in situ keratomileusis-induced neurotrophic epitheliopathy. *Am J Ophthalmol* 2001; 132:405–406.
30. Wilson SE. Laser in situ keratomileusis-induced (presumed) neurotrophic epitheliopathy. *Ophthalmology* 2001; 108:1082–1087.
31. Nettune GR, Pflugfelder SC. Post-LASIK tear dysfunction and dysesthesia. *Ocul Surf* 2010; 8:135–145.
32. Alió JL, Pastor S, Ruiz-Colecha J, *et al.* Treatment of ocular surface syndrome after LASIK with autologous platelet-rich plasma. *J Refract Surg* 2007; 23:617–619.
33. Javaloy J, Alió JL, Rodríguez AE, *et al.* Effect of platelet-rich plasma in nerve regeneration after LASIK. *J Refract Surg* 2013; 29:213–219. This study analyzes the effect of E-PRP when it is applied after LASIK. It evaluates the state of epithelium and the corneal sensitivity.
34. Jhanji V, Young AL, Mehta JS, *et al.* Management of corneal perforation. *Surv Ophthalmol* 2011; 56:522–538.
35. Nakamura T, Kinoshita S. New hopes and strategies for treatment of several ocular surface disease. *Curr Opin Ophthalmol* 2011; 22:274–278.
36. Addis PJ, Hunt CJ, Dart JK. Amniotic membrane grafts, 'fresh' or frozen? A clinical and in vitro comparison. *Br J Ophthalmol* 2001; 85:905–907.
37. Rahman I, Said DG, Maharajan VS, *et al.* Amniotic membrane in ophthalmology: indications and limitations. *Eye* 2009; 23:1954–1961.
38. Alió JL, Rodríguez AE, Martínez LM. Bovine pericardium membrane (Tuto-patch) combined with solid platelet-rich plasma for the management of perforated corneal ulcers. *Cornea* 2013; 32:619–624.
39. Alió JL, Rodríguez AE, Martínez LM, Rio AL. Autologous fibrin membrane combined with solid platelet-rich plasma in the management of perforated corneal ulcers: a pilot study. *JAMA Ophthalmol* 2013; 131:745–751. This is the first publication in which autologous fibrin membrane was used in ophthalmology to treat perforated corneas. The article highlights that this treatment is 100% autologous.
40. Ayache S, Panelli MC, Byrne KM, *et al.* Comparison of proteomic profiles of serum, plasma, and modified media supplements used for cell culture and expansion. *J Transl Med* 2006; 4:40.