

# LENS CAPSULAR FLAP TRANSPLANTATION IN THE MANAGEMENT OF REFRACTORY MACULAR HOLE FROM MULTIPLE ETIOLOGIES

SAN-NI CHEN, MD,\*†‡ CHUNG-MAY YANG, MD§¶

---

**Purpose:** To report the clinical results of lens capsular flap transplantation in refractory macular hole (MH).

**Methods:** This retrospective, interventional, consecutive case series included 20 eyes with persistent MH after previous standard MH surgery. All eyes underwent vitrectomy, lens anterior or posterior capsule transplantation into the MH, gas tamponade, and a 1-week postoperative head down. Structural and functional changes were evaluated.

**Results:** The predisposing conditions to surgical failure included high myopia with MH and retinal detachment in four eyes, MH after myopic foveoschisis surgery in one eye, high myopia with a large MH in one eye, proliferative diabetic retinopathy with MH in three eyes, MH with severe retinal detachment in one eye, retinal detachment with concurrent peripheral breaks and MH in one eye, and large or chronic MH in nine eyes. Macular hole was closed in all the 10 eyes receiving anterior capsular flap transplantation. In the 10 eyes with posterior capsular flap transplantation, MH was closed in 5, partially closed in 3, and not closed in 2. Visual acuity in logarithm of minimal angle of resolution improved from  $1.53 \pm 0.39$  preoperatively to  $1.07 \pm 0.35$  postoperatively.

**Conclusion:** Lens capsular flap transplantation may close the MH and improve visual outcome in the majority cases of refractory MH.

RETINA 36:163–170, 2016

---

Pars plana vitrectomy with posterior hyaloid removal, internal limiting membrane (ILM) peeling, and gas tamponade has been the standard treatment technique for full thickness macular hole (MH). Although the closure rate of idiopathic MH may reach 90% or higher, there are still around 10% of cases that fail to have MH resolved after vitrectomy.<sup>1,2</sup> The failure rate of hole closure is considerably higher in cases with

high myopia,<sup>3–5</sup> chronic MH,<sup>6</sup> or other nonidiopathic conditions.<sup>7,8</sup> For high myopia-associated MH and retinal detachment, the hole closure rate in the retina reattachment group has been found to range from 10% to 44% only.<sup>3</sup> For foveoschisis-associated MH, the success rate is also low at around 25%.<sup>4</sup> The MH closure rate in eyes with an axial length greater than 26 mm is around 62.5%,<sup>5</sup> similar to the closure rate in chronic MH.<sup>6</sup> A persistent hole not only impedes visual recovery but also runs the risk of retinal detachment in a high myopic eye. Current treatment strategies to decrease the likelihood of persistent hole with primary surgery include a larger area of ILM peeling or the inverted ILM flap technique.<sup>9</sup> If the hole remains open after surgery, the ILM free flap has been used during a second surgical procedure.<sup>10</sup> However, the ILM free flap may not be readily available, and the insertion of the ILM fragment into the hole is technically demanding. We hypothesized that

---

From the \*Department of Ophthalmology, Changhua Christian Hospital, Changhua, Taiwan; †School of Medicine, Kaohsiung Medical University, Kaohsiung, Taiwan; ‡School of Medicine, Chung-Shan Medical University, Taichung, Taiwan; §Department of Ophthalmology, National Taiwan University Hospital and College of Medicine, National Taiwan University, Taipei, Taiwan; and ¶College of Medicine, National Taiwan University, Taipei, Taiwan.

None of the authors have any financial/conflicting interests to disclose.

Reprint requests: Chung-May Yang, MD, Department of Ophthalmology, National Taiwan University Hospital and College of Medicine, National Taiwan University, 7, Chung Shan South Road, Taipei, Taiwan; e-mail: chungmay@ntu.edu.tw

Table 1. Demographic Data of Patients

| Patient No/Age (years)/Sex | F/U Duration, months | Primary Disease           | Duration From Previous Surgeries | Size of MH ( $\mu\text{m}$ ) Before Flap Transplant | MH Status After Flap Transplant | Before Initial Surgery | VA Before Flap Transplant | Final VA | Type of Flap/Gas Used           |
|----------------------------|----------------------|---------------------------|----------------------------------|---|---------------------------------|------------------------|---------------------------|----------|---------------------------------|
| 1/78/F                     | 6                    | Old MH                    | 1 year                           | 859   | Partial C                       | 0.02                   | 0.02                      | 0.02     | P/C <sub>3</sub> F <sub>8</sub> |
| 2/69/M                     | 5                    | MHRD, high myopia         | 3 years                          | 815   | C                               | 0.01                   | 0.05                      | 0.2      | P/C <sub>3</sub> F <sub>8</sub> |
| 3/65/F                     | 6                    | PDR                       | 6 months                         | 548   | C                               | 0.01                   | 0.02                      | 0.05     | A/SF <sub>6</sub>               |
| 4/77/F                     | 3                    | Old MH                    | 7 months                         | 904   | C                               | 0.1                    | 0.1                       | 0.2      | A/SF <sub>6</sub>               |
| 5/58/M                     | 4                    | Recurrent RD with PVR     | 1 year                           | 415   | Not C                           | HM                     | 0.02                      | 0.1      | P/C <sub>3</sub> F <sub>8</sub> |
| 6/63/M                     | 3                    | Old MH                    | 3 months                         | 533   | C                               | 0.05                   | 0.05                      | 0.2      | p/C <sub>3</sub> F <sub>8</sub> |
| 7/67/M                     | 4                    | Foveoschisis, high myopia | 14 months                        | 1058  | C                               | 0.1                    | 0.05                      | 0.2      | P/SF <sub>6</sub>               |
| 8/60/F                     | 5                    | Large MH, high myopia     | 3 months                         | 756   | C                               | 0.02                   | 0.02                      | 0.2      | A/SF <sub>6</sub>               |
| 9/76/M                     | 4                    | Old MH                    | 6 years                          | 642   | C                               | 0.15                   | 0.15                      | 0.2      | A/C <sub>3</sub> F <sub>8</sub> |
| 10/79/M                    | 3                    | Old MH                    | 8 years                          | 1053  | C                               | 0.02                   | 0.02                      | 0.1      | A/SF <sub>6</sub>               |
| 11/62/F                    | 3                    | MHRD, high myopia         | 2 years                          | 616   | C                               | CF                     | 0.01                      | 0.01     | P/C <sub>3</sub> F <sub>8</sub> |
| 12/57/F                    | 4                    | RD with MH                | 2 years                          | 933   | C                               | CF                     | 0.02                      | 0.1      | P/C <sub>3</sub> F <sub>8</sub> |
| 13/62/F                    | 3                    | Old MH                    | 6 months                         | 756   | C                               | 0.02                   | 0.02                      | 0.1      | A/SF <sub>6</sub>               |
| 14/71/F                    | 4                    | MHRD, high myopia         | 22 months                        | 1230  | C                               | 0.01                   | 0.02                      | 0.1      | A/SF <sub>6</sub>               |
| 15/64/M                    | 3                    | Old MH                    | 4 years                          | 690   | C                               | 0.1                    | 0.1                       | 0.15     | A/C <sub>3</sub> F <sub>8</sub> |
| 16/57/F                    | 6                    | MHRD, PDR                 | 18 months                        | 830   | C                               | CF                     | 0.05                      | 0.15     | P/C <sub>3</sub> F <sub>8</sub> |
| 17/70/M                    | 3                    | MHRD, PDR                 | 10 months                        | 664   | C                               | 0.01                   | 0.01                      | 0.05     | A/C <sub>3</sub> F <sub>8</sub> |
| 18/56/M                    | 4                    | Old MH                    | 1 year, 8 months                 | 800   | Partially C                     | 0.1                    | 0.16                      | 0.16     | p/C <sub>3</sub> F <sub>8</sub> |
| 19/63/M                    | 5                    | MH, high myopia           | 6 months                         | 663   | C                               | 0.02                   | 0.02                      | 0.15     | A/C <sub>3</sub> F <sub>8</sub> |
| 20/54/F                    | 4                    | Old MH                    | 4 years                          | 1010  | Partially C                     | 0.05                   | 0.03                      | 0.05     | P/SF <sub>6</sub>               |

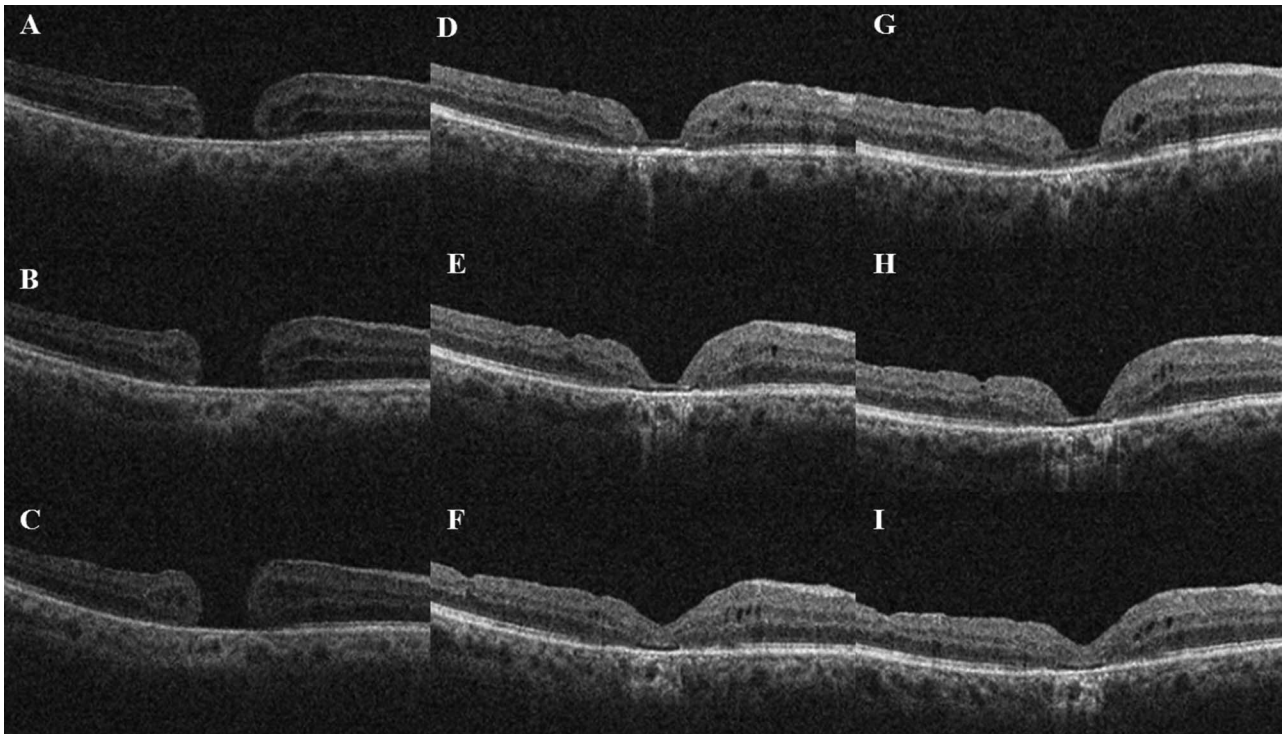
A, anterior capsule; C, closed; CF, counting finger; HM, hand motion; MHRD, macular hole-associated retinal detachment; P, posterior capsule; PDR, proliferative diabetic retinopathy; RD, retinal detachment; SO, silicone oil; VA, best corrected decimal visual acuity.

a piece of crystalline lens capsule inserted into the hole may bridge the hole edge and facilitate hole closure. Herein, we report a case series of persistent MH in which anterior or posterior lens capsule fragments were plugged into the hole to close the hole.

### Materials and Methods

This is a two-center, retrospective, consecutive case series conducted in the Changhua Christian Hospital and National Taiwan University Hospital. Only eyes with persistent MH previously receiving vitrectomy, ILM peeling, and gas-fluid exchanges without hole closure were included. At the initial surgery, each patient had undergone a 23-gauge vitrectomy. After core vitrectomy and triamcinolone acetonide-assisted (2.5 mg/mL) posterior hyaloid removal, a small amount of VisCoat (Alcon-Couvreur N.V., Rijksweg, Puurs, Belgium) was placed in the hole to prevent the indocyanine green (ICG) from making contact with the retinal pigment epithelium later in the procedure.

Indocyanine green (25 mg of ICG diluted with 15 mL of 5% glucose water to yield a concentration of 1.7 mg/mL) was then carefully applied around the VisCoat-coated area within the arcade. Excessive ICG was immediately removed by suction. As the 2 substances, VisCoat and 5% glucose water-diluted ICG solution, were both slightly greater in density than the balanced salt solution (BSS), they could be applied to the designated areas in a more controlled fashion. Either a barbed 25-gauge needle or direct forceps grasping was then used to create an ILM break within the ICG-stained area. Internal limiting membrane peeling centering on the fovea was performed in a circular manner across the macula for the whole area within the arcade. The peripheral retina was then examined for possible breaks followed by air-fluid exchange and 13% C<sub>3</sub>F<sub>8</sub> infusion into the vitreous cavity. The patients were kept in a prone position for approximately 1 week. Using the standard techniques, the anatomical success rate of idiopathic MH had been above 90% for both authors (unpublished data).



**Fig. 1.** A 62-year-old female patient (Case 13) had chronic MH for several years. The hole persisted after vitrectomy, ILM peeling, and gas–fluid exchange (A–C, three successive horizontal cuts). Repeated vitrectomy combined with phacoemulsification and anterior capsular transplantation was performed 6 months after the first surgery. Optical coherence tomography showed the hole was closed 4 weeks later (D–F, 3 successive horizontal cuts). Further centrifugal migration of foveal tissue was noted 2 months later (G–I, 3 horizontal cuts). Visual acuity improved from 0.02 preoperatively to 0.1 at the final visit.

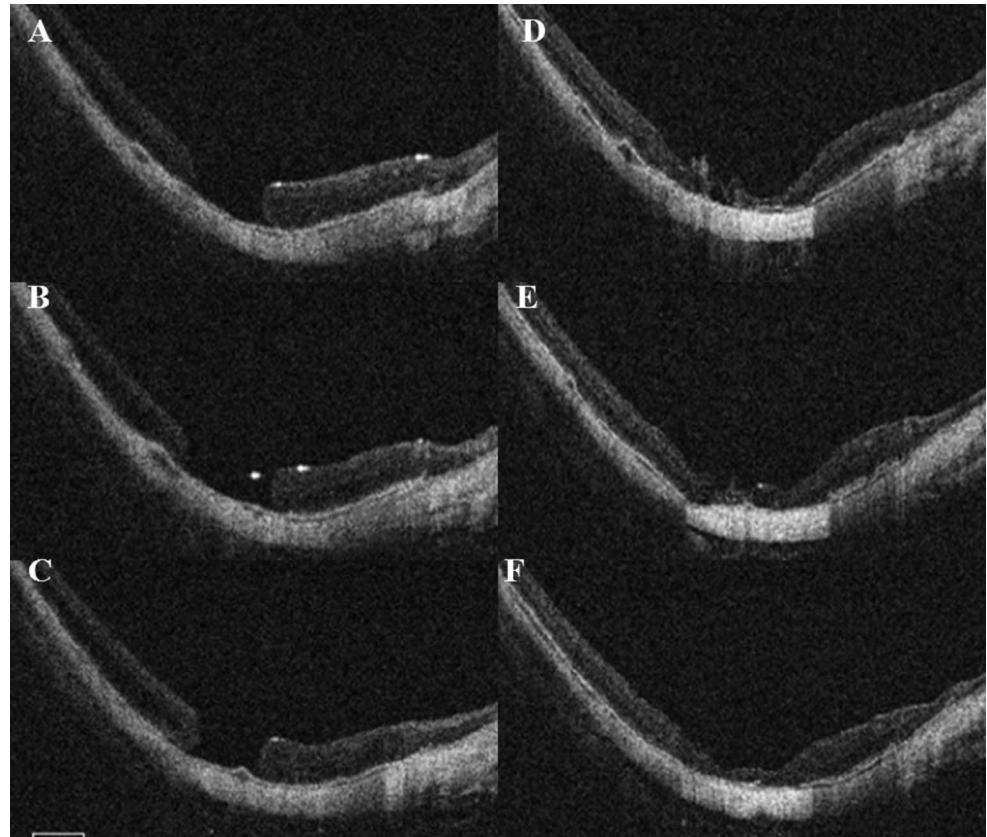
The study adhered to the tenets of the declaration of Helsinki and was approved by the institutional review boards of both hospitals. Patients were informed about the benefits and risks of surgery, and written informed consents were obtained from the patients for the surgical procedures. Best corrected visual acuity and optical coherence tomography (Cirrus HD-OCT; Carl Zeiss Meditec, Inc, Dublin, CA in Changhua Christian Hospital and National Taiwan University Hospital, and RTvue; Optovue Inc, Fremont, CA, in National Taiwan University Hospital) were performed on each visit. All patients were followed up at outpatient clinics for at least 3 months postoperatively.

#### *Surgical Procedures*

*Parse Plana Vitrectomy.* Standard 23-gauge pars plana vitrectomy was performed in all cases. All eyes had capsular flap transplantation to the MH. The capsular flap was harvested from the lens posterior capsule or anterior capsule and was stained with 0.125% ICG before transplantation for better visualization. The choice of anterior or posterior capsule as the free flap was depended on the patients' lens status. In phakic eyes, combined

phacoemulsification procedures were performed, and the anterior capsule was used as the free flap. For pseudophakic eyes, the posterior capsule was used. The flap was made and trimmed to a size a little larger than that of the MH and was placed within the hole with microforceps. Its proper position was secured by trapping the edge of the flap under the edge of the MH. No effort was made to select a specific side of the flap to place against the retinal pigment epithelium. The flap was gently grasped with the microforceps for its delivering into the vitreous cavity. The infusion was temporarily turned off during the microforceps entrance to prevent flap torn by the fluid stream. After the tip of the microforceps was in the mid-vitreous cavity, the infusion line was reopened and the intraocular pressure set at 20 mmHg; a few seconds were given for stabilizing the fluid flow before further manipulation. The lens capsular flap was then released from the microforceps and allowed to settle gently on the posterior retinal surface. After the flap was manipulated into proper position, fluid–air exchange was performed. The procedures were initiated by first pumping the air into the vitreous cavity without removing the instruments. Only after the air bubble had covered the

**Fig. 2.** Results of autologous posterior capsular transplantation in a 67-year-old excessive myopic patient (Case 7). He had foveoschisis initially and developed an MH after vitrectomy and ILM peeling for foveoschisis. Despite repeated vitrectomy and silicone oil tamponade, the hole persisted (A–C, three successive horizontal cuts). He received silicone oil removal and posterior capsule transplantation 8 months later. Optical coherence tomography 4 weeks after the transplantation showed the hole was closed (D–F, 3 horizontal cuts). His visual acuity improved from 0.05 before the transplantation to 0.2 at the final visit.



cannulas were the microforceps withdrawn and backflush needle inserted. This manipulation was used to keep turbulence to a minimum during instrument exchange. The intraocular pressure was kept around 30 mmHg, and the aspiration of fluid was slowly performed. No complete fluid–air exchange was intended to minimize disturbance to the flap in place. Proper position of the flap was indicated by the green spot at the MH at the end of the surgery.

Either 25% SF<sub>6</sub> or 13% C<sub>3</sub>F<sub>8</sub> was used for gas tamponade. The patients were asked to maintain a head-down or prone position for 1 week to 2 weeks.

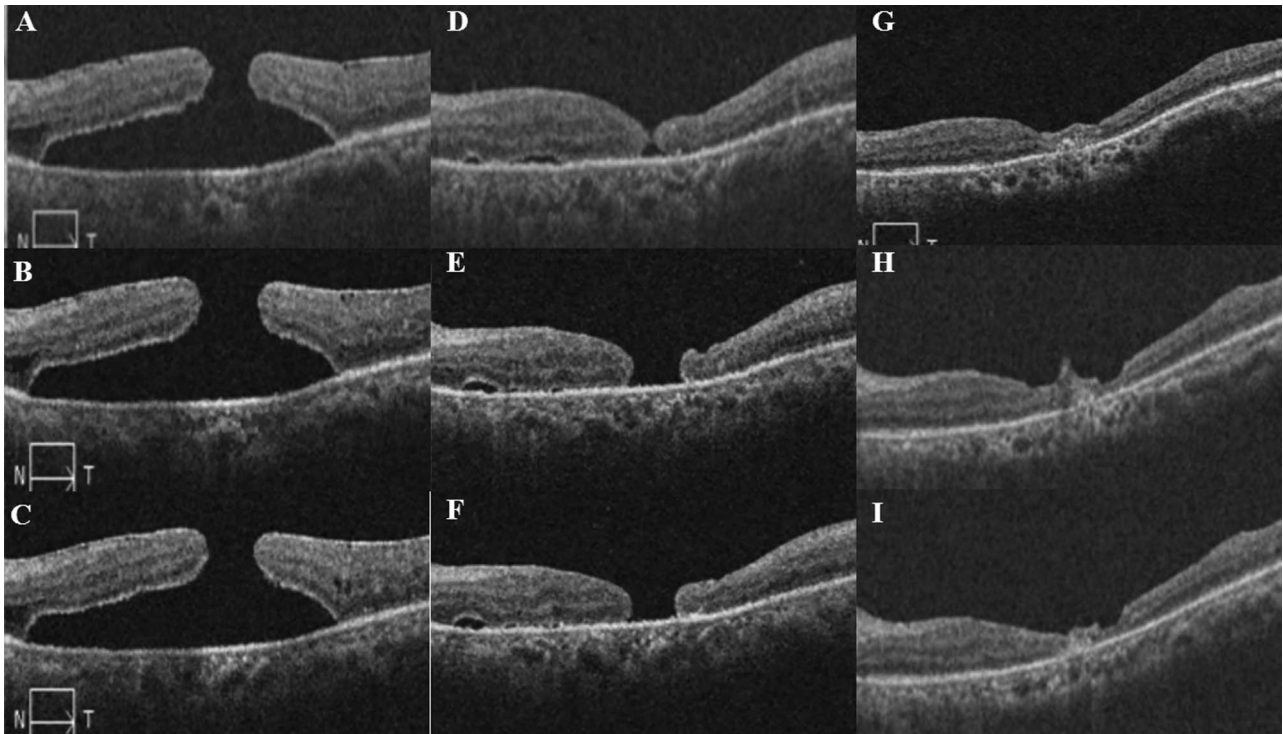
#### *Harvest of the Anterior Capsular Flap and Its Insertion Into the Hole*

Combined cataract surgery was performed in phakic patients. After the circular anterior capsular flap from anterior circular continuous capsulorhexis was obtained, it was stained with 0.125% ICG and was preserved in a balanced salt solution for later use. The anterior capsule was more rigid and easier to manipulate than the ILM. Furthermore, because of its greater specific gravity, it would sink down to the preretinal surface after being released from the tips of the microforceps instead of floating within the

vitreous cavity as was often observed in the case of ILM flaps. Before transplantation, the flap was trimmed to a size a little larger than that of the MH with either microforceps and scissors or the vitrectomy probe in a shaving mode.

#### *Harvest of the Posterior Capsular Flap*

A bent 25-gauged needle tip was used to make an incision at the center of the posterior capsule if there had been no preexisting opening in the posterior capsule. The intraocular microforceps and scissors were used to create a free flap either by tearing the capsule in a continuous curvilinear capsulorhexis-like manner or simply by grasping and isolating a piece of posterior capsule. The posterior capsule was stained with 0.125% ICG either by instilling the dye into the bag behind the intraocular lens before the harvest of the flap (as long as the capsule was intact and too transparent for good visualization) or by staining the flap outside the eye after harvesting the flap. In eyes with posterior capsule fibrosis, the flap was often more rigid and easier to manipulate, which was then trimmed into the proper size (slightly larger than that of the MH) and inserted to the MH in the same way that the anterior capsular flap was treated. If there was



**Fig. 3.** A 57-year-old female patient presented with proliferative diabetic retinopathy, and MH-associated retinal detachment in the right eye (A–C, 3 successive horizontal cuts). The MH and retinal detachment persisted after vitrectomy, delamination of fibrous tissue, ILM peeling, and air–fluid exchange. The retina was reattached with persistent MH (D–F, three horizontal cuts) after another surgery with silicone oil tamponade. Eighteen months later, after posterior capsular transplantation, silicone oil removal, and gas tamponade, the hole was sealed with the retina attached (G–I, three horizontal cuts).

no posterior capsular fibrosis, the posterior capsule would be pliable and tended to curl up and thus sometimes required more than one piece of flap to completely fill the hole. Similar to the anterior capsule, the posterior capsule was heavier than the balanced salt solution and usually sank down to the preretinal surface after release from the tip of the microforceps.

#### *Definition of Closed Macular Hole, Partially Closed Macular Hole, and Unclosed Macular Hole*

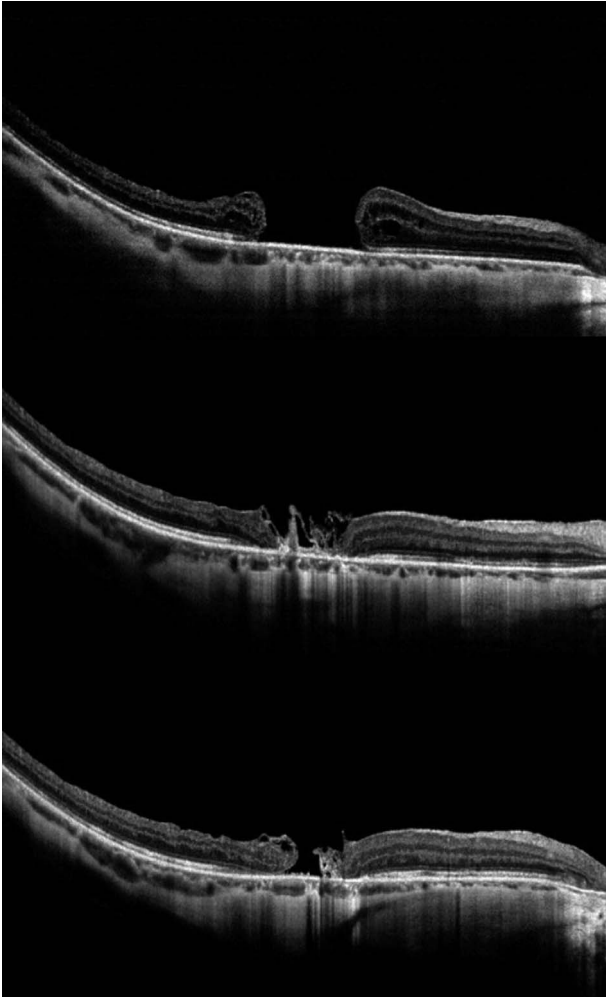
Optical coherence tomography was used to examine the macular conditions after surgery. We defined closed MH as a MH closed without any exposure of the bare retinal pigment epithelium; partially closed MH was defined as a MH decreased in size as compared with the preoperative condition with part of its edge in contact with the retinal pigment epithelium. Unclosed MH was defined as a MH that had the same size or even larger size than that of the preoperative one.

**Statistics.** Best corrected visual acuity recorded as decimal visual acuity was converted to logarithm of minimal angle of resolution (logMAR) value for statistics. The preoperative and postoperative best corrected visual acuity was compared with the paired

*t*-test using SPSS software (SPSS, Inc, Chicago, IL). A *P* value of less than 0.05 was considered statistically significant. The chi-square test was used to compare the closure rate, and an independent sample *t*-test was used to compare whether there was any difference in visual acuity changes between eyes receiving anterior capsular flap and those having posterior capsular flap transplantation.

## Results

A total of 20 cases (20 eyes in 20 patients; 10 men and 10 women) were enrolled in this study. The demographic data are listed in Table 1. The average age was  $65.40 \pm 7.74$  years (range, 54–79 years), and the average size of the MH before the surgery was  $788.80 \pm 198.11 \mu\text{m}$  (range, 415–1230  $\mu\text{m}$ ). The duration from the previous surgeries varied greatly ranging from 3 months to 96 months (mean,  $24.35 \pm 14.67$  months). The initial conditions associated with the MH formation also varied: high myopia with MH and retinal detachment in four eyes, MH after myopic foveoschisis surgery in one eye, high myopia with a large MH in one eye, proliferative diabetic retinopathy with MH in three eyes, MH complicating



**Fig. 4.** A 54-year-old female patient had a history of MH in the right eye for 5 years. She received two previous surgeries of vitrectomy, ILM peeling, gas tamponade, and phacoemulsification, but the hole persisted (top). She received posterior capsular transplantation 4 years after the previous surgery. The hole was closed 2 weeks after this surgery (middle), and her vision improved from 0.02 to 0.05. Although the hole reopened 1 month later, the size of MH was comparatively smaller than before the transplantation. Visual acuity remained at 0.05 after 4 months of the transplantation.

proliferative vitreoretinopathy in one eye, retinal detachment with concurrent peripheral retinal breaks and MH in one eye, and large or chronic MH in nine eyes. Ten eyes had combined phacoemulsification and anterior capsular flap transplantation, whereas 10 eyes with previous phacoemulsification procedures had posterior capsule as the free flap. Macular hole was closed in 15 eyes, partially closed in 3 eyes and not closed in 2 eyes. In the 10 eyes with anterior capsular flap transplantation, the hole was closed in all (Figure 1). For eyes with posterior capsular flap transplantation, the hole was completely closed in 5 eyes (Figures 2 and 3), partially closed in 3 eyes (Figure 4) and unclosed in 2 eyes. The common characteristics

for the eyes without closed holes were that all of the five eyes either had a nonfibrotic posterior capsule or that only a sparse curled posterior capsular flap could be obtained, which could not properly fill the hole in one piece. In the follow-up optical coherence tomography, the flap appeared dislodged after the operation and no flap was visible in the optical coherence tomography image in the two eyes without closed holes. In one eye with a partially closed hole, the hole was initially closed (Case 20, Figure 4) but later reopened, leaving a hole smaller in size as compared with the preoperative status. The averaged VA in logMAR before and after the transplantation was  $1.53 \pm 0.39$  and  $1.07 \pm 0.35$ , respectively ( $P = 0.04$ , paired *t*-test). Eyes in the anterior capsule group had a significantly better closure rate (Table 2,  $P = 0.04$ , chi-square test) but did not have a significantly better visual improvement than eyes in the posterior capsule group (Table 2,  $P = 0.66$ , independent sample *t*-test). The postoperative best corrected visual acuity gained 0.2 logMAR units or more in 14 eyes and remained unchanged in 6 eyes. No eyes had deteriorated best corrected visual acuity. The surgical complications included transient elevated intraocular pressure postoperatively in 1 eye (32 mmHg), which was rapidly brought under control with antiglaucomatous agents.

## Discussion

Vitrectomy with or without ILM peeling is commonly used to treat MH, and although the closure rate is high, persistent MH remains a problem. ILM free flap insertion into the hole has been advocated to facilitate hole closure in the refractory cases.<sup>10</sup> However, the technique of peeling the peripheral ILM may sometimes be very difficult in cases whose ILM had already been peeled within the arcade in the previous surgeries or only shreds of ILM can be obtained. Furthermore, the ILM fragment tends to float into the vitreous cavity, and the ILM flap can be easily lost during the manipulation. In our study, the application of crystalline lens capsular flap, a similar concept as the ILM free flap method was shown to provide an alternative way for the treatment of refractory MH.

Similar to ILM, lens capsule is a basement membrane in nature. It is thicker than the ILM but still possesses a pliable consistency. The advantage of a lens capsule flap is its higher density compared with the ILM making it easier to settle down on the retinal surface and be directed to the designated place. Another advantage of this technique was the easy feasibility of capsular tissue. Before the second surgery, most cases were either pseudophakic or had cataract requiring lens extraction.

Table 2. Comparison of Patients Receiving Anterior or Posterior Capsule Flap Transplantation

|                          | Anterior Capsule (n = 10) | Posterior Capsule (n = 10) | P     |
|--------------------------|---------------------------|----------------------------|-------|
| Age                      | 68.70 ± 6.86              | 62.10 ± 7.43               | 0.05* |
| Size of MH               | 790.70 ± 210.90           | 786.90 ± 206.72            | 0.97* |
| Pre-VA logMAR            | 1.58 ± 0.36               | 1.47 ± 0.34                | 0.27† |
| Post-VA logMAR           | 1.09 ± 0.31               | 1.05 ± 0.49                | 0.83* |
| Improvement of VA logMAR | 0.49 ± 0.35               | 0.42 ± 0.34                | 0.66* |
| Hole closure (%)         |                           |                            | 0.04‡ |
| Closed                   | 10 (100)                  | 5 (50)                     |       |
| Partially                | 0                         | 3 (30)                     |       |
| Not closed               | 0                         | 2 (20)                     |       |

\*Independent-samples *t*-test.

†Nonparametric two-sample *t*-tests (Mann-Whitney *U* test).

‡Chi-square test.

Pre-VA logMAR, best corrected visual acuity in logarithm of minimal angle of resolution before operation; Post-VA logMAR, best corrected visual acuity in logarithm of minimal angle of resolution after operation.

In the former condition, the posterior capsule was easy to obtain, whereas in the latter condition, the anterior capsule was readily available after circular continuous capsulorhexis. In addition to anatomical improvement, we also noted a mean improved visual acuity. Although a concomitant cataract surgery in the anterior capsular group may make the postoperative visual improvement ( $0.49 \pm 0.35$  in logMAR) more difficult to interpret, visual improvement was also observed in eyes with posterior capsular transplantation ( $0.42 \pm 0.34$  in logMAR), in which no concomitant cataract surgery was performed. This finding indicates that the technique had a positive effect on visual function.

The disadvantage of lens capsule fragment is its transparency, which makes it difficult to be seen clearly unless it is stained with some vital dye. The dye-staining procedure, however, may raise the concern of retinal toxicity. In this study, we used a very low concentration of ICG in an attempt to minimize the possibility of toxicity to a minimum, and most of our patients had improved vision after a successful hole closure. Although potential risks do exist, compared with even greater disadvantage with an open large break, this may be an acceptable compromise.

In this study, we noted that all the failed cases had posterior capsule as the flap tissue. Given that the posterior capsule, if not fibrotic, tended to curl into a small roll instead of a flat sheet as was the anterior capsular flap, the flap prepared may sometimes not have been large enough to fill the whole MH. In this case, it was also more difficult to secure the friable tissue under the hole margin, making flap dislodgement from the MH occur more easily during the postoperative period. Optical coherence tomographic images in our two failed cases that showed no evidence of capsular flap within the hole might have been the result of this drawback. The anterior capsule flap, in contrast, is more rigid. It is easy to

obtain a single sheet of tissue large enough in size to fill the whole MH area and trap the flap under the edge of the hole to stabilize it. Another disadvantage of using the posterior capsule flap is that because sometimes more than one flap was necessary to fill the hole, the flaps would curl up and separate from each other, thereby losing their bridging effect. This change may explain why one of our cases receiving posterior capsular flap transplantation initially had a closed MH, which later reopened. Whether a prolonged head-down position may be helpful requires further study. One concern of lens capsular transplantation is the possibility of lens epithelial cell proliferation and its effect on the macular structure. Although we did not find any lens epithelial cell-related complications in this series, long-term follow-up is needed to address this issue.

The limitations of the study are its retrospective nature, small patient number, and the short-term follow-up. However, this is the first case series using lens capsule to treat persistent MH. We found that lens capsular free flap is useful in closing chronic large-sized MH with previous MH surgeries in various kinds of predisposing conditions. A prospective study with a larger number of patients and longer follow-up time is necessary to further establish the advantages of this technique and to see whether there are complications in the long run.

**Key words:** macular hole, lens capsular flap.

#### Acknowledgments

The authors would like to thank Dr. Yu-Chih Hou from National Taiwan University for the technical support in harvesting the anterior capsule, and Dr. Chang-Hao Yang from National Taiwan University for providing critical opinion in conducting the surgical procedures.

### References

1. Brooks HL Jr. Macular hole surgery with and without internal limiting membrane peeling. *Ophthalmology* 2000;107:1939–1948.
2. Ip MS, Baker BJ, Duker JS, et al. Anatomical outcomes of surgery for idiopathic macular hole as determined by optical coherence tomography. *Arch Ophthalmol* 2002;120:29–35.
3. Ichibe M, Yoshizawa T, Murakami K, et al. Surgical management of retinal detachment associated with myopic macular hole: anatomic and functional status of the macula. *Am J Ophthalmol* 2003;136:277–284.
4. Ikuno Y, Tano Y. Vitrectomy for macular holes associated with myopic foveoschisis. *Am J Ophthalmol* 2006;141:774–776.
5. Wu TT, Kung YH. Comparison of anatomical and visual outcomes of macular hole surgery in patients with high myopia vs. non-high myopia: a case-control study using optical coherence tomography. *Graefes Arch Clin Exp Ophthalmol* 2012;250:327–331.
6. Thompson JT, Sjaarda RN, Lansing MB. The results of vitreous surgery for chronic macular holes. *Retina* 1997;17:493–501.
7. Yeh PT, Cheng CK, Chen MS, et al. Macular hole in proliferative diabetic retinopathy with fibrovascular proliferation. *Retina* 2009;29:355–361.
8. Ghoraba H. Types of macular holes encountered during diabetic vitrectomy. *Retina* 2002;22:176–182.
9. Michalewska Z, Michalewska J, Adelman RA, Nawrocki J. Inverted internal limiting membrane flap technique for large macular holes. *Ophthalmology* 2010;117:2018–2025.
10. Morizane Y, Shiraga F, Kimura S, et al. Autologous transplantation of the internal limiting membrane for refractory macular holes. *Am J Ophthalmol* 2014;157:861–869.