

Five-Year Trends in Multifocal Electroretinogram for Patients With Birdshot Chorioretinopathy



ADRIANE MAILHAC, JOSÉ LABARERE, FLORENT APTEL, SYLVIE BERTHEMY,
LAURENCE BOUILLET, AND CHRISTOPHE CHIQUET

- **PURPOSE:** The aim of this study is to investigate temporal trends in multifocal ERG (mfERG) parameters and analyze their relationships with anatomic and functional markers in patients with birdshot chorioretinopathy (BSCR).
- **DESIGN:** Prospective observational case series.
- **METHODS:** Sixteen BSCR patients were included and underwent 2 standardized follow-up (FU) visits within 5 years following a baseline examination, including mfERG, visual acuity (VA), visual field (VF), Lanthony desaturated panel D-15 test for color vision, quality of life (QoL), fluorescein and indocyanine green angiography, and optical coherence tomography (OCT).
- **RESULTS:** A significant trend toward a decrease in absolute N1 amplitude values was observed over the follow-up period ($P < .001$) while N1 implicit time remained unchanged. In contrast, P1 amplitude decreased ($P < .001$) and P1 implicit time increased ($P < .001$) over the same period. No significant temporal change was found for VA, color vision score, foveal threshold, mean deviation of VF, and QoL. After adjusting for time to FU, increasing N1 and P1 IT were both associated with decreasing values of logMAR, foveal threshold, and QoL and with increasing color vision score and mean deviation of VF. A significant relationship was observed between decreasing P1 amplitude values and increasing mean deviation of VF. Lower absolute values of N1 amplitude were associated with venous vasculitis, whereas lower P1 amplitude values correlated with alteration of the outer retina in OCT.
- **CONCLUSIONS:** Progressive deterioration in mfERG during a 5-year period is detected in BSCR, whereas classical functional test results were unchanged. This study suggests a better sensitivity of mfERG in monitoring the retinal function of BSCR patients. (Am J

Ophthalmol 2019;200:138–149. © 2019 Elsevier Inc. All rights reserved.)

BIRDSHOT CHORIORETINOPATHY (BSCR) IS A POSTERIOR autoimmune uveitis, usually symmetric, and strongly associated with human leukocyte antigen A 29. BSCR accounts for 0.5%-1.5% of uveitis, with a higher female prevalence and a mean age of symptom onset of 53 years.¹ BSCR has an insidious progression and can cause a significant visual loss owing to various complications, including macular edema, diffuse retinal atrophy, epiretinal membrane, and/or choroidal neovascularization.

Because visual acuity (VA) may remain stable despite steadily progressive deterioration of retinal function,² it lacks sensitivity for detecting or monitoring patients with BSCR. Several functional and imaging technologies have been proposed for monitoring BSCR,³ including visual field,⁴ color vision,⁵ standard electroretinography,^{3,6–8} fluorescein (FA) and indocyanine green (ICGA) angiography, and optical coherence tomography (OCT).^{9,10} Yet these tests yield limited accuracy or reliability for assessing disease activity. This explains why monitoring BSCR patient remains challenging in routine practice.

Because electrophysiologic testing may detect early functional changes, its use has been advocated for monitoring disease progression in uveitis.¹¹ Three types of electroretinogram (ERG) are currently used in the clinical setting: full-field, pattern, and multifocal ERGs. Multifocal ERG (mfERG) is a noninvasive method for objectively measuring retinal function within localized patches, especially the central retina, that is, up to 45 degrees of eccentricity around the central foveal area. Multifocal ERG waveform can be understood as a combination of overlapping ON- and OFF-bipolar cell contributions combined with smaller contributions from inner retina and photoreceptors.¹² Many studies have reported on the diagnostic and prognostic values of full-field ERG parameters for BSCR, including the light-adapted 30-Hz flicker response.^{6–8} In contrast, only 2 cross-sectional studies investigated the value of mfERG in BSCR.^{13,14} Birch and associates¹³ reported (1) lower mfERG responses for 6 eyes with macular atrophy compared to 8 eyes without macular thinning and (2) abnormal mfERG responses for patients with BSCR evolving for 10 years or more. Using

AJO.com

Supplemental Material available at AJO.com.

Accepted for publication Nov 30, 2018.

From Grenoble Alpes University, Grenoble, France (A.M., J.L., F.A., S.B., L.B., C.C.); Departments of Ophthalmology (A.M., F.A., C.C.) and Internal Medicine (L.B.), Grenoble Alpes University Hospital, Grenoble, France; and Quality of Care Unit, CIC 1406 INSERM, University Hospital, Grenoble, France (J.L.).

Inquiries to Prof. Christophe Chiquet, Department of Ophthalmology, Grenoble Alpes University Hospital, CS 10217, 38043 Grenoble cedex 09, France; e-mail: christophe.chiquet@inserm.fr

a cross-sectional study design, Chiquet and associates¹⁴ showed that amplitudes (AMP) and implicit times (IT) of the mfERG parameters were impaired in BSCR patients and were associated with other anatomic and functional test findings. In contrast to full-field ERG, mfERG explores cone-driven light-adapted retinal function and provides objective assessment of central retinal function in different retinal areas within a short time frame. Furthermore, the multifocal technique may provide useful insights into the mechanisms of BSCR, since the N1 wave represents the hyperpolarization of cones and the P1 wave represents the depolarization of bipolar cells. Yet the value of mfERG for monitoring BSCR patients remains to be established and prospective longitudinal studies are warranted for this purpose.

This prospective cohort study of BSCR patients with a 5-year follow-up (FU) period aimed to investigate temporal trends in mfERG parameter values and elucidate their relationships with anatomic and functional tests.

METHODS

- **STUDY DESIGN:** As part of a prospective observational case series of BSCR, the present analysis focused on consecutive adult patients who were monitored at baseline and at 3 and 5 years of FU, using mfERG, in Grenoble Alpes University Hospital. This study complied with the Declaration of Helsinki guidelines for research involving human subjects and was approved by the local Institutional Review Board (IRB 00008855). All study participants provided written informed consent for conducting all ophthalmologic examinations.

- **PATIENTS:** All patients met the 2006 International Consensus Conference research criteria for diagnosis of BSCR,¹⁵ were older than 18 years, and had no medical contraindications for performing FA and ICGA. They were recruited between January 2008 and December 2010.

- **DATA COLLECTION:** Baseline characteristics and FU data were prospectively collected, including measurement of VA (ETDRS chart), a 30-2 Swedish Interactive Threshold Algorithm (SITA) standard program on the Humphrey Field Analyzer (Carl Zeiss Meditec Inc, Dublin, California, USA), and a Lanthony desaturated panel D-15 test for color vision under standardized conditions of ambient illumination, with calculation of the total error score.^{16,17} All patients had a reliable visual field test, defined as a false-positive error <15%, a false-negative error <15%, and a fixation loss <20%. Quality of life (QoL) was assessed using the cross-cultural adaptation of the NEI Visual Function Questionnaire (VFQ-25) in French.¹⁸

Anatomic testing was based on FA, ICGA (Heidelberg, Germany), and optical coherence tomography (OCT) (spectral-domain [SDOCT]; Carl Zeiss Meditec, Inc, or Heidelberg Engineering, Heidelberg, Germany). Angiographic data were evaluated in a masked fashion by 2 independent investigators^{19,20} and included optic disc hyperfluorescence, macular edema, retinal vascular staining and/or leakage (with an extension varying between 0 and 4 related quadrants), peripheral capillary leakage (extension: 0-4 quadrants), and posterior capillary leakage. Retinal vasculitis was defined as fluorescein staining of any retinal vessels proximal to the third bifurcation.²¹ ICGA criteria were presence of hypocyanescence areas at the intermediate frame (10 min after the ICG injection).²⁰

OCT data collected were central macular thickness (CMT), alteration of outer retina, and macular edema (ME). We defined ME in time-domain OCT (TDOCT) as CMT over 260 μm and in SDOCT as CMT over 295 μm .^{22,23} Other ME features included cystoid macular edema (CME), consisting of low-reflective intraretinal spaces, clearly defined and separated by thin, high-reflective retinal tissue; diffuse ME, consisting of increased macular thickness; and small low-reflective areas with spongy appearance of the retinal layers. We defined alterations of the outer retina by the presence of a defect of at least 1 of 4 hyperreflective outer retinal bands: the external limiting membrane (ELM); the ellipsoid portion of the inner segments (ellipsoid band); the cone outer segment/contact cylinder region (cone OS); and the retinal pigment epithelium (RPE).^{24,25} CMT was defined as the mean retinal thickness within the 1-mm central subfield.

Each patient was followed using the same OCT machine. Patients initially included in 2008 had TDOCT at baseline and were followed by TDOCT over 5 years and SDOCT from 2010. Cirrus measurement was defined as the reference measurement, and we used the conversion table to convert Stratus (Cirrus = Stratus \times 1 + 55.6) and Heidelberg measurements (Cirrus = Spectralis \times 0.8 + 36.4) into Cirrus CMT.²⁶

Severity of the disease and progression of inflammation were based on anatomic (fluorescein and ICG angiography, OCT) and functional (VA, visual field parameters) examinations.

Multifocal ERG (Vision Monitor; Métrivision, Pérenchies, France) was performed according to the International Society for Clinical Electrophysiology of Vision (ISCEV) protocol,²⁷ using a 61 hexagon strategy and scaled hexagons. Stimulations were generated on a cathode ray tube monitor with a 120-Hz frame rate. The luminance of white hexagons was 400 cd/m^2 and that of black hexagons 4 cd/m^2 . The electrode used was the ERG-jet corneal electrode. Dark frames were inserted after the white frames to achieve an 18-Hz stimulus frequency. The surrounding luminance was set at 30 cd/m^2 . The stimulus was calibrated following the ISCEV guidelines.²⁷ After pupil dilation

using phenylephrine 5% (Europhtha, Monaco) and tropicamide (Thea, Clermont-Ferrand, France), patient positioning, good fixation, best optical correction for near vision, and constant moderate room light for at least 15 minutes were ensured for each patient. Care was taken to eliminate any reflections from lens surfaces and to keep any bright light sources out of the patient's direct view. The first-order kernel mfERG responses were analyzed. Individual mfERG responses for the hexagons were grouped into 5 concentric rings centered on the fovea for analysis (2, 2-5, 5-10, 10-15, and beyond 15 degrees of visual angle). Mathematically, the first-order kernel is obtained by adding all the records that follow the presentation of a white hexagon (luminance, 400 cd/m²) and subtracting all the records that follow a black hexagon. The following data were collected: the root mean square values (RMS), implicit time (IT), and AMP of N1, P1, and N2 waves. The N1 response was measured from the starting baseline to the base of the N1 trough; the P1 response AMP was measured from the N1 trough to the P1 peak. IT was measured from the onset of the stimulation to the trough or peak. Only averaged data including 5 rings are presented in the Results section.

Normative values (obtained from the manufacturer, Métrovision) are (mean \pm SD): -915 \pm 260 nV for N1 AMP, 1633 \pm 395 nV for P1 AMP, 23.2 \pm 1.3 ms for N1 IT, and 42.2 \pm 1.6 ms for P1 IT. The reliability using the Metrovision device has been previously reported in this study.²⁸ For N1 and P1 waves, the percentage change for the intraindividual reproducibility study was 9.1% and 6.7%, respectively, with the ERG-jet electrode and 18.2% and 13.5%, respectively, using the same electrode. These published data have been used in the present study to categorize evolution of mfERG parameters into unchanged/improved/deteriorated evolution from baseline.

• **STATISTICAL ANALYSIS:** Sex, treatments at baseline, evidence of photoreceptor alteration, ME and ERM on OCT, and fluorescein and indocyanine green angiography findings were reported as numbers and percentages. Age, disease duration, VA, QoL score, foveal threshold, VF parameters, color vision score, CMT, and ERG data (ie, N1 and P1 implicit times and amplitudes) were summarized with means and standard deviation. Because of skewed distribution, disease duration and total error score were summarized with the median and 25th-75th percentiles.

Time trends in continuous mfERG parameters were modeled using linear regression for longitudinal data with time to FU visit entered as an independent variable. The linear time trend reflected the long-run tendency of mfERG parameter values to increase or decrease over time.

Temporal trends in continuous mfERG parameters were modeled using linear regression for longitudinal data with time to FU visit entered as an independent variable. To investigate univariate associations of mfERG parameters, we performed longitudinal regression modeling for

continuous dependent variables, with characteristics and time to FU entered as independent covariates. We assessed the linearity assumption for continuous independent variables by using fractional polynomial functions. First-order interactions involving time to FU and each independent covariate were systematically tested for statistical significance. If a significant interaction was found, coefficient estimates were stratified by time to FU. To account for the hierarchical data structure, we used generalized estimated equations with the eye and FU observations nested within participants.^{29,30}

Regression coefficient point estimates were reported along with 95% confidence intervals. Regression coefficients represent the variation in predicted mfERG parameter value for a 1-unit increase in the covariate value. In longitudinal analysis, changes in mfERG parameter values were reported as "per year of FU." Two-sided *P* values of $<.05$ were considered statistically significant. All analyses were performed using Stata Special Edition version 14.0 (Stata Corporation, College Station, Texas, USA).

RESULTS

OVERALL, 16 PATIENTS WITH A MEAN AGE OF 60.2 (STANDARD deviation, 7.8) years were enrolled between 2008 and 2010 and underwent FU visits at 3.2 (standard deviation 0.3) and 5.1 (standard deviation, 0.2) years of enrollment. Baseline characteristics are reported in Table 1. The mean time from diagnosis to enrollment was 4.8 \pm 4 years. Eight eyes (25%) had a cataract and none was pseudophakic at baseline, while 4 eyes (12.5%) underwent cataract surgery during the FU period.

No significant temporal trend was found for VA (increase of 0.46 letter per year of FU, 95% confidence interval [CI], -0.51 to 1.44, *P* = .35), color vision score (decrease of -9 per year of FU, 95% CI, -20 to 2, *P* = .12), foveal threshold (increase of 0.19 dB per year of FU, 95% CI, -0.14 to 0.52, *P* = .26), and mean deviation of visual field (increase of 0.07 dB per year of FU, 95% CI, -0.19 to 0.33, *P* = .60), and quality-of-life score (increase of 0.71 per year of FU, 95% CI, -0.89 to 2.31, *P* = .39) over the 5-year FU period.

The percentage of patients receiving corticosteroids alone or in combination with immunosuppressive treatment was 62% (10/16) and 56% (9/16) at baseline and 5 years of FU, respectively (*P* = .72). The percentage of patients with corticosteroids alone decreased over time (from 50% at baseline to 25% at the 5-year FU) and the proportion of patients with corticosteroids and immunosuppressants increased (from 0% at baseline to 31%). Over the 5-year period, 2 out of 16 patients were newly treated, 3 out of 16 did not change their treatment, 3 out of 16 stopped their previous treatment, and 4 out of 16 had no treatment.

TABLE 1. Baseline Patient and Eye Characteristics

Characteristic	Result	
Baseline patient characteristics (n = 16) ^a		
Male sex, n (%)	6	(37.5)
Disease duration, median (IQR), y	4.2	(1.6-7.3)
Quality-of-life score, mean (SD)	70.3	(15.2)
Treatment, n (%)		
None	6	(37.5)
Corticosteroids	8	(50.0)
Immunosuppressive therapy	2	(12.5)
Baseline eye characteristics (n = 32) ^b		
Visual acuity (ETDRS letters), mean (SD)	76.6	(14.5)
Visual field		
Foveal threshold, mean (SD), dB	33.3	(4.5)
Mean deviation of the sensitivity of visual field, mean (SD), dB	-6.24	(6.04)
Color vision		
Total error score, median (IQR)	140	(88-244)
OCT data		
Central macular thickness, ^c mean (SD), μm	260	(90)
Photoreceptor alteration, n (%)	5	(15.6)
Cystoid macular edema, n (%)	4	(12.5)
Epiretinal membrane, n (%)	12	(37.5)
ERG data		
N1 amplitude, mean (SD), nV	-648	(243)
N1 implicit time, mean (SD), ms	25.4	(2.8)
P1 amplitude, mean (SD), nV	1099	(432)
P1 implicit time, mean (SD), ms	45.4	(3.1)
N2 amplitude, mean (SD), nV	-821	(380)
N2 implicit time, mean (SD), ms	65.3	(4.8)
Fluorescein angiography		
Posterior capillary leakage, n (%)	10	(31.2)
Optic disc hyperfluorescence, n (%)	6	(18.8)
Venous vasculitis, n (%)		
Absence	19	(59.4)
1 quadrant	3	(9.4)
2 quadrants	4	(12.5)
3 quadrants	4	(12.5)
4 quadrants	2	(6.2)
Peripheral capillary leakage, n (%)		
Absence	20	(62.5)
1 quadrant	2	(6.2)
2 quadrants	1	(3.1)
3 quadrants	0	(0.0)
4 quadrants	9	(28.1)
Indocyanine green angiography		
Peripapillary hypocyancence, n (%)	17	(53.1)
Dark dots, n (%)		
Absence	2	(6.2)
1 quadrant	3	(9.4)

Continued on next column

A significant decreasing temporal trend was observed over the 5-year FU period (Figure 1) for N1 (37 nV, 95% CI, 24-51, $P < .001$), P1 (61 nV, 95% CI, 38-84, $P < .001$), and N2 (35 nV, 95% CI, 11-58, $P = .003$)

TABLE 1. Baseline Patient and Eye Characteristics (Continued)

Characteristic	Result	
2 quadrants	3	(9.4)
3 quadrants	7	(21.9)
4 quadrants	17	(53.1)

ERG = electroretinography; IQR = interquartile range (ie, 25th-75th percentiles); OCT = optical coherence tomography; SD = standard deviation.

Normative values (obtained from the manufacturer, Métrovision) are (mean ± SD) -915 ± 260 nV for N1 amplitude, 1633 ± 395 for P1 amplitude, 23.2 ± 1.3 ms for N1 implicit time, and 42.2 ± 1.6 ms for P1 implicit time.

^aValues were missing for quality of life (n = 1) and disease duration (n = 1).

^bN2 amplitude and N2 implicit times were missing at baseline for 1 eye in 1 patient.

^cCMT was defined as the mean retinal thickness within the 1-mm central subfield.

amplitudes. Over the same period, P1 implicit time increased (0.68 ms, 95% CI, 0.41-0.94, $P < .001$) while N1 (0.24 ms, 95% CI, -0.04 to 0.51, $P = .08$) and N2 (0.89 ms, 95% CI, -5.20 to 6.98, $P = .78$) implicit times did not vary significantly. Taking into account the intraindividual reproducibility of the mfERG, we reported that N1 AMP and P1 AMP deteriorated in 25 of 32 eyes (78%) between baseline and FU3 (last visit, Supplemental Table; Supplemental Material available at AJO.com).

Increasing N1 and P1 IT were both associated with increasing values of EDTRS score (in letters), foveal threshold, and quality of life and with increasing color vision score and mean deviation of visual field over the 5-year FU period (Table 2). A significant relationship was observed between decreasing P1 AMP values and increasing MD of visual field. Increased N2 AMP and longer N2 IT were associated with decreasing values of mean deviation of visual field over the 5-year FU period (Table 2) whereas longer N2 IT was also associated with increasing values of VA (EDTRS letters).

Over the 5-year FU period, longer N1 and P1 IT were both associated with macular edema (Table 3). Additionally P1 IT was also associated with optic disk hyperfluorescence and peripapillary hypocyancence. Univariate associations were found between reduced N1 AMP values and the presence of venous vasculitis and peripheral capillary leakage. Reduced P1 AMP values were associated with the presence of photoreceptor layer alteration. No significant association was found between mfERG variables with posterior capillary leakage. Reduced N2 AMP and lower IT were significantly associated with photoreceptor alteration in OCT.

Figure 2 illustrates 1 case with a typical reduction of N1 and P1 AMP over time whereas visual field parameters and

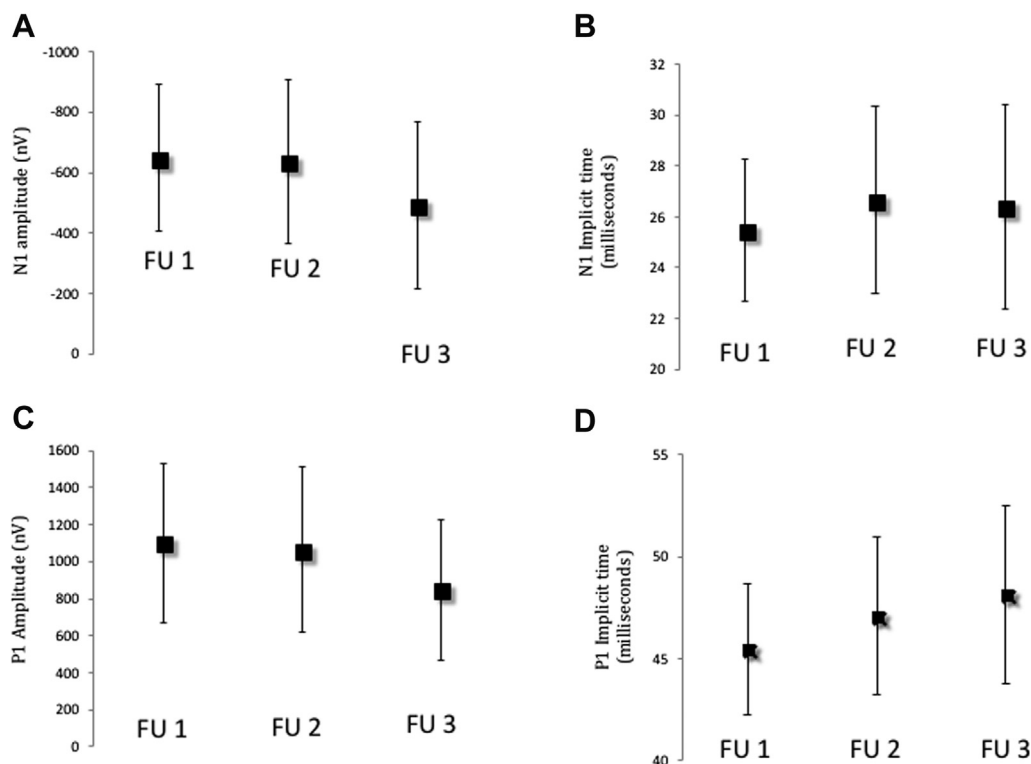


FIGURE 1. Trends in average values of multifocal electroretinogram parameter values at baseline (BL), follow-up 2 (FU2) at approximately 3 years, and follow-up 3 (FU3) at approximately 5 years. The filled square is the average value of 16 patients and the vertical line is the standard deviation. **A:** N1 amplitude (increase of 37 nV per year of FU, 95% CI, 24-51, $P < .001$). **B:** N1 implicit time (increase of 0.24 ms per year of FU, 95% CI, -0.04 to 0.51, $P = .09$). **C:** P1 amplitude (decrease in 61 nV per year of FU, 95% CI, -84 to -38, $P < .001$). **D:** P1 implicit time (increase of 0.68 ms per year of FU, 95% CI, 0.41 to 0.94, $P < .001$). Data are means and bars represent standard deviation.

VA were stable, and no recurrence of vasculitis or CME occurred.

DISCUSSION

THIS PROSPECTIVE OBSERVATIONAL CASE SERIES STUDY showed that mfERG parameters worsen in BSCR patients during a 5-year FU period, with decreasing N1 and P1 AMP values and increasing P1 IT. Importantly, these temporal trends in mfERG parameter values were not paralleled by changes in classical functional parameters such as VA and visual field. However, substantial associations were found between N1 AMP and venous vasculitis and peripheral capillary leakage, whereas P1 AMP reflected alterations of the outer retina in OCT, after adjusting for time to FU. Wave amplitudes were well correlated to the visual field parameters whereas IT was well correlated to quality of life, VA, and visual field parameters (Figure 3).

We confirmed that BSCR patients exhibit reduced AMP of P1 and N1 waves and increased IT of P1 over time. These data are consistent with our previous findings in a cross-sectional study, showing that BSCR eyes differed

significantly from healthy eyes by a decrease in P1 (-17%) and N2 AMP (-27%) and an increase in N1 (9%) and P1 (5%) IT.¹⁴ In presence of macular atrophy in long-standing (>10 years) BSCR patients, foveal mfERG amplitudes¹³ are reduced by 2.3 when compared to BSCR eyes without anatomic thinning.

To our knowledge, the present study is the first to investigate trends in mfERG in patients with BSCR over a 5-year period. The reduction in N1 and P1 AMP and increase in P1 IT suggest a worsening of retinal function across time whereas classical functional parameters such as VA, color vision, and visual field parameters did not vary significantly. A previous study reporting standard ERG³¹ showed that 70% of the patients had a loss of inner and/or outer retinal functions over prolonged FU. Previous studies reporting the full-field cone system 30-Hz flicker ERG peak time,⁶ the scotopic bright flash amplitudes (combined rods and cones), reduction in the a-wave and b-wave amplitudes,^{32,33} reduction in cone-b-wave implicit times, and reduction in scotopic rod b-wave amplitudes⁷ illustrated that both the rod and cone systems are involved in BSCR.

Previous studies showed that VA did not accurately reflect disease severity,³⁴ was stable,² or yielded a slow

TABLE 2. Longitudinal Analysis of Univariable Associations Between Multifocal Electroretinogram and Functional Parameters

Parameters	N1 Amplitude, nV			N1 Implicit Time, ms			P1 Amplitude, nV			P1 Implicit Time, ms		
	β^a	(95% CI)	<i>P</i>	β^a	(95% CI)	<i>P</i>	β^a	(95% CI)	<i>P</i>	β^a	(95% CI)	<i>P</i>
Visual acuity (ETDRS letters)	-2.24	(-4.91 to 0.43)	.10	-0.09	(-0.13 to -0.04)	<.001	2.33	(-2.36 to 7.02)	.33	-0.05	(-0.10 to 0.00)	.05
Quality of life	-1	(-4 to 2)	.52	-0.08	(-0.13 to -0.02)	.004	0.7	(-4.8 to 6.3)	.80	-0.06	(-0.12 to -0.02)	.04
Visual field, dB												
Foveal threshold	2.3	(-5.8 to 10.4)	.56	-0.3	(-0.4 to -0.1)	<.001	4	(-11 to 18)	.61	-0.2	(-0.4 to -0.1)	.003
MD	-9.3	(-18.5 to -0.1)	.05	-0.4	(-0.5 to -0.3)	<.001	23	(8 to 38)	.002	-0.4	(-0.6 to 0.3)	<.001
Color vision	0.20	(-0.03 to 0.43)	.10	0.01	(0.007 to 0.01)	<.001	-0.5	(-0.9 to -0.1)	.01	0.008	(0.004 to 0.010)	<.001
Parameters	N2 Amplitude, nV			N2 Implicit Time, ms								
	β^a	(95% CI)	<i>P</i>	β^a	(95% CI)	<i>P</i>						
Visual acuity (ETDRS letters)	-2.45	(-7.07 to 2.17)	.30	1.18	(0.86 to 1.49)	<.001						
Quality of life	-0.5	(-6.3 to 5.4)	.88	-0.43	(-0.28 to 1.13)	.24						
Visual field, dB												
Foveal threshold	-3.0	(-17.3 to 11.3)	.68	1.3	(-0.9 to 3.4)	.26						
MD	-22.3	(-36.5 to -8.2)	.002	1.9	(0.8 to 3.0)	.001						
Color vision	0.55	(0.14 to 0.96)	.009	-0.02	(-0.08 to 0.05)	0.59						

CI = confidence interval; MD = mean deviation; mfERG = multifocal electroretinogram.

^aRegression coefficients represent the variation in predicted mfERG parameter value for a 1-unit increase in the covariate value. β regression coefficients represent change in mfERG parameters for a 1-unit variation in functional parameters. For instance, a 1-decibel increase in MD values (ie, worsening of MD) is associated with a -0.4 ms variation in predicted N1 implicit time. In addition, a 1-decibel decrease in MD values (ie, improvement of MD) is associated with a +23 nV variation in predicted N1 implicit time.

TABLE 3. Longitudinal Analysis of Univariate Associations Between Multifocal Electroretinogram Parameters and Anatomic Parameters

Parameters	N1 Amplitude, nV			N1 Implicit Time, ms			P1 Amplitude, nV			P1 Implicit Time, ms		
	β^a	(95% CI)	<i>P</i>	β^a	(95% CI)	<i>P</i>	β^a	(95% CI)	<i>P</i>	β^a	(95% CI)	<i>P</i>
OCT												
CMT	0.06	(-0.35 to .49)	.75	0.001	(-0.006 to .01)	.67	0.22	(-0.52 to 0.96)	.56	0.001	(-0.007 to .01)	.72
PR alteration	2.37	(-70.51 to 75.25)	.95	0.90	(-0.62 to 2.43)	.25	-145.46	(-273.56 to -17.36)	.03	0.92	(-0.59 to 2.44)	.23
CME	-9.4	(-72.93 to 54.1)	.77	1.38	(0.08 to 2.68)	.04	-75.63	(-186.48 to 35.21)	.18	1.48	(0.21 to 2.75)	.02
Fluorescein angiography												
Posterior capillary leakage	-21.90	(-85.30 to 41.49)	.50	-0.34	(-1.64 to .95)	.60	31.95	(-79.55 to 143.46)	.57	-0.87	(-2.15 to .39)	.18
Venous vasculitis	-24.10	(-42.51 to -5.70)	.01	0.26	(-0.12 to .65)	.18	30.21	(-2.77 to 63.20)	.07	-0.02	(-0.41 to .36)	.88
Peripheral capillary leakage	-21.35	(-39.07 to -3.63)	.02	-0.24	(-0.61 to .12)	.19	59.82	(30.31 to 89.33)	<0.001	-0.35	(-0.72 to .004)	.05
Optic disk hyperfluorescence	16.78	(-46.97 to 80.54)	.61	0.72	(-0.60 to 2.05)	.28	-75.73	(-186.94 to 35.47)	.18	1.62	(0.36 to 2.89)	.01
Indocyanin green angiography												
Dark dots areas	-14.46	(-39.19 to 10.25)	.25	0.00	(-0.50 to .52)	.98	17.89	(-25.80 to 61.59)	.42	-0.17	(-0.68 to .33)	.50
Peripapillary hypocyancescence	79.48	(-3.54 to 162.50)	.06	0.50	(-1.13 to 2.14)	.55	-16.39	(-163.47 to 130.68)	.83	2.23	(0.64 to 3.83)	.006
Parameters	N2 Amplitude, nV			N2 Implicit Time, ms								
	β^a	(95% CI)	<i>P</i>	β^a	(95% CI)	<i>P</i>						
OCT												
CMT	-0.32	(-1.05 to .42)	.40	0.08	(-0.04 to .21)	.19						
PR alteration	182.9	(57.5 to 308.4)	.004	-21.9	(-42.6 to -1.1)	.04						
CME	104.9	(-10.9 to 220.6)	.07	7.1	(-18.7 to 32.9)	.59						
Fluorescein angiography												
Posterior capillary leakage	38.9	(-74.3 to 152.2)	.50	13.1	(-6.7 to 32.8)	.19						
Venous vasculitis	-2.1	(-38.4 to 34.2)	.91	2.3	(-4.5 to 9.0)	.51						
Peripheral capillary leakage	-32.5	(-64.9 to -0.1)	.05	3.6	(-1.9 to 9.0)	.21						
Optic disk hyperfluorescence	81.5	(-35.4 to 198.5)	.17	2.6	(-23.0 to 28.1)	.84						
Indocyanin green angiography												
Dark dots areas	10.7	(-33.9 to 55.2)	.64	-2.4	(-10.7 to 5.9)	.57						
Peripapillary hypocyancescence	3.5	(-144.9 to 152.0)	.96	-7.9	(-27.4 to 11.7)	.43						

CI = confidence interval; CME = cystoid macular edema; CMT = central macular thickness; FA = fluorescein angiography; ICGA = indocyanin green angiography; OCT = optical coherence tomography; PR = photoreceptor.

^a β regression coefficients represent change in multifocal electroretinogram parameters for a 1-unit variation in functional parameters.

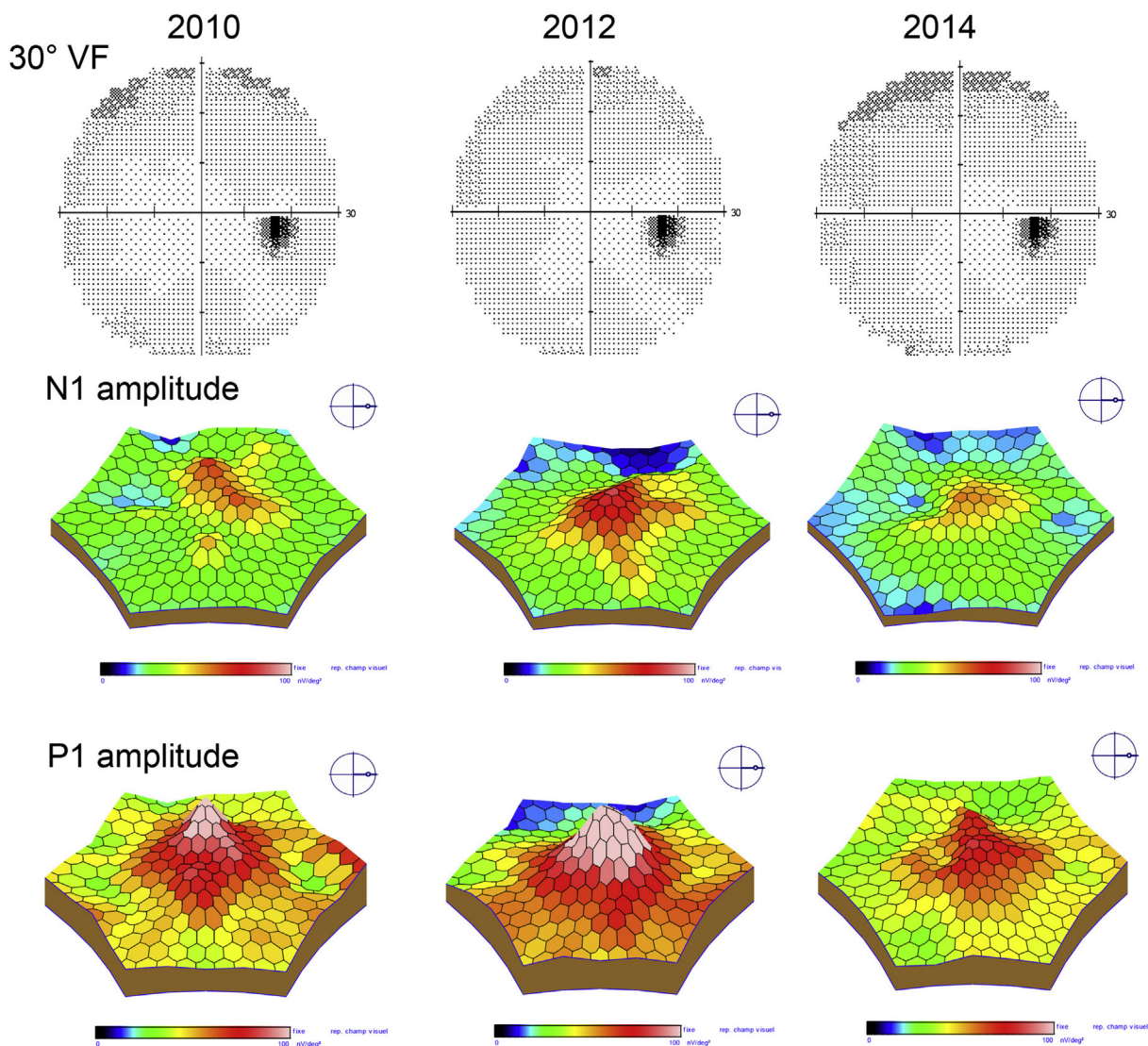


FIGURE 2. Time trend of multifocal electroretinogram (mfERG) parameters over a 5-year follow-up, with visual field and mfERG N1 and P1 amplitude 3D representation. This female patient, 50 years old, was diagnosed for birdshot disease in 2008. Visual acuity was 20/30; she had a venous vasculitis and a macular edema and was initially treated by steroids and mycophenolate mofetil. In 2010, the patient was free of macular edema and vasculitis, under treatment with mycophenolate mofetil. Visual field was stable within the 5-year period with mean deviation varying between -1.94 dB and -0.92 dB. Foveal sensitivity and visual acuity were stable (37 dB and 20/20, respectively). This case illustrates the worsening of mfERG parameters of the right eye within the 5-year period: decrease in N1 amplitudes (from -865 nV to -738 nV) and P1 amplitudes (from 1398 nV to 1197 nV). Note that N1 amplitudes are illustrated in positive absolute values in the 3D graph.

decline over time.³¹ Color vision is impaired in BSCR,^{5,14} with 55%-61% of patients having abnormal color confusion scores. However, the color vision score remained stable over 5 years in our study. There is more information in the literature concerning the abnormalities of the visual field, including peripheral constriction, generalized diminished sensitivity, enlarged blind spot, and central or paracentral scotoma.^{1,35} Recent studies showed that MD might be stable,² whereas PSD possibly reflecting sectorial changes increases, especially in patients who received short-term treatment. Pointwise

linear regression analysis of luminance sensitivity can identify visual field loss despite a stable MD.¹ These data highlight the need of complementary functional tests, which can reliably estimate the evolution of the retinal function.

Our data show a positive correlation between mfERG and other functional tests despite the absence of temporal changes of VA, color vision, and visual field parameters over a 5-year period. Wave AMPs were well correlated to the visual field sensitivity, whereas ITs were well correlated to quality-of-life, VA, and visual field parameters. An original finding of this study is the worsening of mfERG responses

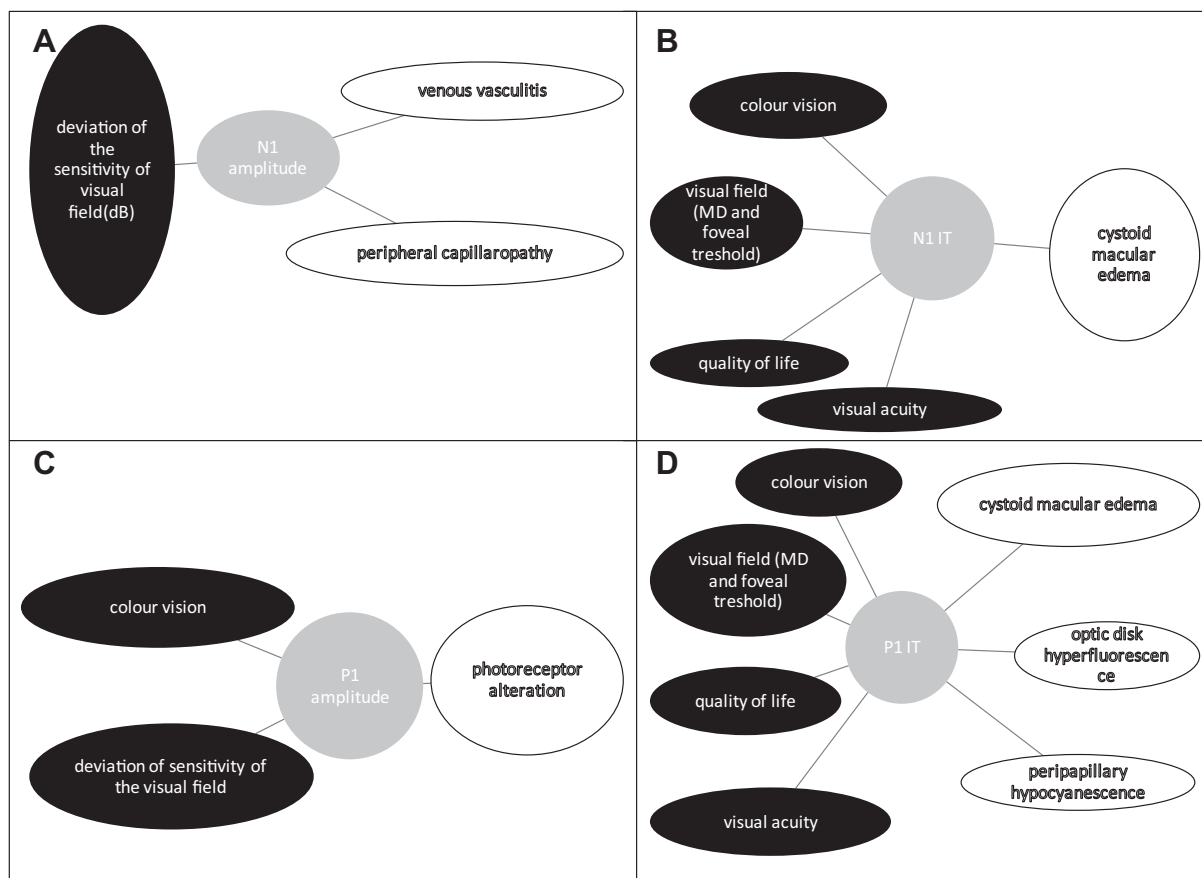


FIGURE 3. Univariate associations between multifocal electroretinogram parameters and anatomic and functional parameters.

while VA and MD of visual field remains stable over time. There are several potential explanations for this discrepancy. First, changes in N1 and P1 AMP and/or IT may be early markers of worsening clinical outcomes that may not be captured over a 5-year FU period. Second, we cannot exclude that this study was underpowered to detect any significant time trends in visual acuity, quality of life, visual field, or color vision. A perspective of this work will consist of investigating the prognostic value of mfERG responses at baseline for the prediction of visual function in the long term.

BSCR has a high impact on vision-related quality of life, especially for general health and near vision, difficulties with activities, and depression,¹⁴ with a mean global VFQ-25 score around 70, consistent with previous study.³⁶ In this study taking into account both eyes of each patient, we showed for the first time that (1) the reduced QoL score was not modified significantly during a 5-year period and (2) QoL score was significantly associated with N1 and P1 IT. This finding is interesting, since previous report showed only a weak correlation between composite scores and VA.³⁶

P1 wave abnormalities suggest a lesion at the cone receptor site and ON-bipolar cells, with a delayed response from both neurons.³⁷ The P1 IT is also known to be a very sensitive measure of outer retinal function.³⁷ In BSCR

patients, the outer retina damages, such as photoreceptor layer alteration and presence of macular edema, were respectively correlated with decreased AMP and longer IT of P1. This finding confirms the pilot study of Birch and associates, who showed that BSCR patients with OCT macular thinning exhibit a significantly altered mfERG.¹³ These data highlight the importance of analyzing the outer retina. Loss of OFF-bipolar cells is known to decrease the amplitude of N1.³⁷ We found that venous vasculitis and capillary leakage were specifically associated with a reduction in N1 AMP, probably by a deleterious effect on the inner retina, especially on bipolar cells. The origin of N2 wave remains uncertain.¹² A recent study indicated that the activity of retinal ganglion cells contributed to the amplitude of the N2 of the mfERG.³⁸ The univariate analysis done in our study shows that N2 AMP was associated with photoreceptor alterations, but it was not possible to identify confounding factors and contributions of other retinal layers, such as the retinal ganglion cell layer. Contribution of N2 for the FU of uveitis patients should be confirmed by further studies, while association with VF and VA were found in this study.

The implicit times of the N1 and P1 response are also known to be a very sensitive measure of outer retinal

function³⁷ and were correlated to the presence of macular edema. This finding is consistent with the correlation between CMT or macular edema and longer IT found previously in BSCR¹⁴ and diabetic patients.^{37,39}

We did not find any correlations between mfERG parameters and ICGA data, such as the number of quadrants with hypofluorescent dots at the intermediate phase. This finding could be owing to the relative independence between choroidal and retinal involvement.^{40,41} P1 IT was correlated with peripapillary hypofluorescence, which is a frequent finding in BSCR.^{42,43} Future studies are needed to correlate choroidal thinning with changes of mfERG.^{44,45}

The limitations of our study deserve mention. First, our study might be underpowered in detecting clinically significant temporal trends, owing to the relatively limited sample size. Second, we investigated univariate associations only. Indeed, too few observations were available relative to the number of predictors included in multivariate analysis of mfERG. Hence, the multivariable model would fit the data set too closely and be likely to perform less well in new patients—a statistical phenomenon called overfitting. Furthermore, the limited series of patients did not allow statistical comparisons for each ring separately. Third, 5 patients of the cohort were followed using TD-OCT since they were examined at baseline using TDOCT in 2008. For this reason, analysis of the outer retina was done according to the inner segment/outer segment disruption and not systematically considering the 4 bands well described in SDOCT (ELM, ellipsoid zone, cone interdigitation zone, RPE). We used a published formula in order to reduce the effect of using different OCT machines. We estimate that the range of error is slight and

that CME detection was not affected by these calculations. Fourth, 4 eyes (12.5%) were operated on for cataract during the study and the surgery was done between baseline and the first visit. The change in lens status may have changed the mfERG parameters. Cataract may reduce N1 and P1 amplitudes⁴⁶ and cataract surgery may increase mfERG responses.^{46,47} Finally, mfERG is limited to the central 30 degrees, much less than standard ERG. Our previous study¹⁴ showed that the degree of eccentricity (5 rings) modulated the values for RMS, P1 and N2 amplitude, and P1 implicit time. These differences were found essentially between ring 1+2 and the other rings, suggesting that the macula is more sensitive to inflammation than the extrafoveal retina. This topographic information was not used statistically in the present study owing to statistical limitations. We can therefore hypothesize that full-field ERG and mfERG are complementary. One should note that these examinations are time consuming and necessitate cooperation of the patient.

In conclusion, this longitudinal study of BSCR patients provides for the first time the evidence of worsening of mfERG responses in patients who were stable for other standard visual tests. MfERG, which is considered a reliable and accurate functional test,⁴⁸ was able to detect variations in N1 and P1 AMP and P1 IT over the 5-year FU period. Longer N1 and P1 IT at each visit were associated with functional worsening and macular edema. On the other hand, wave AMPs were associated with presence of venous vasculitis and peripheral capillary leakage for N1 and photoreceptor layer alteration for P1. Although our findings deserve replication, our study supports the use of mfERG for initial assessment and subsequent monitoring of BSCR activity.

FUNDING/SUPPORT: ASSOCIATION FOR RESEARCH AND TEACHING IN OPHTHALMOLOGY (ARFO, GRENOBLE, FRANCE). THE sponsor of the funding organization had no role in the design or conduct of this research. Financial Disclosures: The following authors have no financial disclosures: Adriane Mailhac, José Labarere, Florent Aptel, Sylvie Berthemey-Pellet, Laurence Bouillet, and Christophe Chiquet. All authors attest that they meet the current ICMJE criteria for authorship.

REFERENCES

1. Shah KH, Levinson RD, Yu F, et al. Birdshot chorioretinopathy. *Surv Ophthalmol* 2005;50(6):519–541.
2. Tomkins-Netzer O, Taylor SRJ, Lightman S. Long-term clinical and anatomic outcome of birdshot chorioretinopathy. *JAMA Ophthalmol* 2014;132(1):57–62.
3. Comander J, Loewenstein J, Sobrin L. Diagnostic testing and disease monitoring in birdshot chorioretinopathy. *Semin Ophthalmol* 2011;26(4-5):329–336.
4. Gordon LK, Monnet D, Holland GN, Brézin AP, Yu F, Levinson RD. Longitudinal cohort study of patients with birdshot chorioretinopathy. IV. Visual field results at baseline. *Am J Ophthalmol* 2007;144(6):829–837.
5. Holland GN, Shah KH, Monnet D, et al. Longitudinal cohort study of patients with birdshot chorioretinopathy II: color vision at baseline. *Am J Ophthalmol* 2006;142(6):1013–1018.
6. Holder GE. Electrophysiological characterisation and monitoring in the management of birdshot chorioretinopathy. *Br J Ophthalmol* 2005;89(6):709–718.
7. Sobrin L, Lam BL, Liu M, Feuer WJ, Davis JL. Electroretinographic monitoring in birdshot chorioretinopathy. *Am J Ophthalmol* 2005;140(1):52–64.
8. Zacks DN, Samson CM, Loewenstein J, Foster CS. Electroretinograms as an indicator of disease activity in birdshot retinopathy. *Graefes Arch Clin Exp Ophthalmol* 2002;40(8):601–607.
9. Symes R, Young M, Forooghian F. Quantitative assessment of retinal degeneration in birdshot chorioretinopathy using optical coherence tomography. *Ophthalmic Surg Lasers Imaging Retina* 2015;46(10):1009–1012.

10. Teussink MM, Huis In Het Veld PI, de Vries LAM, Hoyng CB, Klevering BJ, Theelen T. Multimodal imaging of the disease progression of birdshot chorioretinopathy. *Acta Ophthalmol* 2016;94(8):815–823.
11. Moschos MM, Gouliopoulos NS, Kalogeropoulos C. Electrophysiological examination in uveitis: a review of the literature. *Clin Ophthalmol* 2014;8:199–214.
12. Hood DC, Frishman LJ, Saszik S, Viswanathan S. Retinal origins of the primate multifocal ERG: implications for the human response. *Invest Ophthalmol Vis Sci* 2002;43(5):1673–1685.
13. Birch DG, Williams PD, Callanan D, Wang R, Locke KG, Hood DC. Macular atrophy in birdshot retinochoroidopathy: an optical coherence tomography and multifocal electroretinography analysis. *Retina* 2010;30(6):930–937.
14. Chiquet C, Berthemy-Pellet S, Altayrac-Bethenod J, et al. Multifocal electroretinogram in birdshot chorioretinopathy. *Retina* 2015;35(6):1256–1265.
15. Levinson RD, Brezin A, Rothova A, Accorinti M, Holland GN. Research criteria for the diagnosis of birdshot chorioretinopathy: results of an International Consensus Conference. *Am J Ophthalmol* 2006;141(1):185–187.
16. Lanthony P. [Evaluation of the desaturated Panel D-15. I. Method of quantification and normal scores]. *J Fr Ophthalmol* 1986;9(12):843–847.
17. Török. Farnsworth-munsell FM 100-Hue, Farnsworth D-15 and lanthony D-15-WEB-based scoring. 2006. Available at: <http://www.torok.info/colorvision5/d15.htm>. Accessed January 2019.
18. Mangione CM, Lee PP, Gutierrez PR, et al. Development of the 25-item National Eye Institute Visual Function Questionnaire. *Arch Ophthalmol* 2001;119(7):1050–1058.
19. Priem HA, Oosterhuis JA. Birdshot chorioretinopathy: clinical characteristics and evolution. *Br J Ophthalmol* 1988;72(9):646–659.
20. Fardeau C, Herbort CP, Kullmann N, Quentel G, LeHoang P. Indocyanine green angiography in birdshot chorioretinopathy. *Ophthalmology* 1999;106(10):1928–1934.
21. Monnet D, Brézin AP, Holland GN, et al. Longitudinal cohort study of patients with birdshot chorioretinopathy. I. Baseline clinical characteristics. *Am J Ophthalmol* 2006;141(1):135–142.
22. Fiore T, Androudi S, Iaccheri B, et al. Repeatability and reproducibility of retinal thickness measurements in diabetic patients with spectral domain optical coherence tomography. *Curr Eye Res* 2013;38(6):674–679.
23. Browning DJ, Glassman AR, Aiello LP, et al. Optical coherence tomography measurements and analysis methods in optical coherence tomography studies of diabetic macular edema. *Ophthalmology* 2008;115(8):1366–1371.e1.
24. Spaide RF, Curcio CA. Anatomical correlates to the bands seen in the outer retina by optical coherence tomography: literature review and model. *Retina* 2011;31(8):1609–1619.
25. Nazari H, Dustin L, Heussen FM, Sadda S, Rao NA. Morphometric spectral-domain optical coherence tomography features of epiretinal membrane correlate with visual acuity in patients with uveitis. *Am J Ophthalmol* 2012;154(1):78–86.e1.
26. Roh Y-R, Park KH, Woo SJ. Foveal thickness between stratus and spectralis optical coherence tomography in retinal diseases. *Korean J Ophthalmol* 2013;27(4):268.
27. Hood DC, Bach M, Brigell M, et al. ISCEV standard for clinical multifocal electroretinography (mfERG) (2011 edition). *Doc Ophthalmol* 2012;124(1):1–13.
28. Thimonier C, Daubas P, Bourdon L, et al. [Multifocal ERG using ERG-jet and Gold Foil electrodes in normal subjects: comparison and reproducibility]. *J Fr Ophthalmol* 2008;31(6 Pt 1):585–590.
29. Glynn RJ, Rosner B. Regression methods when the eye is the unit of analysis. *Ophthalmic Epidemiol* 2012;19(3):159–165.
30. Murdoch IE, Morris SS, Cousens SN. People and eyes: statistical approaches in ophthalmology. *Br J Ophthalmol* 1998;82(8):971–973.
31. Oh KT, Christmas NJ, Folk JC. Birdshot retinochoroiditis: long term follow-up of a chronically progressive disease. *Am J Ophthalmol* 2002;133(5):622–629.
32. Hirose T, Katsumi O, Pruett RC, Sakaue H, Mehta M. Retinal function in birdshot retinochoroidopathy. *Acta Ophthalmol (Copenh)* 1991;69(3):327–337.
33. Priem HA, De Rouck A, De Laey JJ, Bird AC. Electrophysiologic studies in birdshot chorioretinopathy. *Am J Ophthalmol* 1988;106(4):430–436.
34. Touhami S, Fardeau C, Vanier A, et al. Visual acuity in birdshot retinochoroidopathy evaluation. *Am J Ophthalmol* 2015;160(4):817–821.e2.
35. Arya B, Westcott M, Robson AG, Holder GE, Pavesio C. Pointwise linear regression analysis of serial Humphrey visual fields and a correlation with electroretinography in birdshot chorioretinopathy. *Br J Ophthalmol* 2015;99(7):973–978.
36. Levinson RD, Monnet D, Yu F, Holland GN, Gutierrez P, Brezin AP. Longitudinal cohort study of patients with birdshot chorioretinopathy. V. Quality of life at baseline. *Am J Ophthalmol* 2009;147(2):346–350.e2.
37. Hood DC. Assessing retinal function with the multifocal technique. *Prog Retin Eye Res* 2000;19(5):607–646.
38. Kato F, Miura G, Shirato S, Sato E, Yamamoto S. Correlation between N2 amplitude of multifocal ERGs and retinal sensitivity and retinal nerve fiber layer thickness in glaucomatous eyes. *Doc Ophthalmol* 2015;131(3):197–206.
39. Fortune B, Schneck ME, Adams AJ. Multifocal electroretinogram delays reveal local retinal dysfunction in early diabetic retinopathy. *Invest Ophthalmol Vis Sci* 1999;40(11):2638–2651.
40. Leozappa M, Micelli Ferrari T, Grossi T, et al. Prognostic prediction ability of postoperative multifocal ERG after vitrectomy for diabetic macular edema. *Eur J Ophthalmol* 2008;18(4):609–613.
41. Herbort CP, Probst K, Cimino L, Tran VT. Differential inflammatory involvement in retina and choroid in birdshot chorioretinopathy. *Klin Monbl Augenheilkd* 2004;221(5):351–356.
42. Koizumi H, Pozzoni MC, Spaide RF. Fundus autofluorescence in birdshot chorioretinopathy. *Ophthalmology* 2008;115(5):e15–e20.
43. Piffer A-LL, Boissonnot M, Gobert F, et al. Relevance of wide-field autofluorescence imaging in Birdshot retinochoroidopathy: descriptive analysis of 76 eyes. *Acta Ophthalmol* 2014;92(6):e463–e469.
44. Young M, Fallah N, Forooghian F. Choroidal degeneration in birdshot chorioretinopathy. *Retina* 2015;35(4):798–802.

45. Birnbaum AD, Fawzi AA, Rademaker A, Goldstein DA. Correlation between clinical signs and optical coherence tomography with enhanced depth imaging findings in patients with birdshot chorioretinopathy. *JAMA Ophthalmol* 2014;132(8): 929–935.
46. Tam W-K, Chan H, Brown B, Yap M. Effects of different degrees of cataract on the multifocal electroretinogram. *Eye (Lond)* 2004;18(7):691–696.
47. Tam W-K, Chan H, Brown B, Leung K-W, Woo V, Yap M. Comparing the multifocal electroretinogram topography before and after cataract surgery. *Curr Eye Res* 2005;30(7): 593–599.
48. Lai TYY, Chan W-M, Lai RYK, Ngai JWS, Li H, Lam DSC. The clinical applications of multifocal electroretinography: a systematic review. *Surv Ophthalmol* 2007; 52(1):61–96.